


Principles



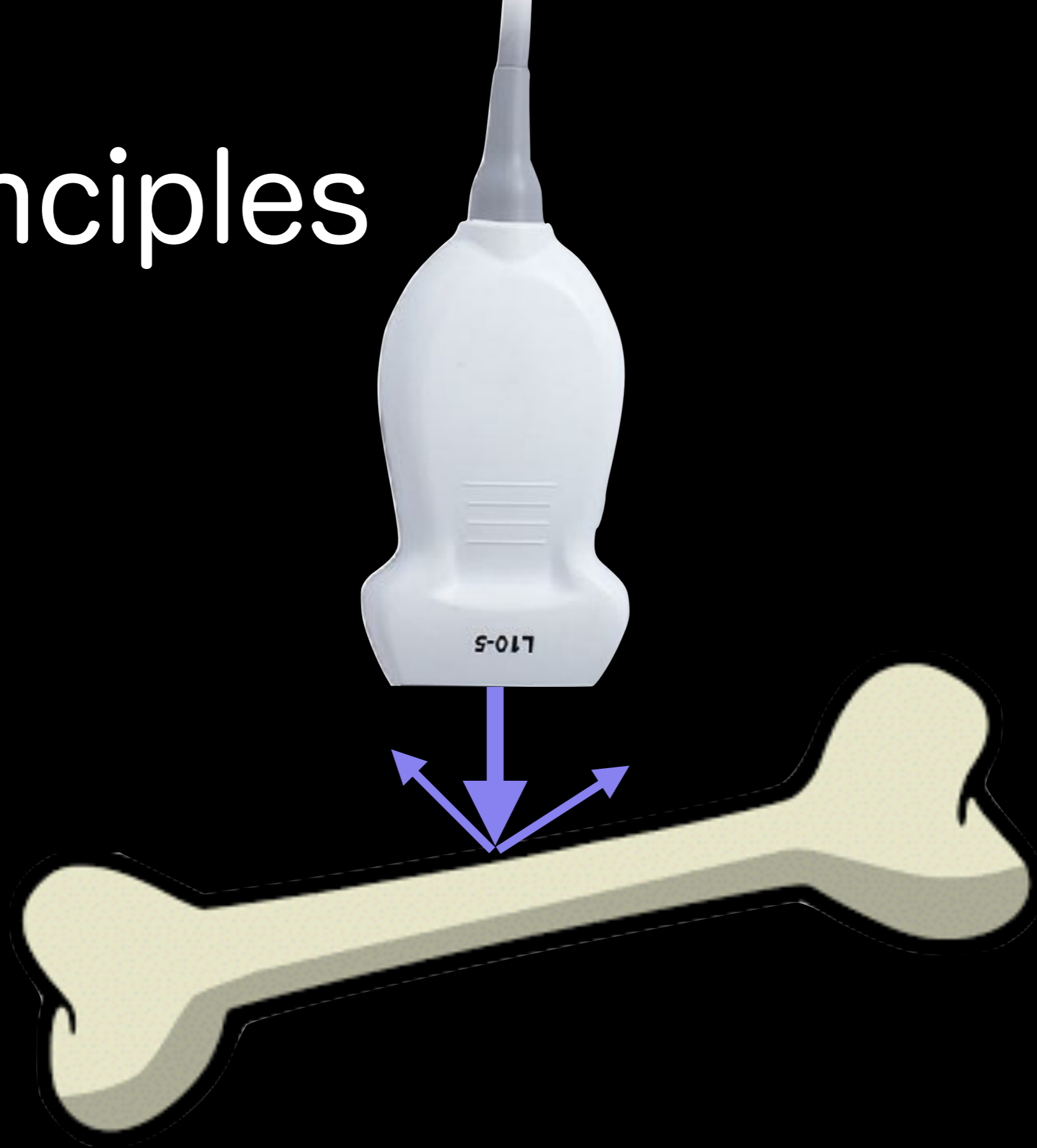
Principles



Principles



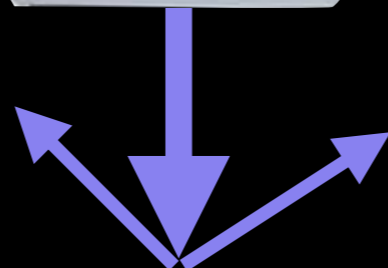
Principles



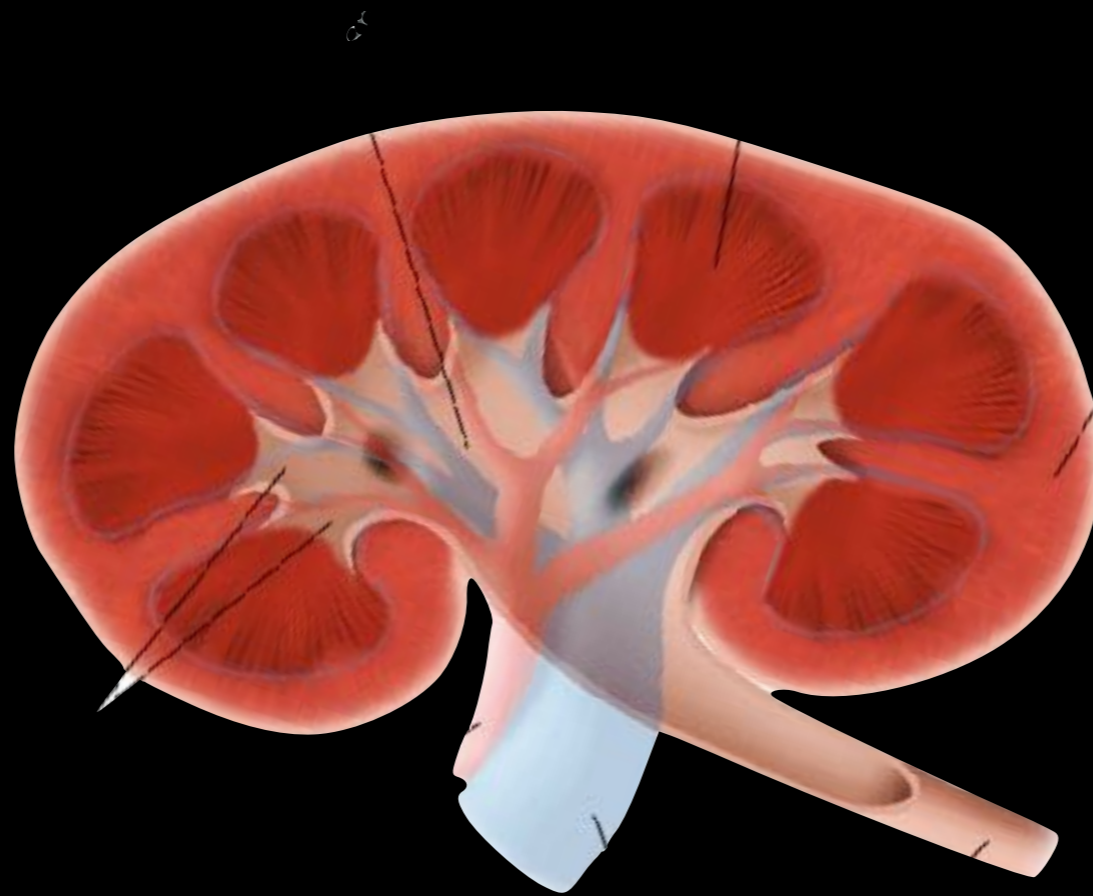Principles



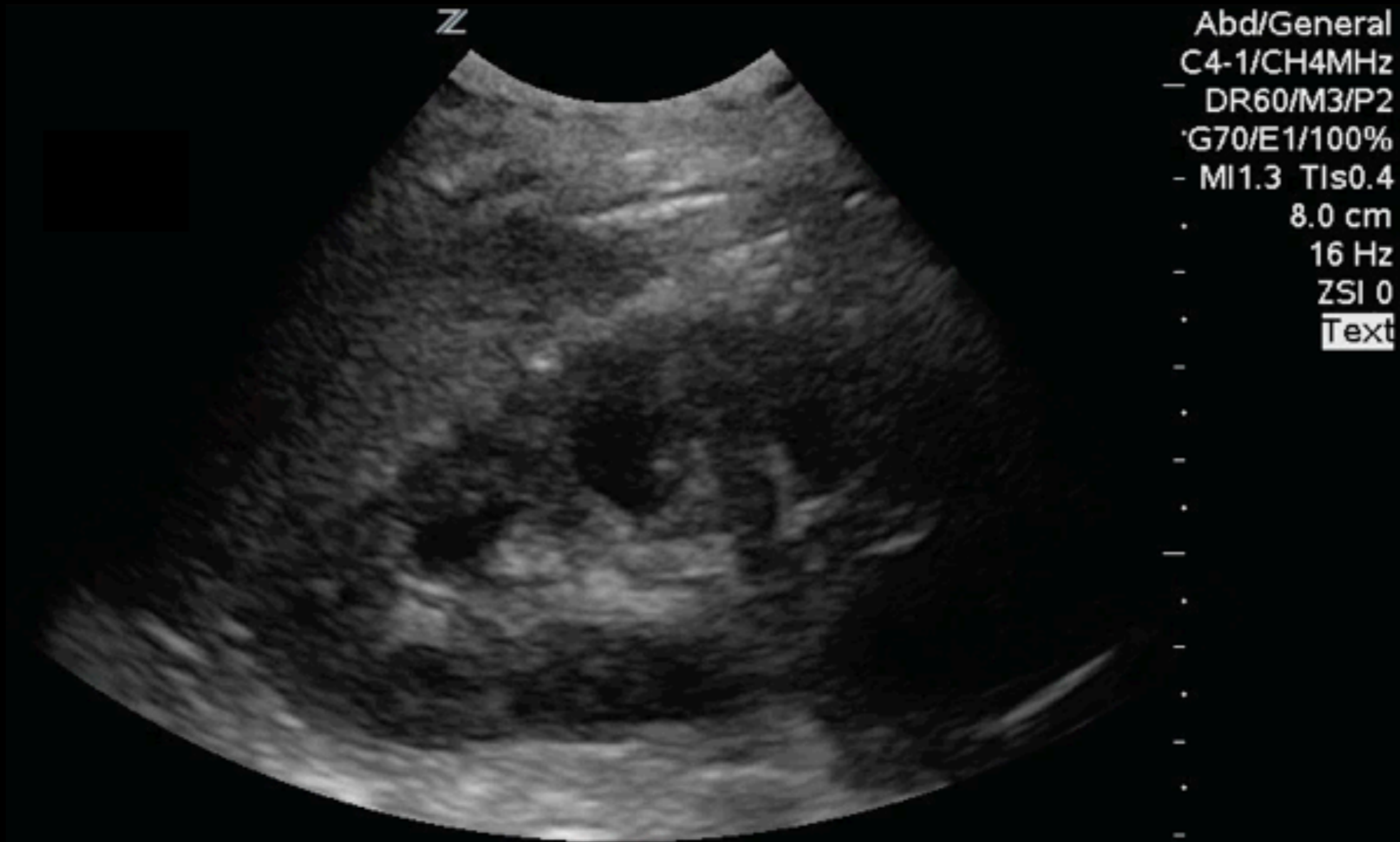
Principles



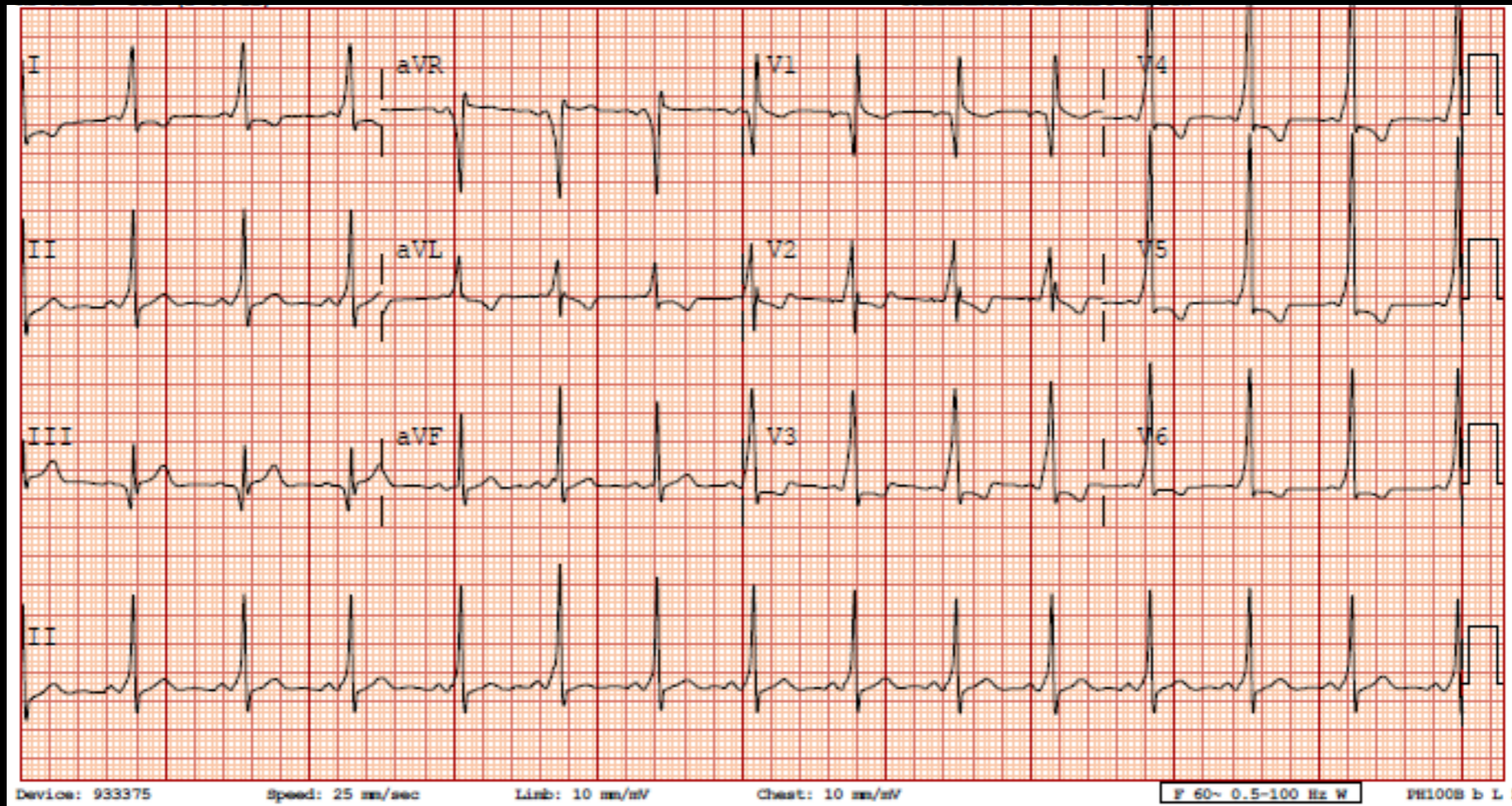
Principles



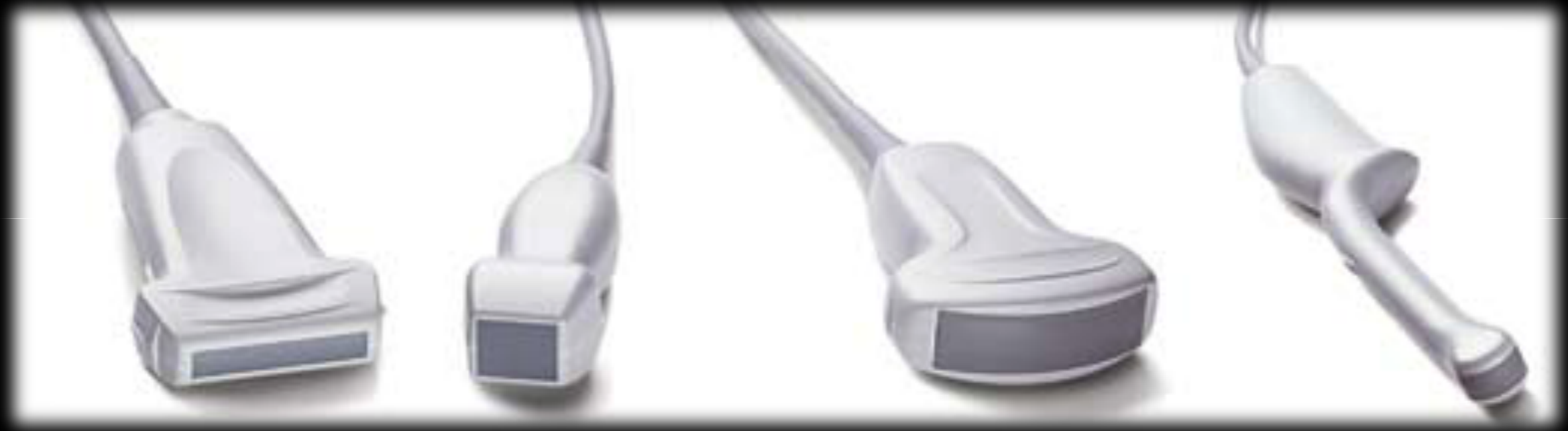Principles



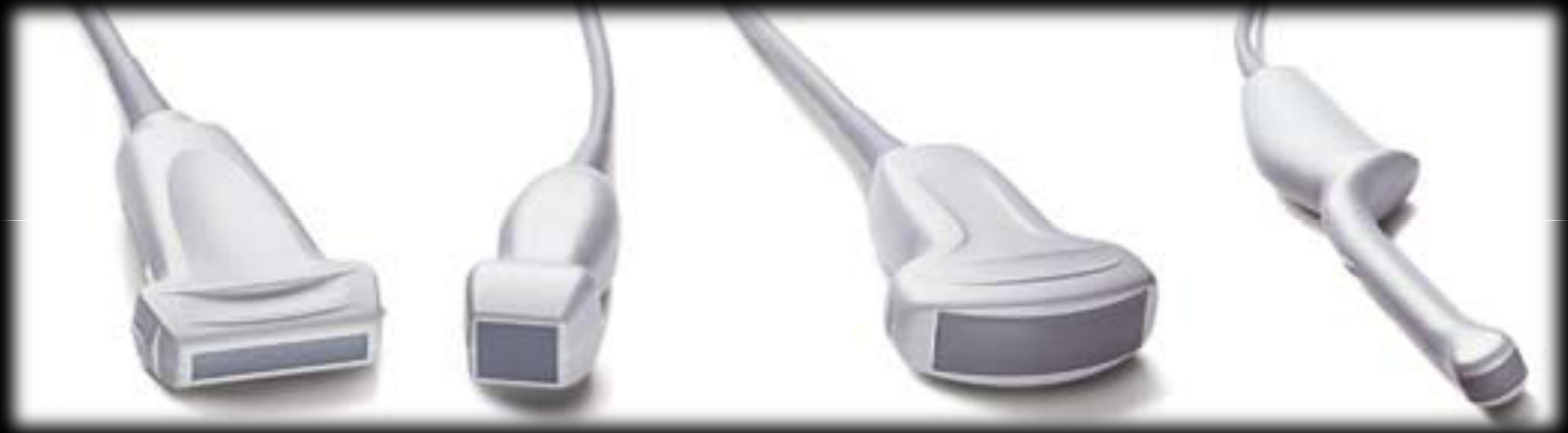Principles



Scanning technique




Scanning technique



Probe

Approach

Scanning technique




Probe

Curvilinear or phased array probe

Approach

Linear probe for lung sliding if needed

Scanning technique




Probe

Curvilinear or phased array probe

Approach

Linear probe for lung sliding if needed

Scanning technique




Probe

Approach

Lung setting

Scanning technique



Probe

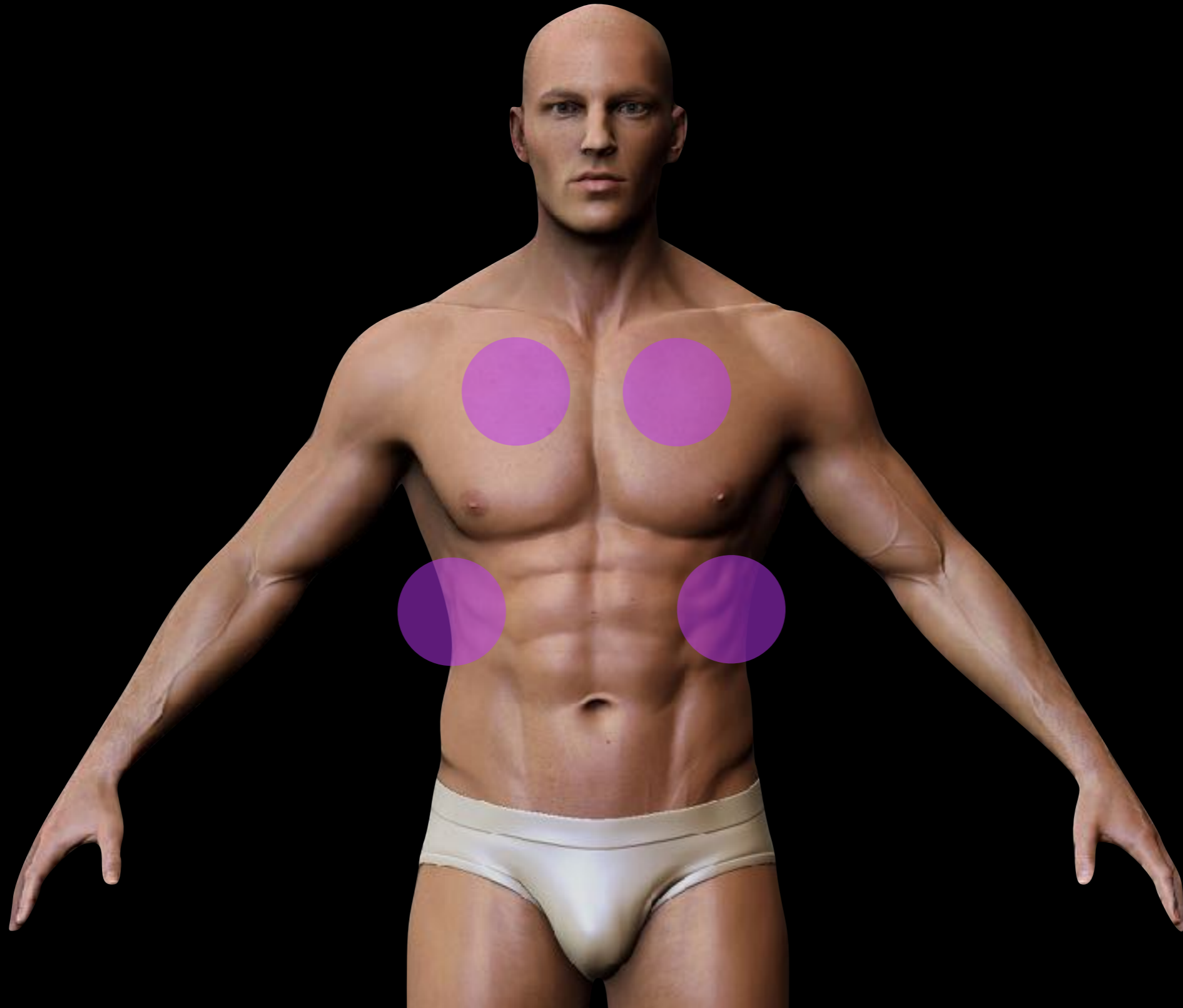
Approach



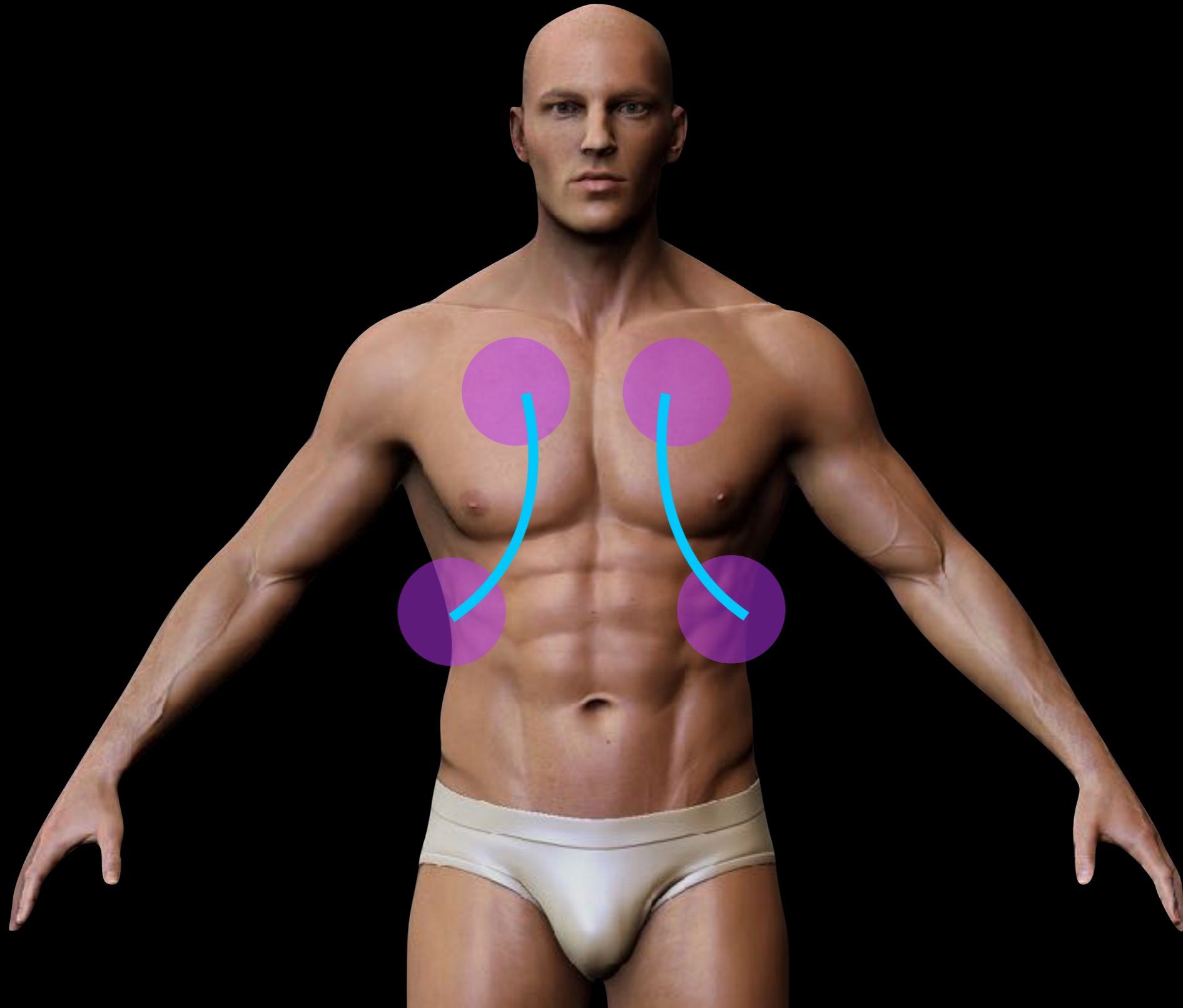Scanning technique




Scanning technique



Scanning technique



Interpretation



Lung sliding?

Lung sliding?

A-lines?

Lung sliding?

A-lines?

B-lines?

Lung sliding?

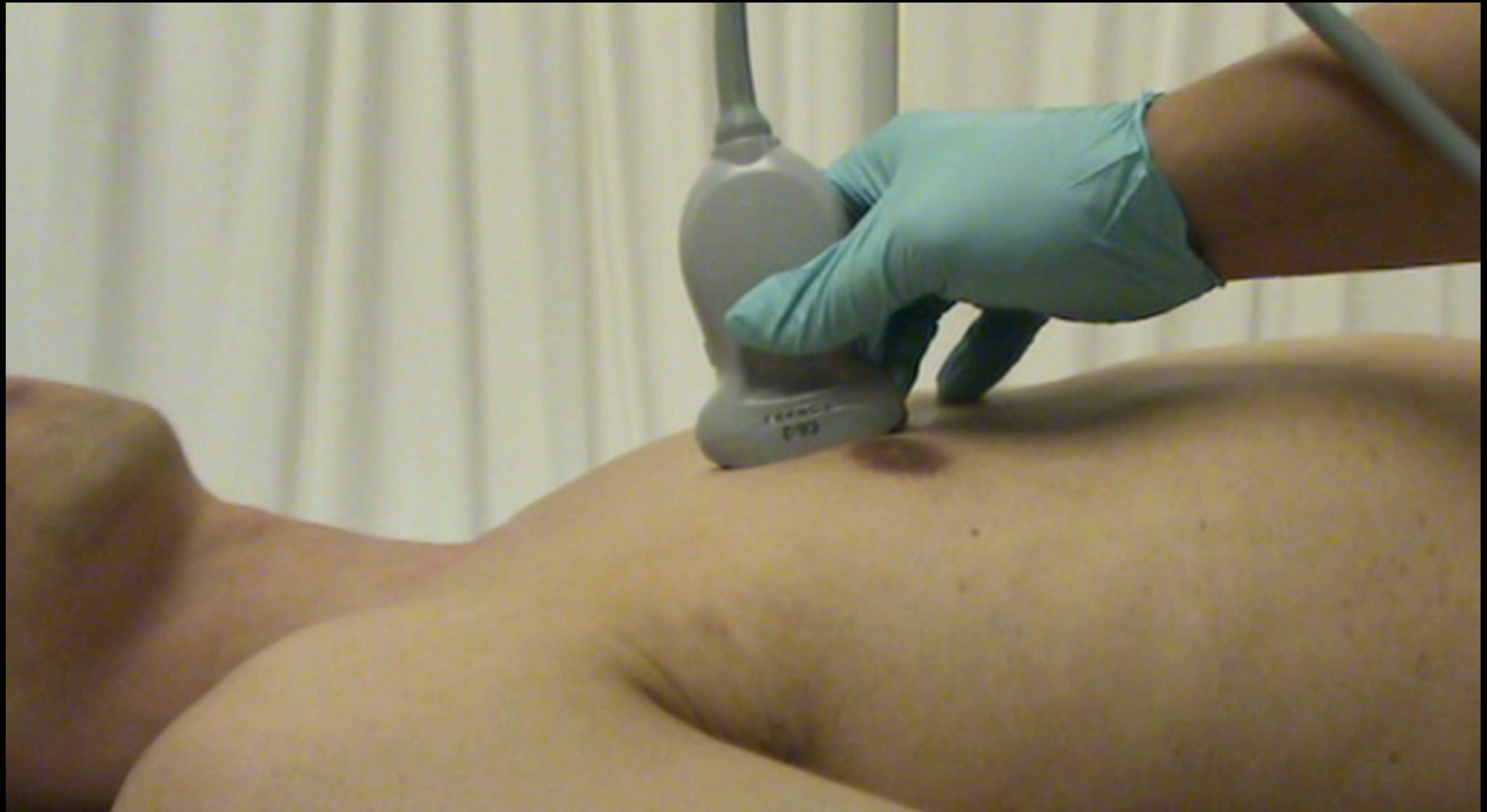
A-lines?

B-lines?

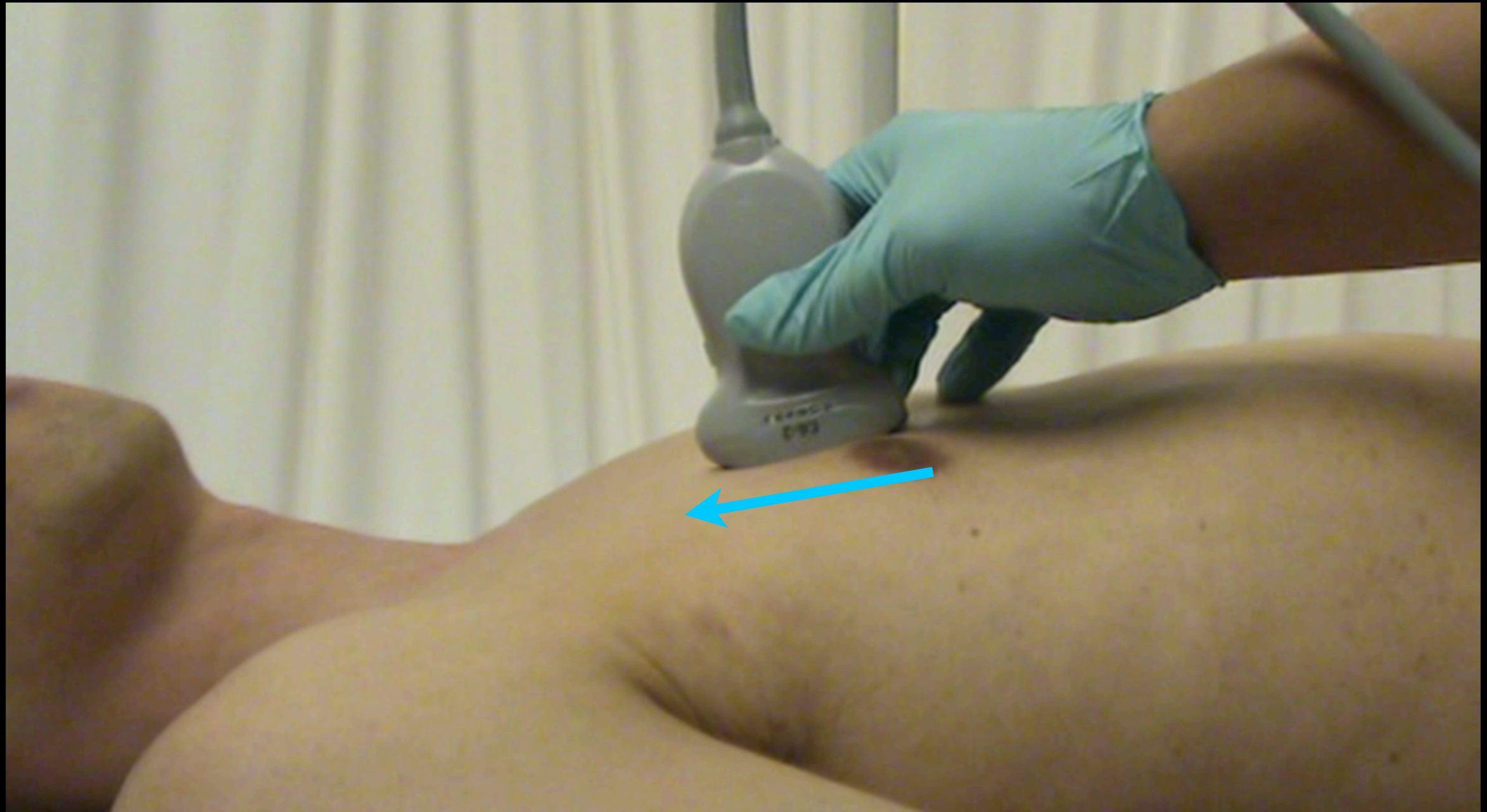
Consolidations or Effusions?

Lung sliding?

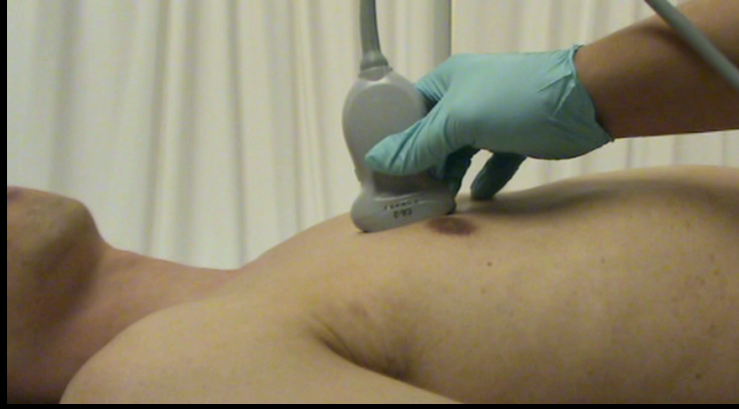Scanning technique

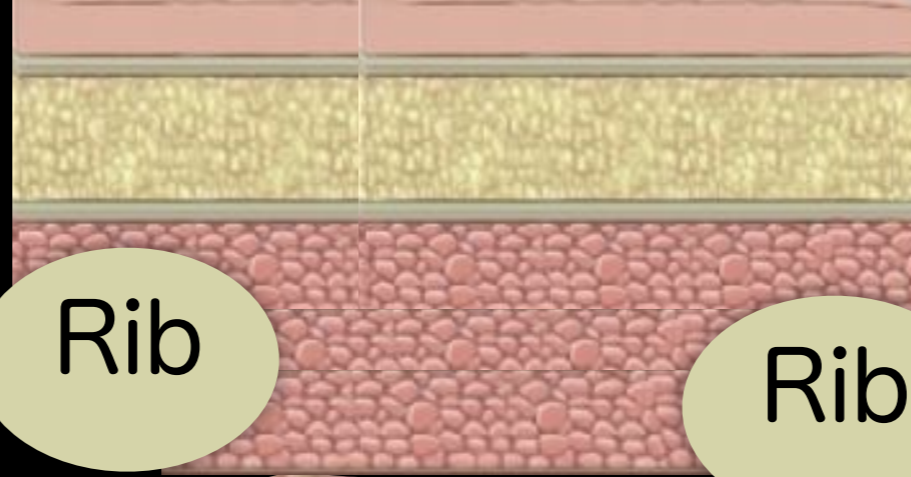
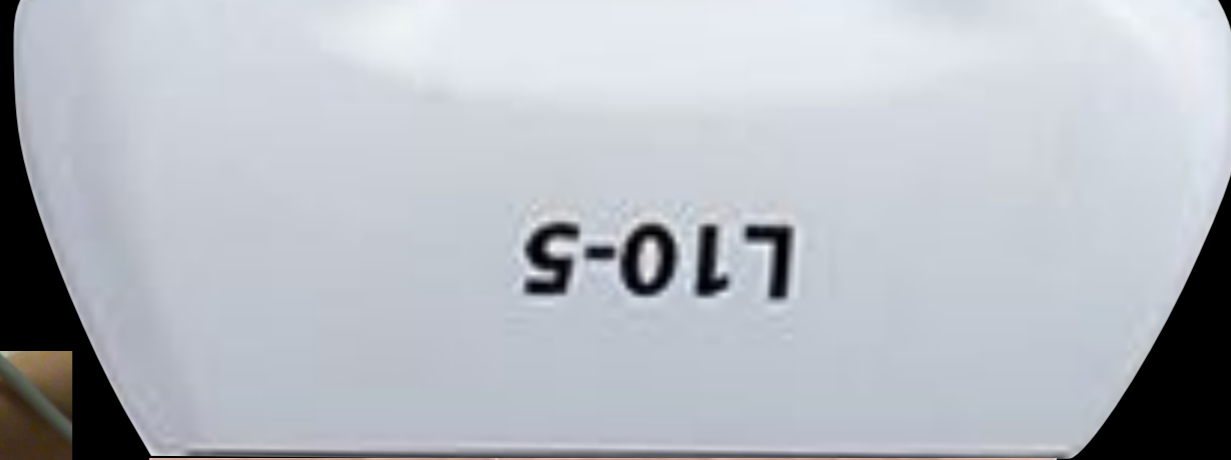
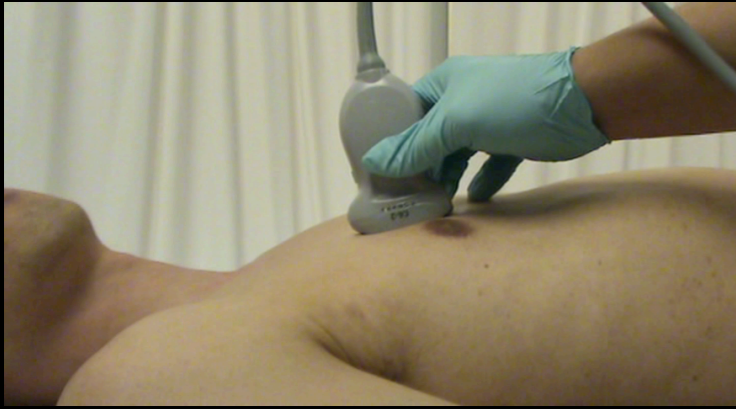

Scanning technique



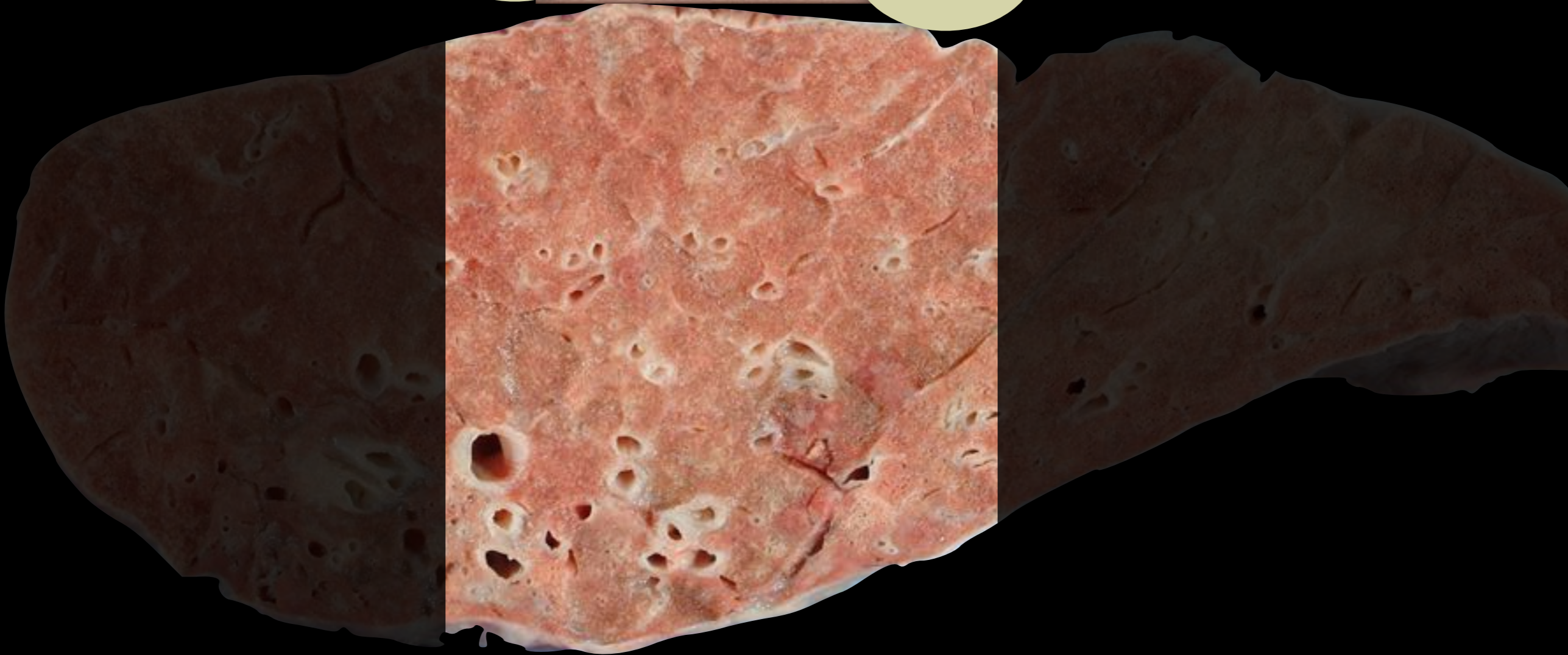
L10-5

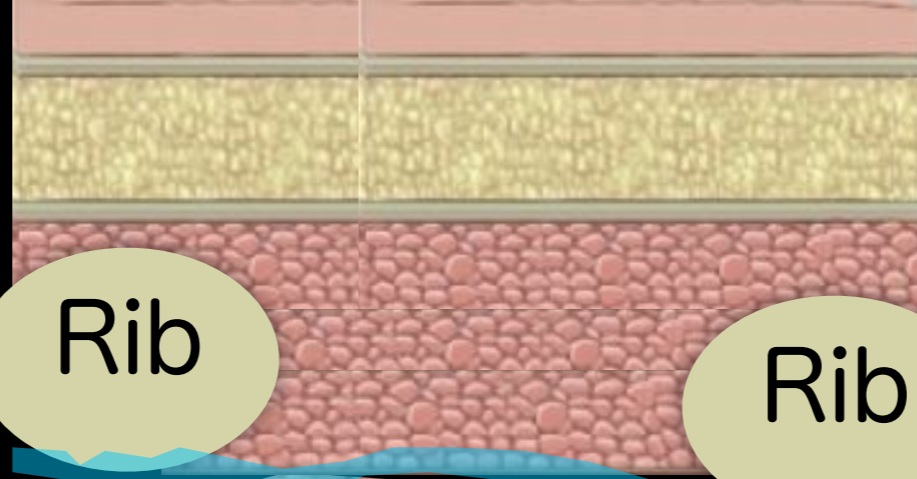
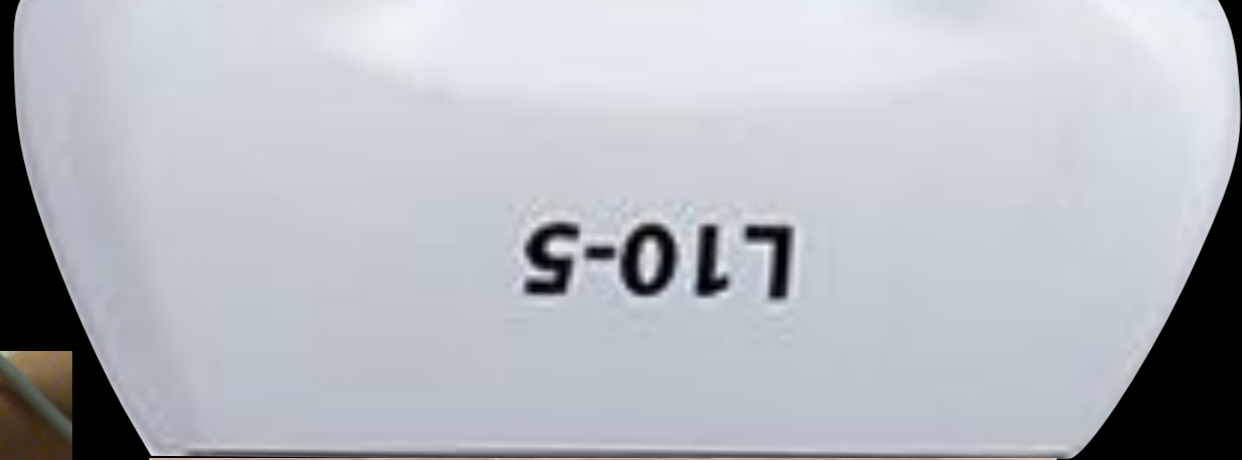



Rib

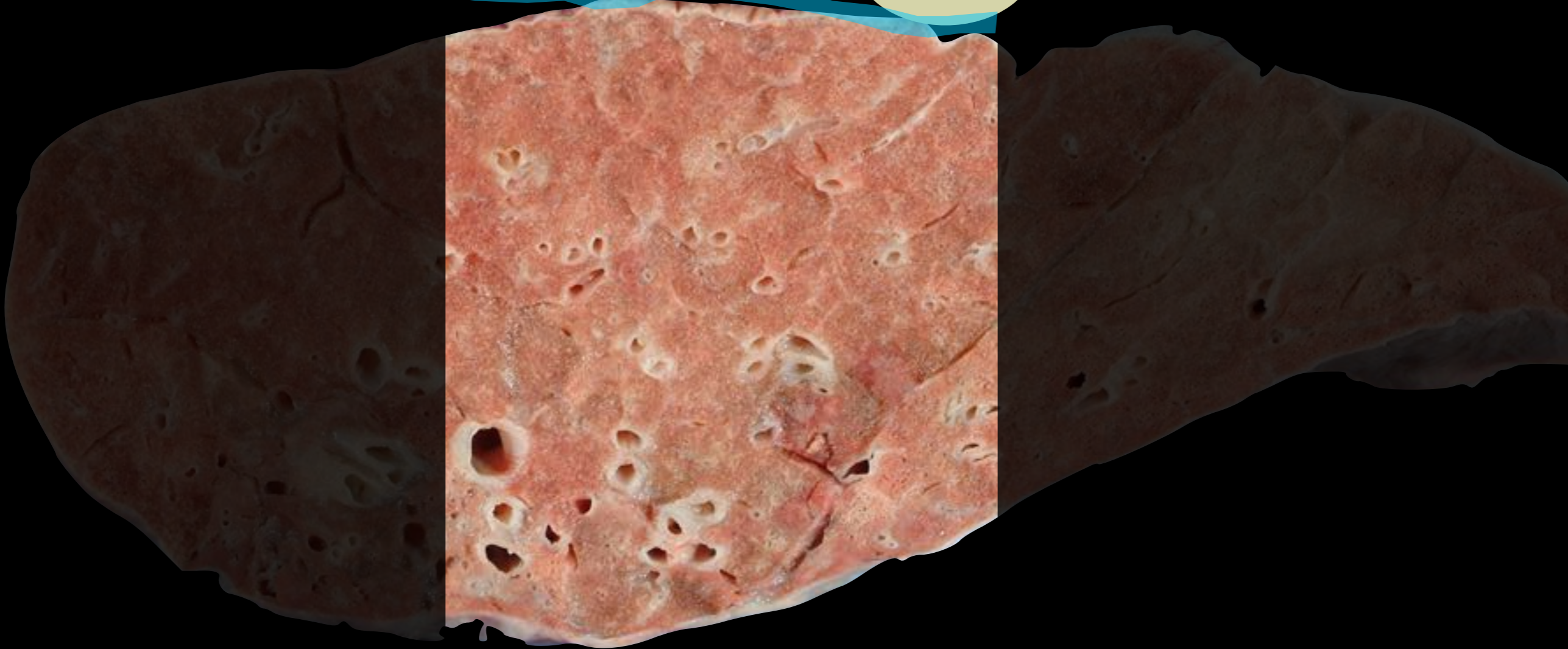
Rib



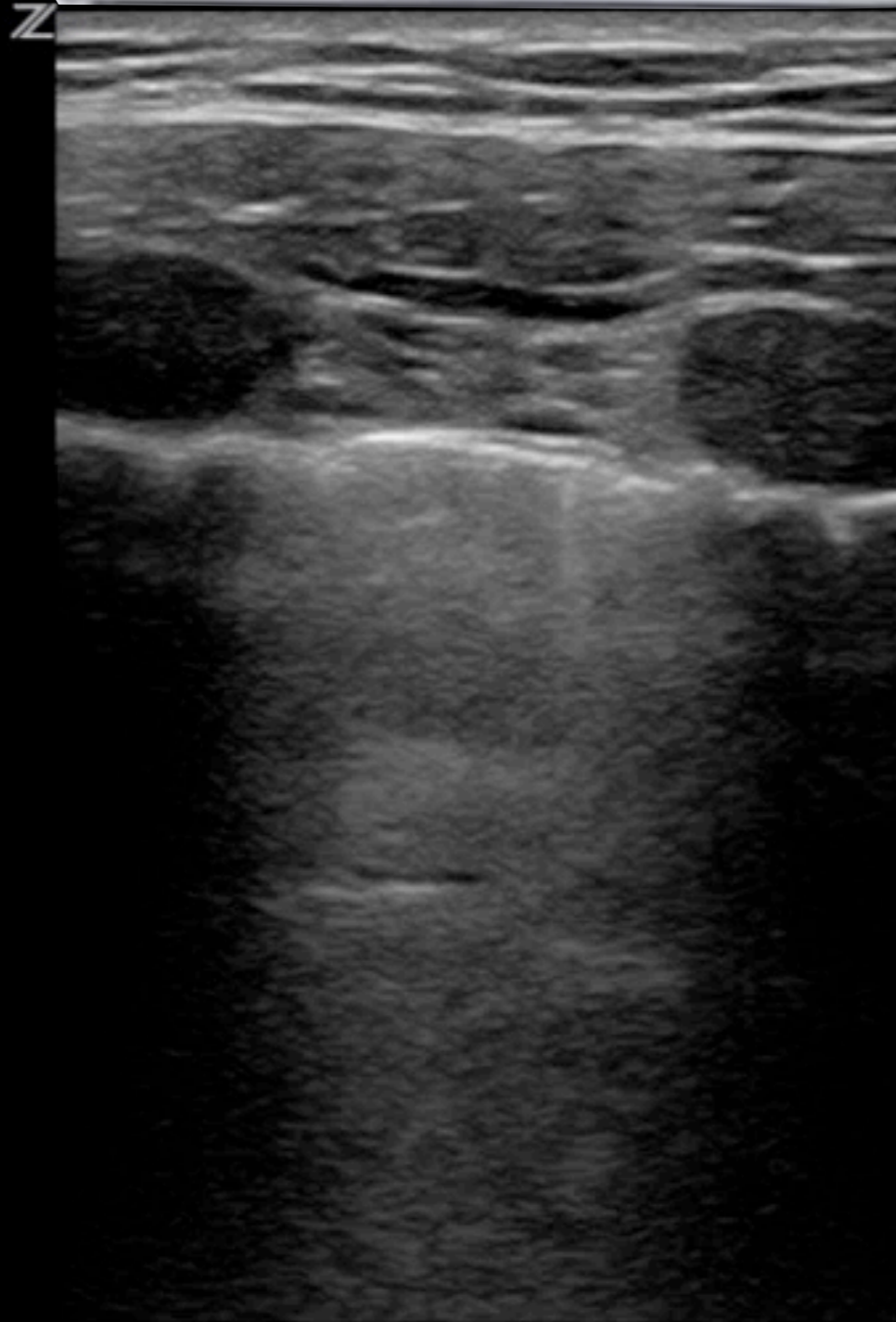
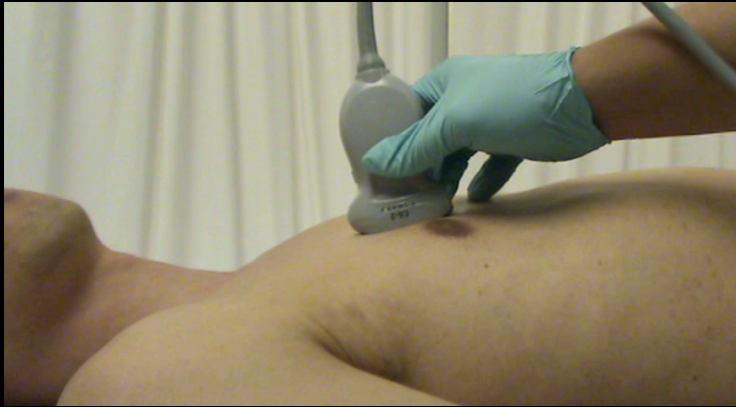

Rib

Rib

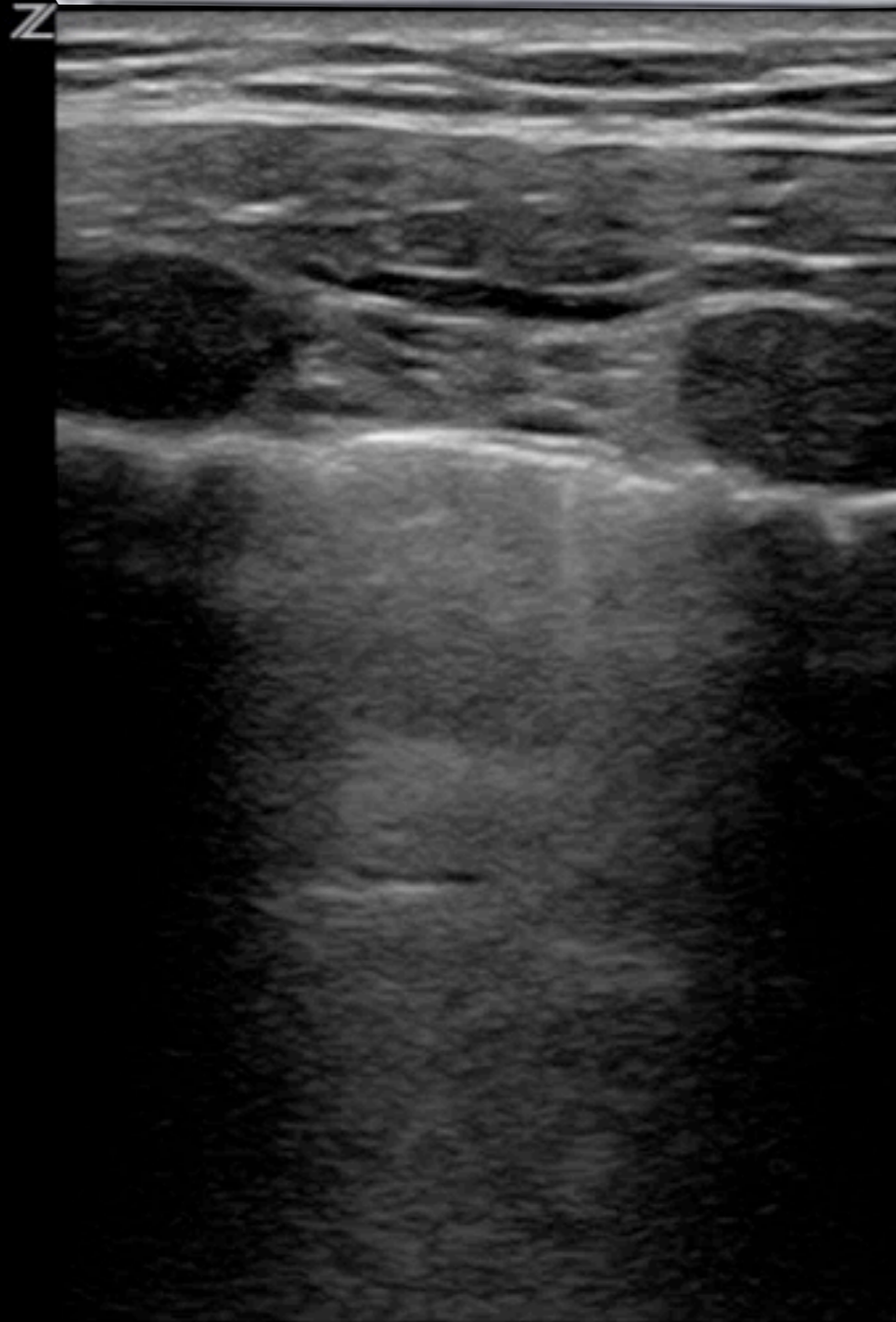


L10-5



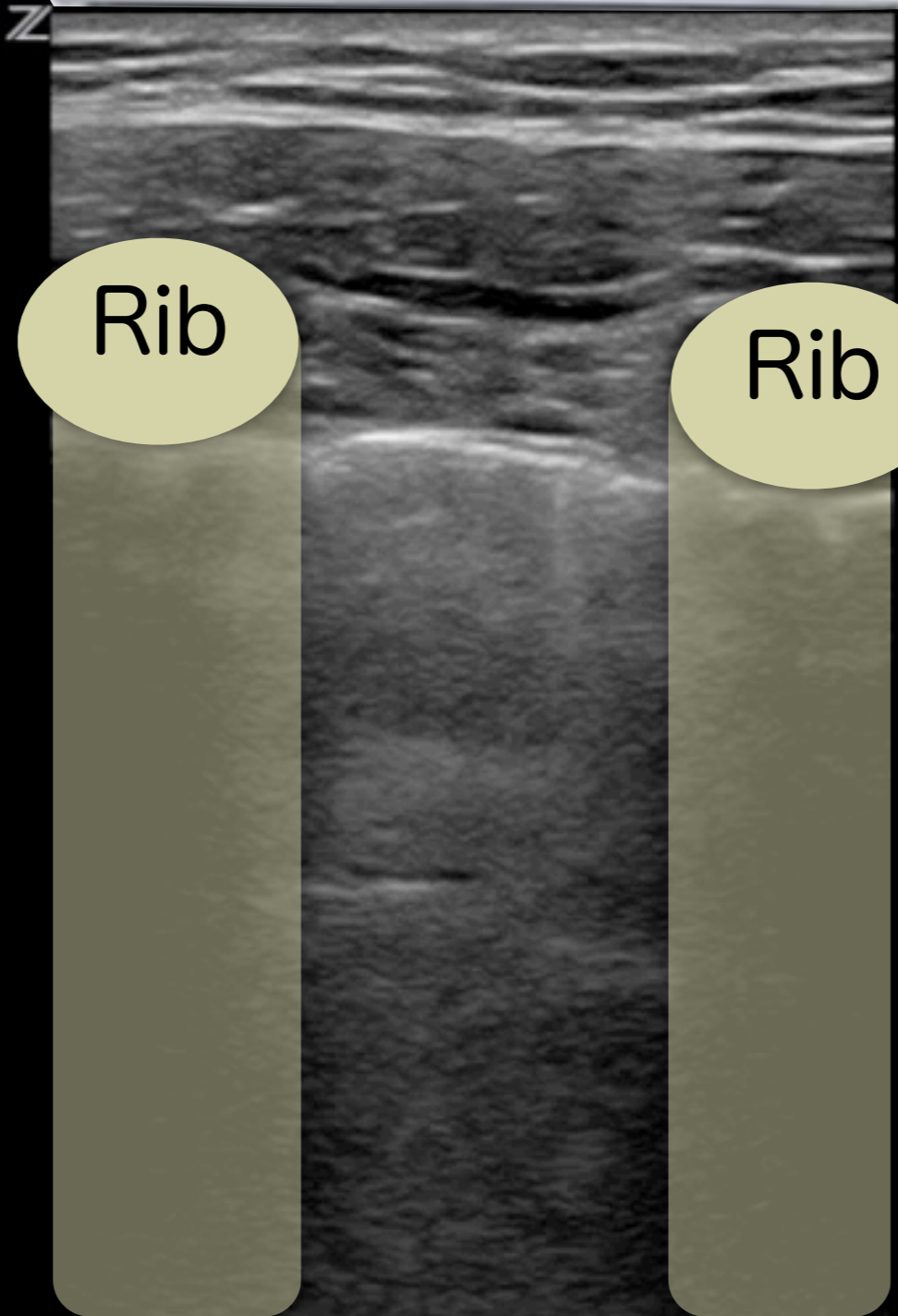
— Abd/PTX
L10-5/8.5MHz
· DR70/M3/P2
G92/E2/100%
- MI1.4 TIs0.1
6.0 cm
· 13 Hz
△ ZSI 0

L10-5



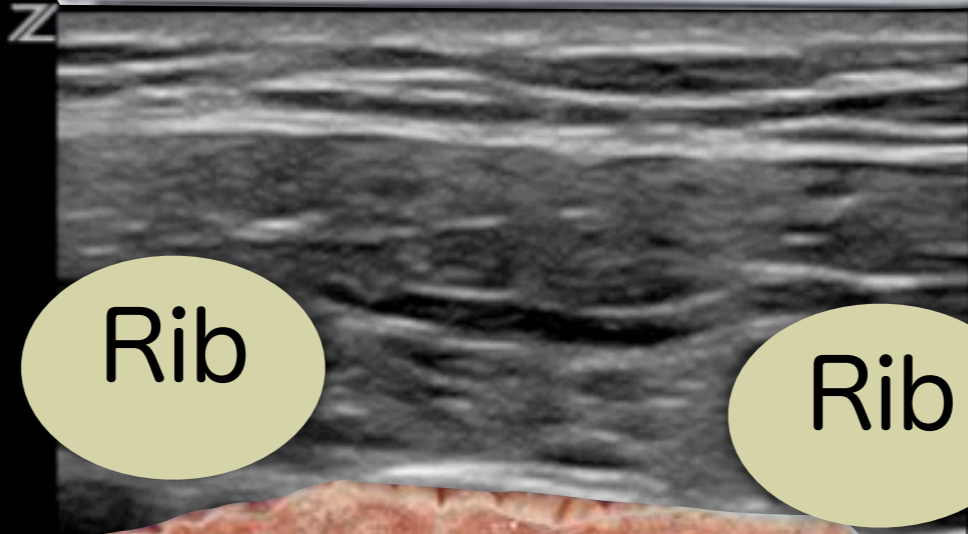
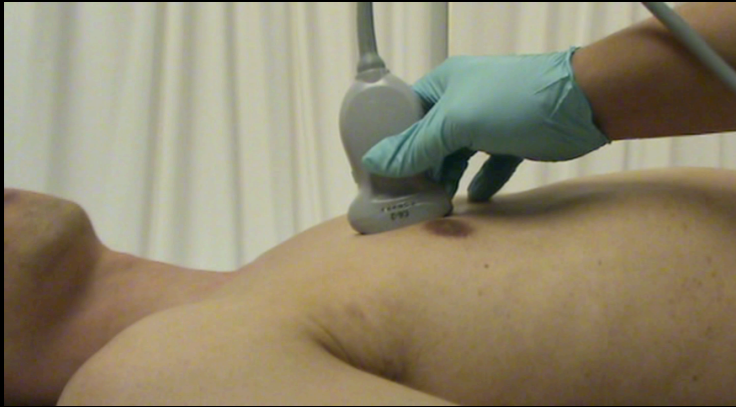
— Abd/PTX
L10-5/8.5MHz
· DR70/M3/P2
G92/E2/100%
- MI1.4 TIs0.1
6.0 cm
· 13 Hz
△ ZSI 0

L10-5

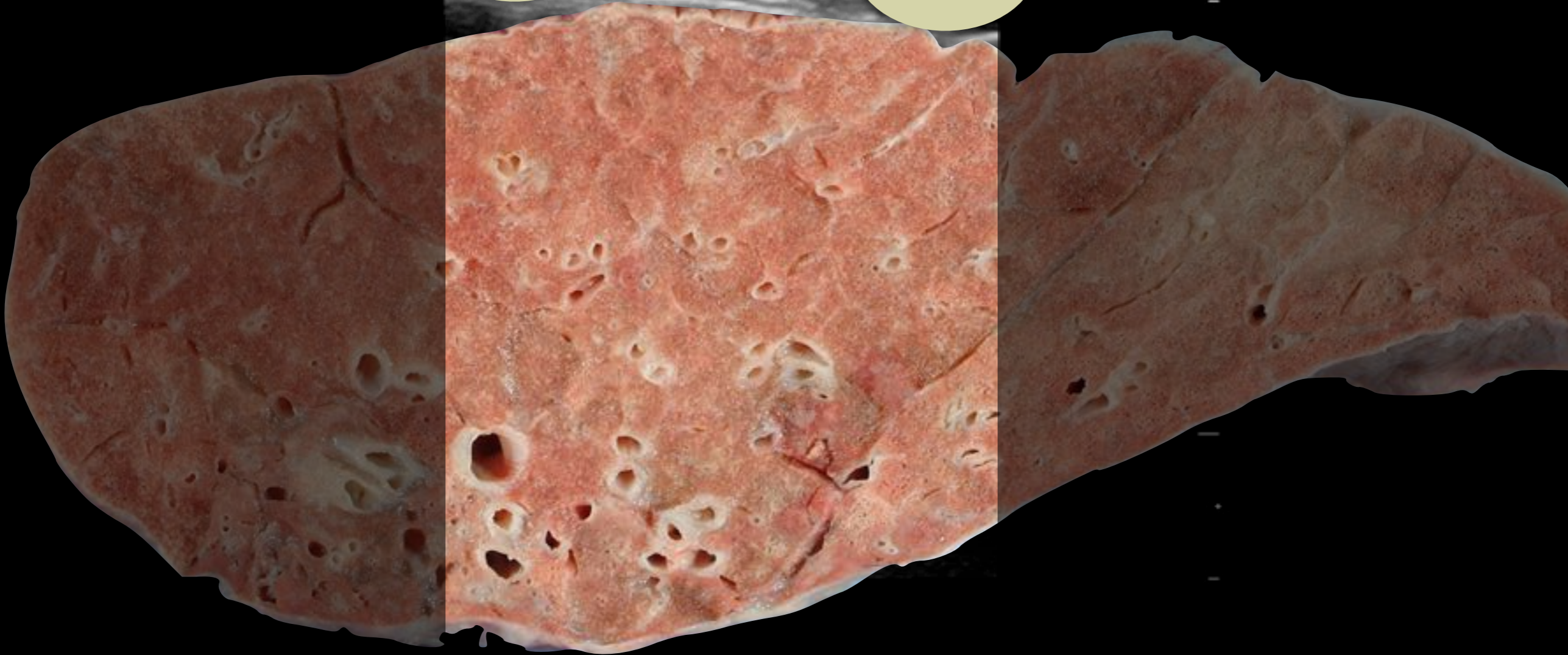


— Abd/PTX
L10-5/8.5MHz
· DR70/M3/P2
G92/E2/100%
- MI1.4 TIs0.1
6.0 cm
· 13 Hz
△ ZSI 0

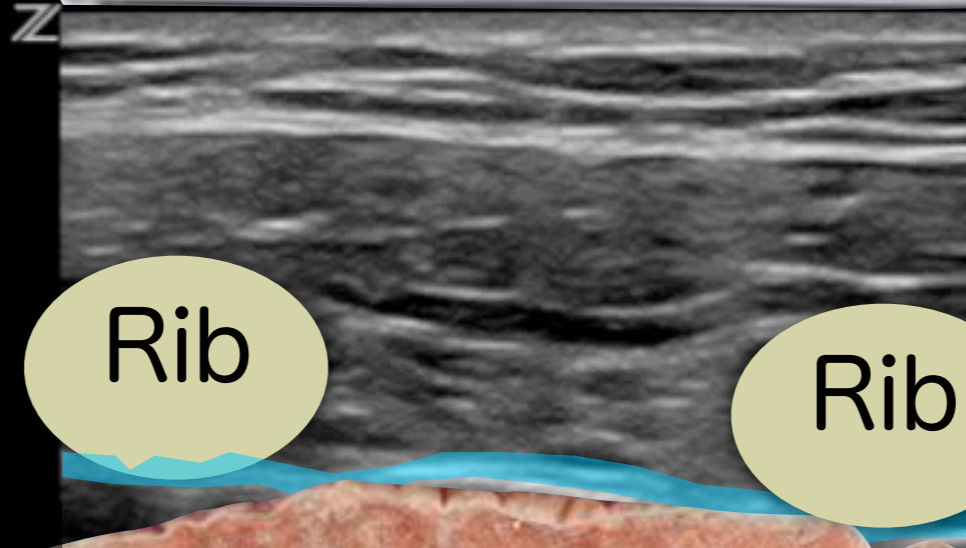
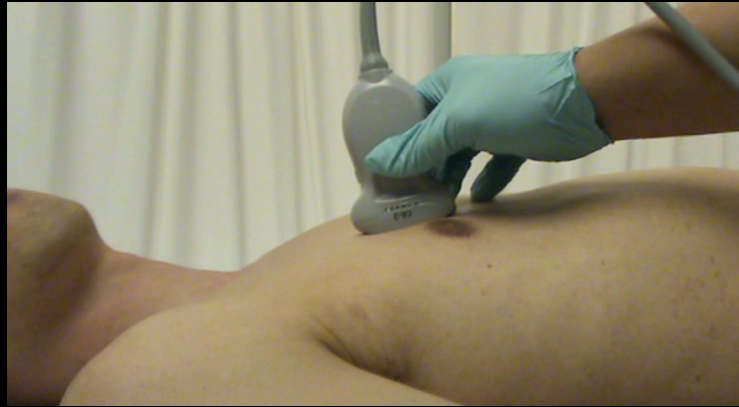L10-5



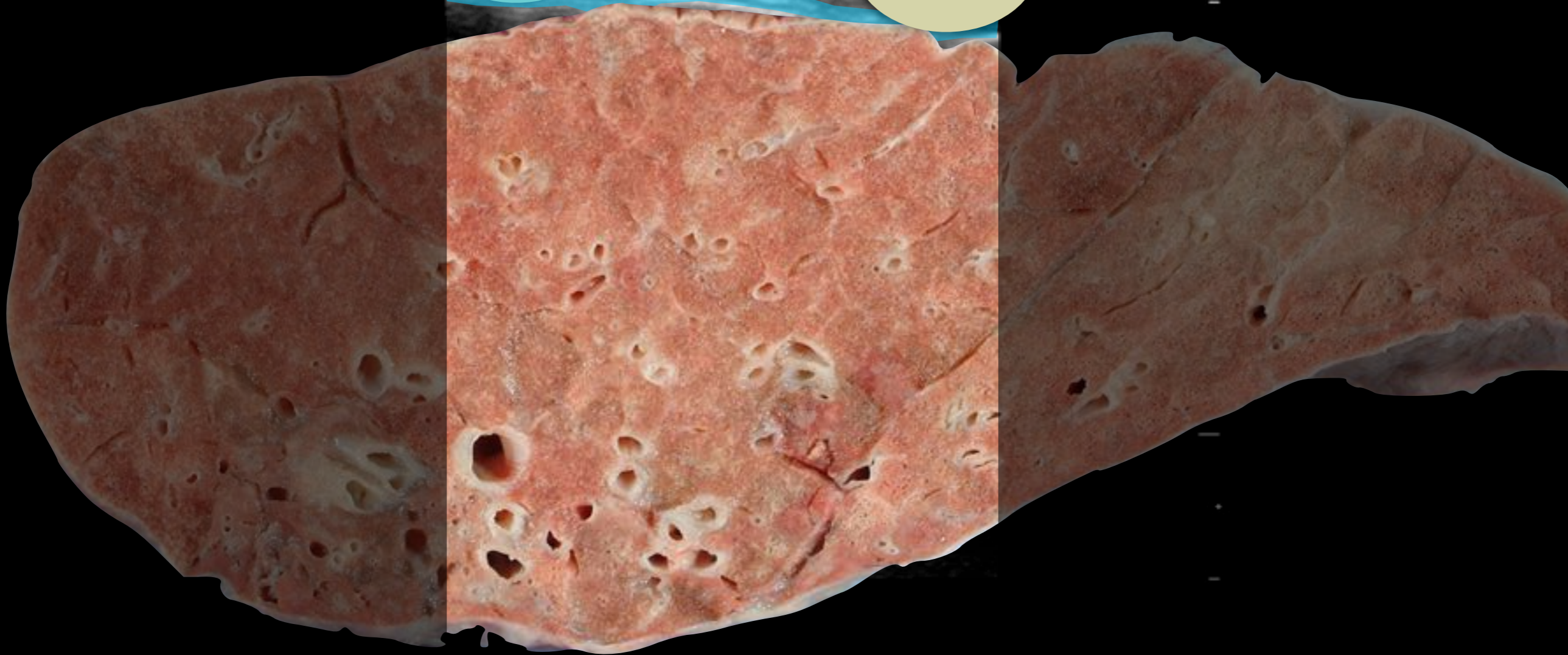
— Abd/PTX
L10-5/8.5MHz
· DR70/M3/P2
G92/E2/100%
- MI1.4 TIs0.1
6.0 cm
· 13 Hz
△ ZSI 0



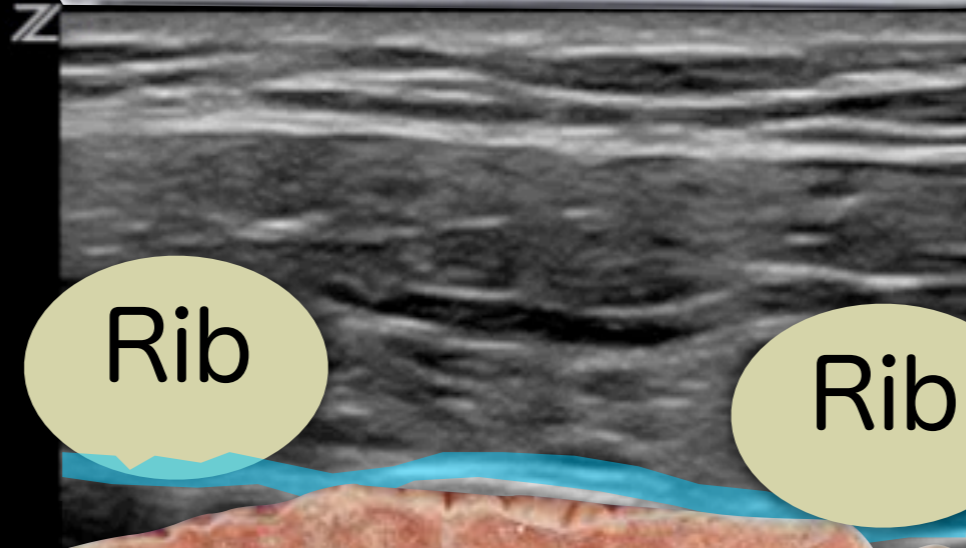
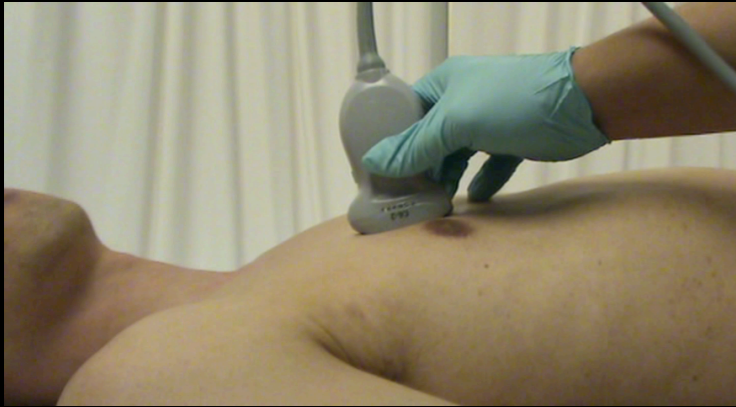
L10-5



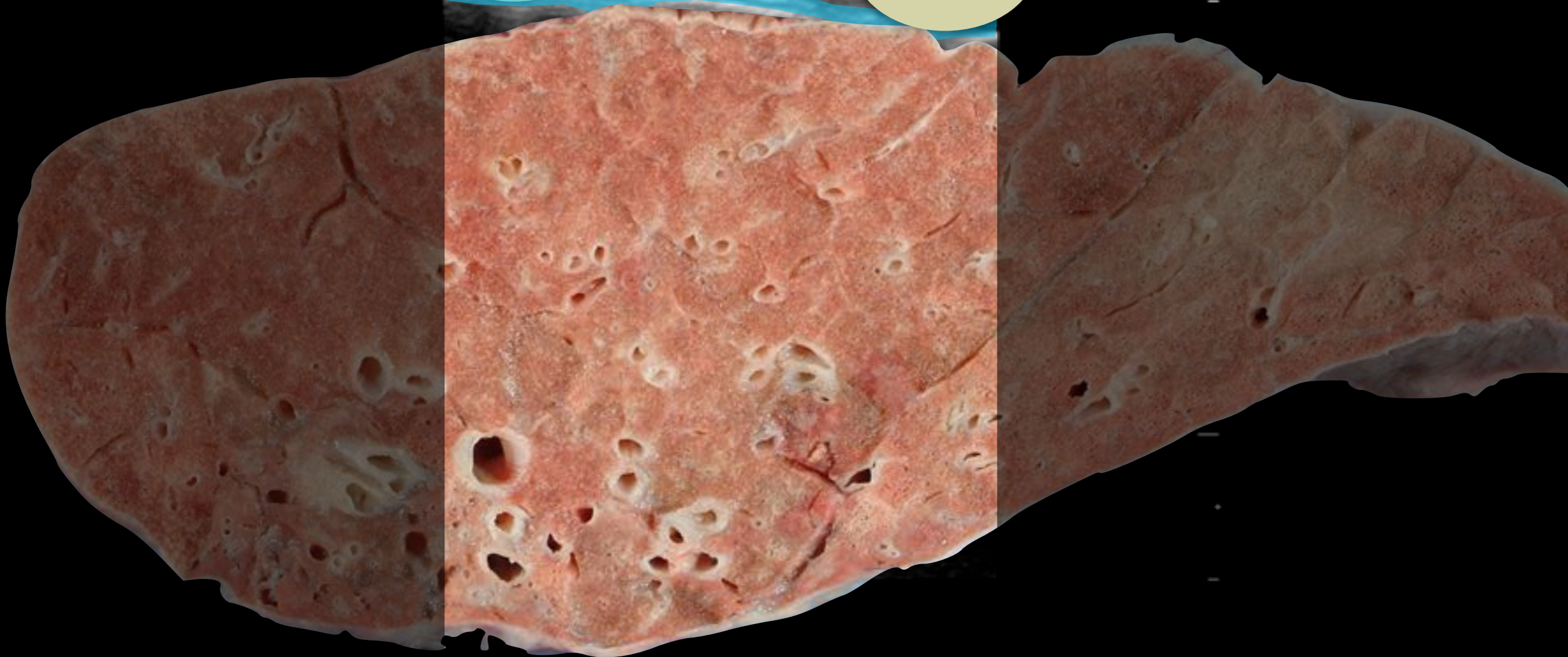
— Abd/PTX
L10-5/8.5MHz
· DR70/M3/P2
G92/E2/100%
- MI1.4 TIs0.1
6.0 cm
· 13 Hz
△ ZSI 0



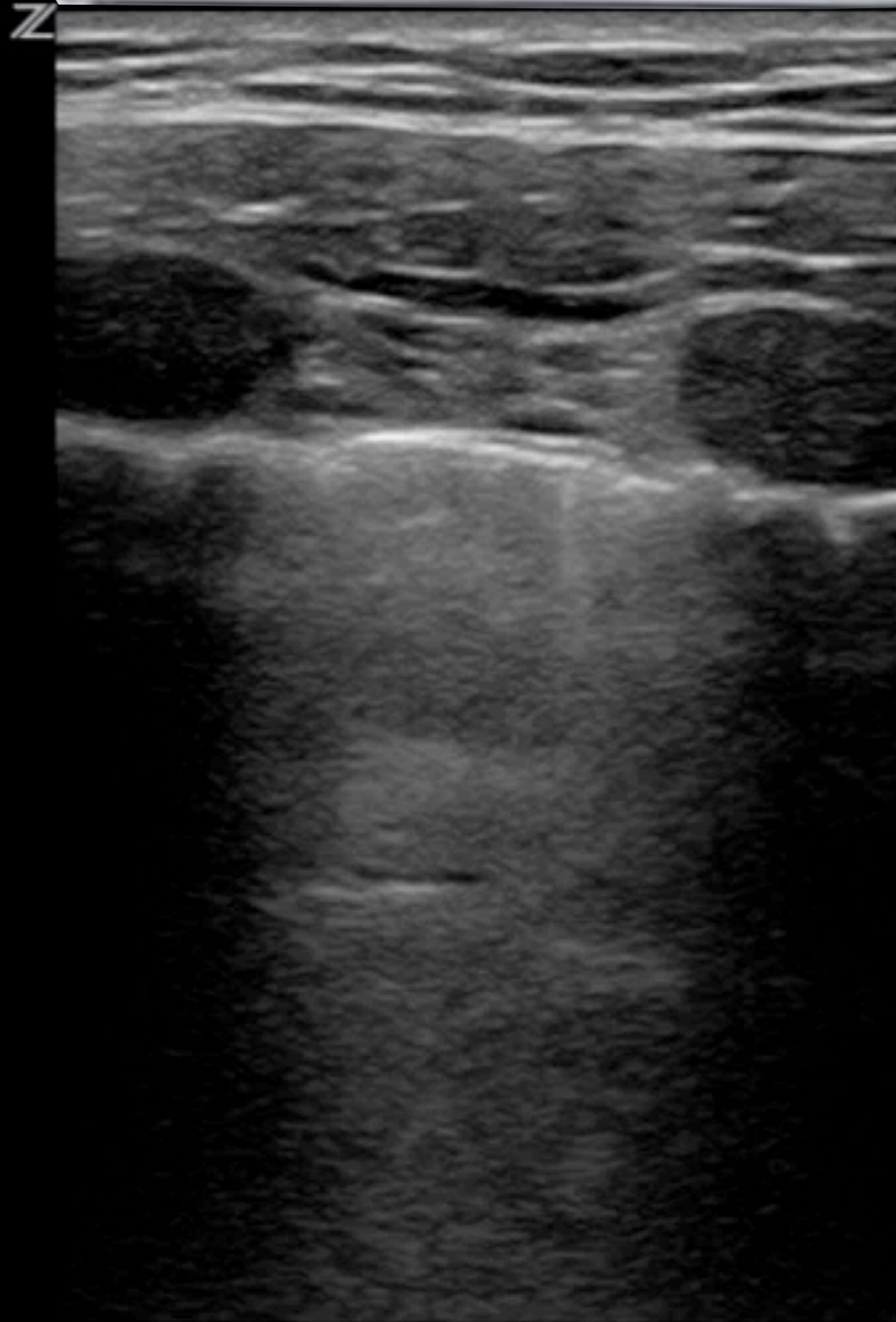
L10-5



— Abd/PTX
L10-5/8.5MHz
· DR70/M3/P2
G92/E2/100%
- MI1.4 TIs0.1
6.0 cm
· 13 Hz
△ ZSI 0

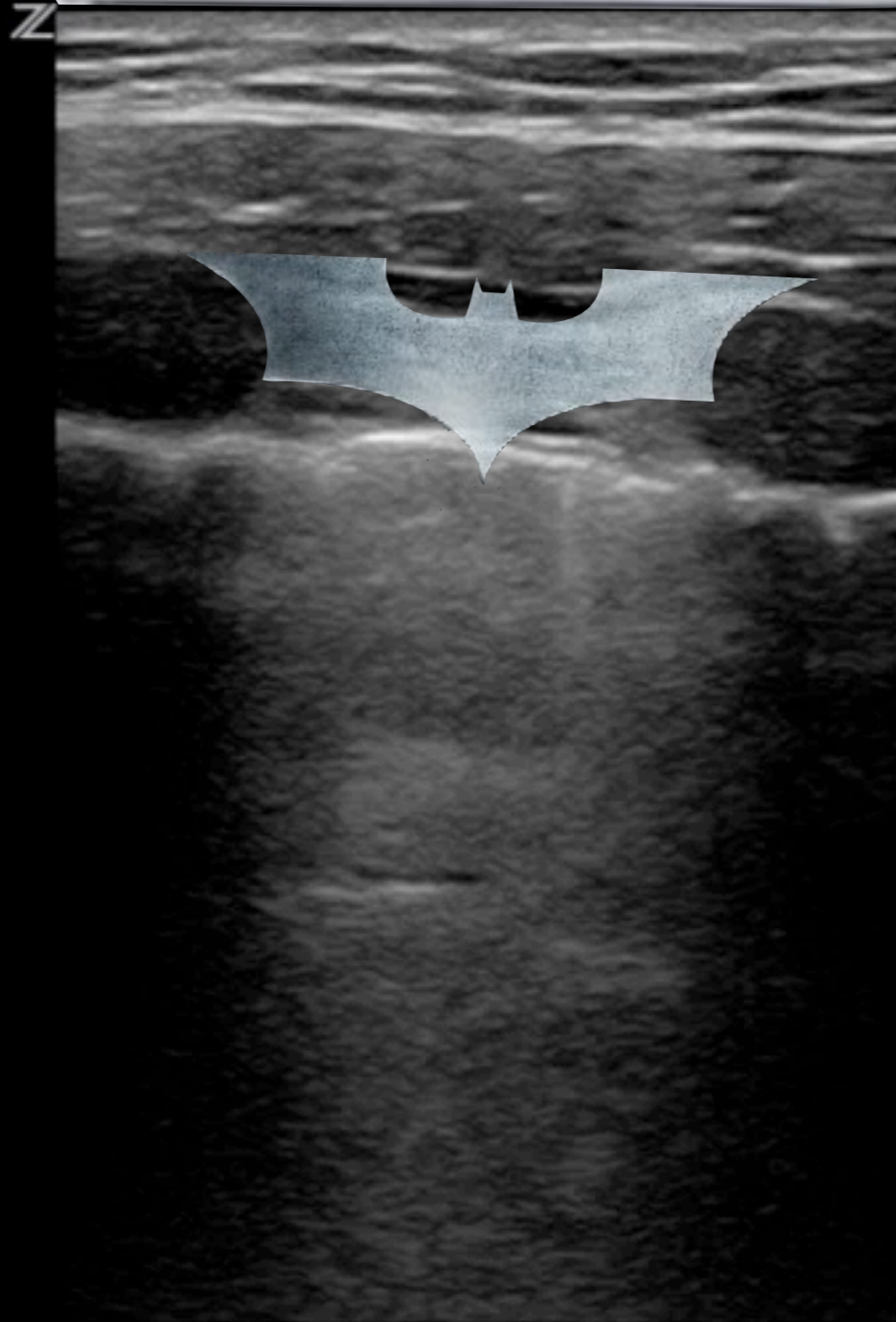

L10-5



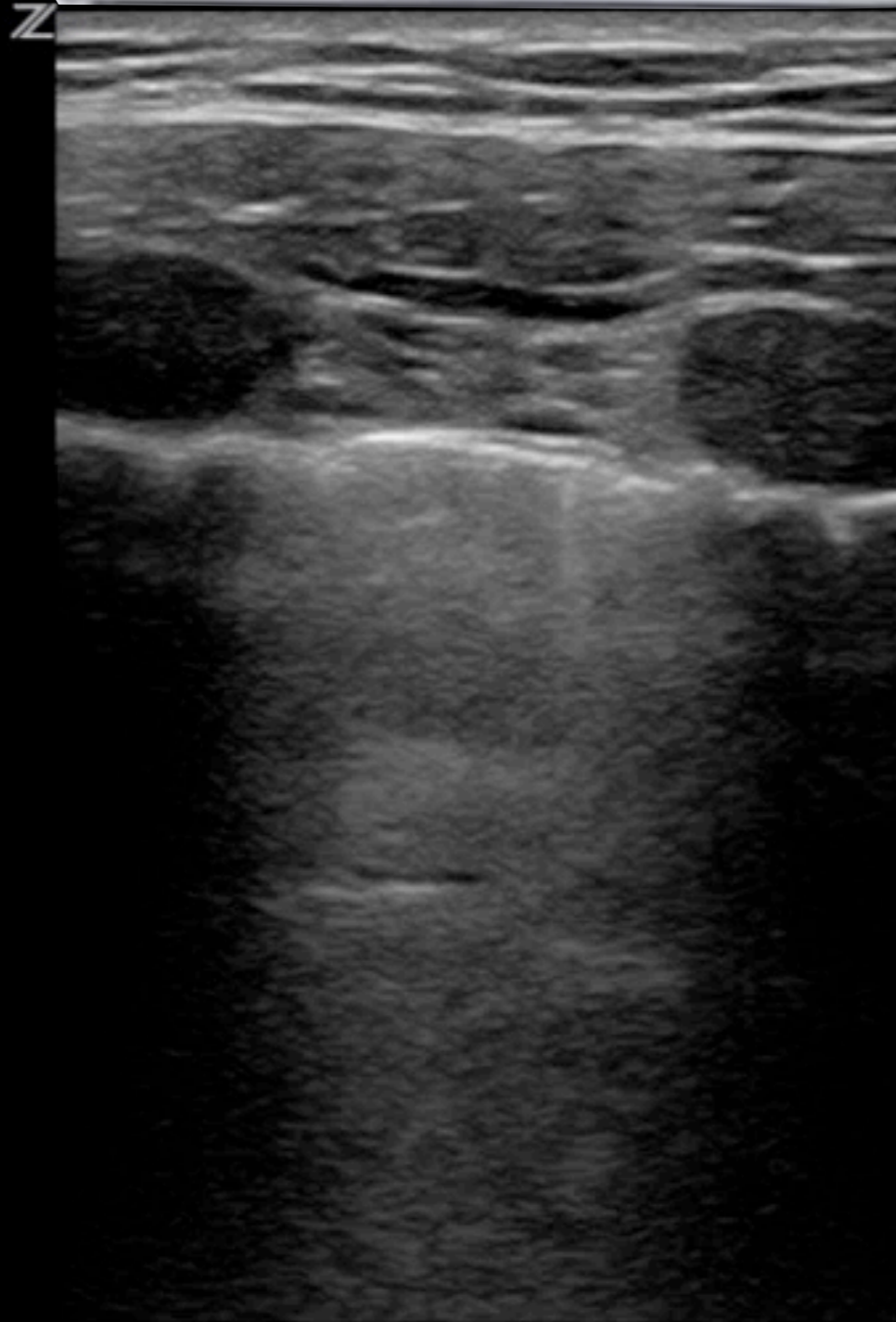
— Abd/PTX
L10-5/8.5MHz
· DR70/M3/P2
G92/E2/100%
- MI1.4 TIs0.1
6.0 cm
· 13 Hz
△ ZSI 0

L10-5



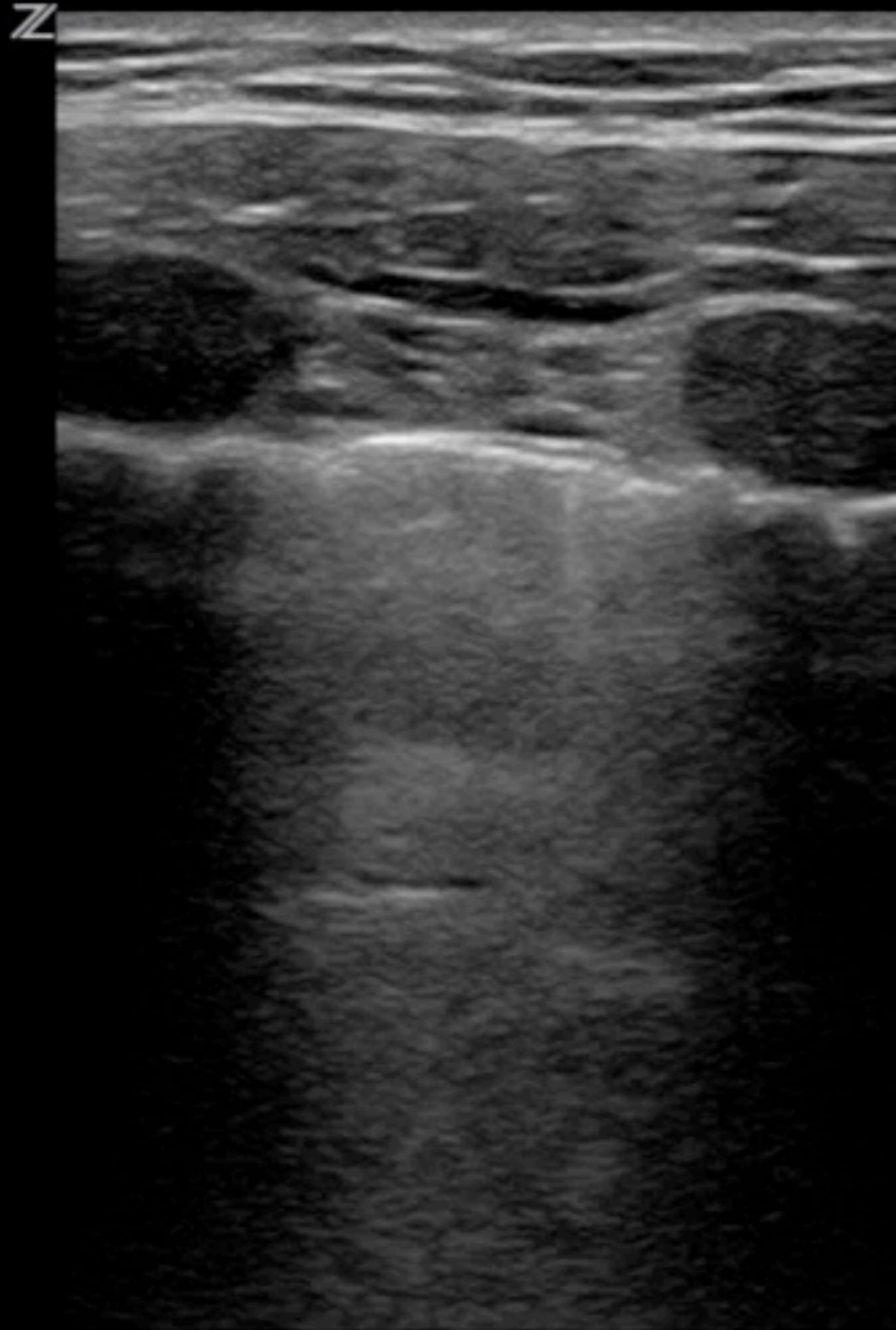
— Abd/PTX
L10-5/8.5MHz
· DR70/M3/P2
G92/E2/100%
- MI1.4 TIs0.1
6.0 cm
· 13 Hz
△ ZSI 0

L10-5



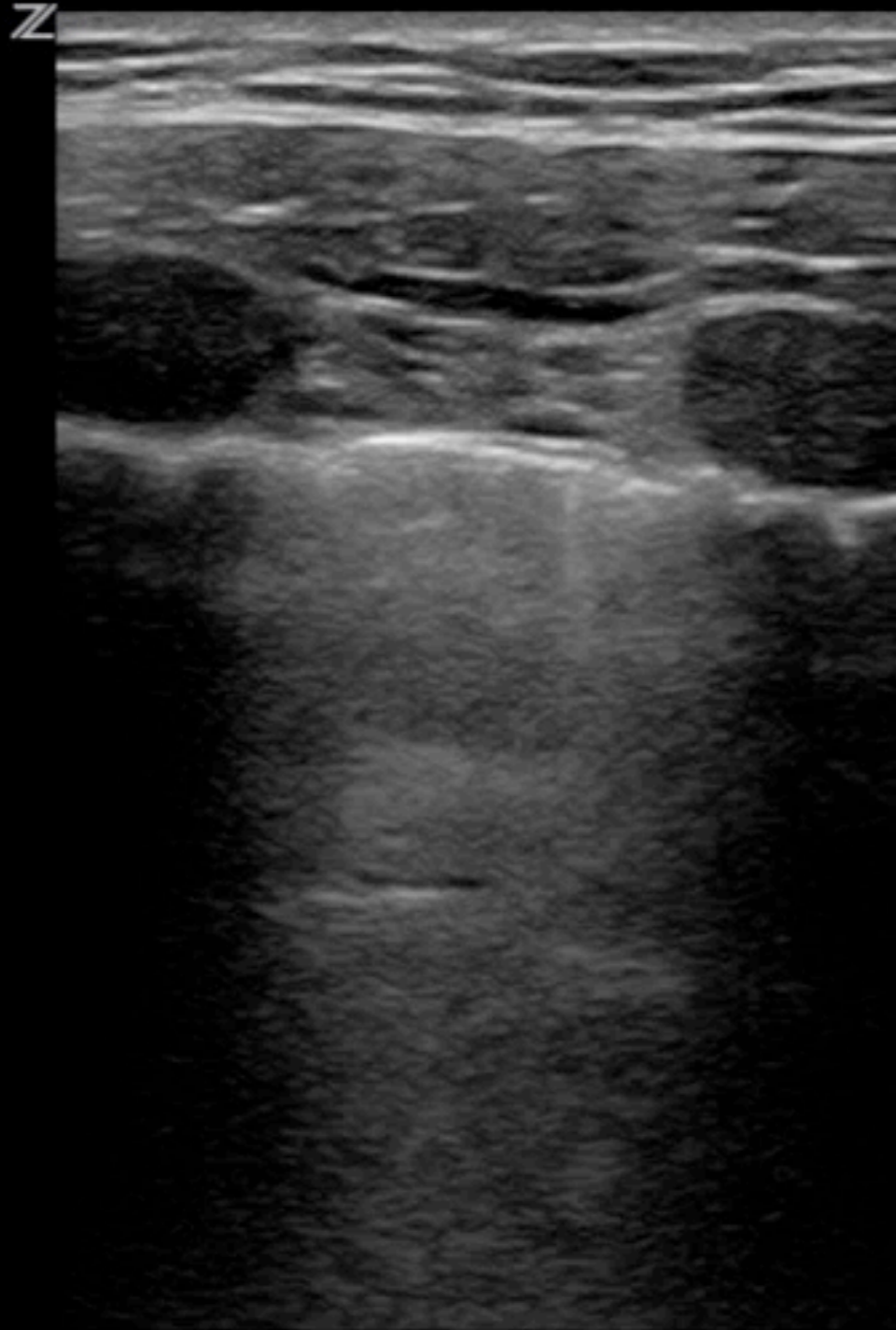
— Abd/PTX
L10-5/8.5MHz
· DR70/M3/P2
G92/E2/100%
- MI1.4 TIs0.1
6.0 cm
· 13 Hz
△ ZSI 0

Lung sliding



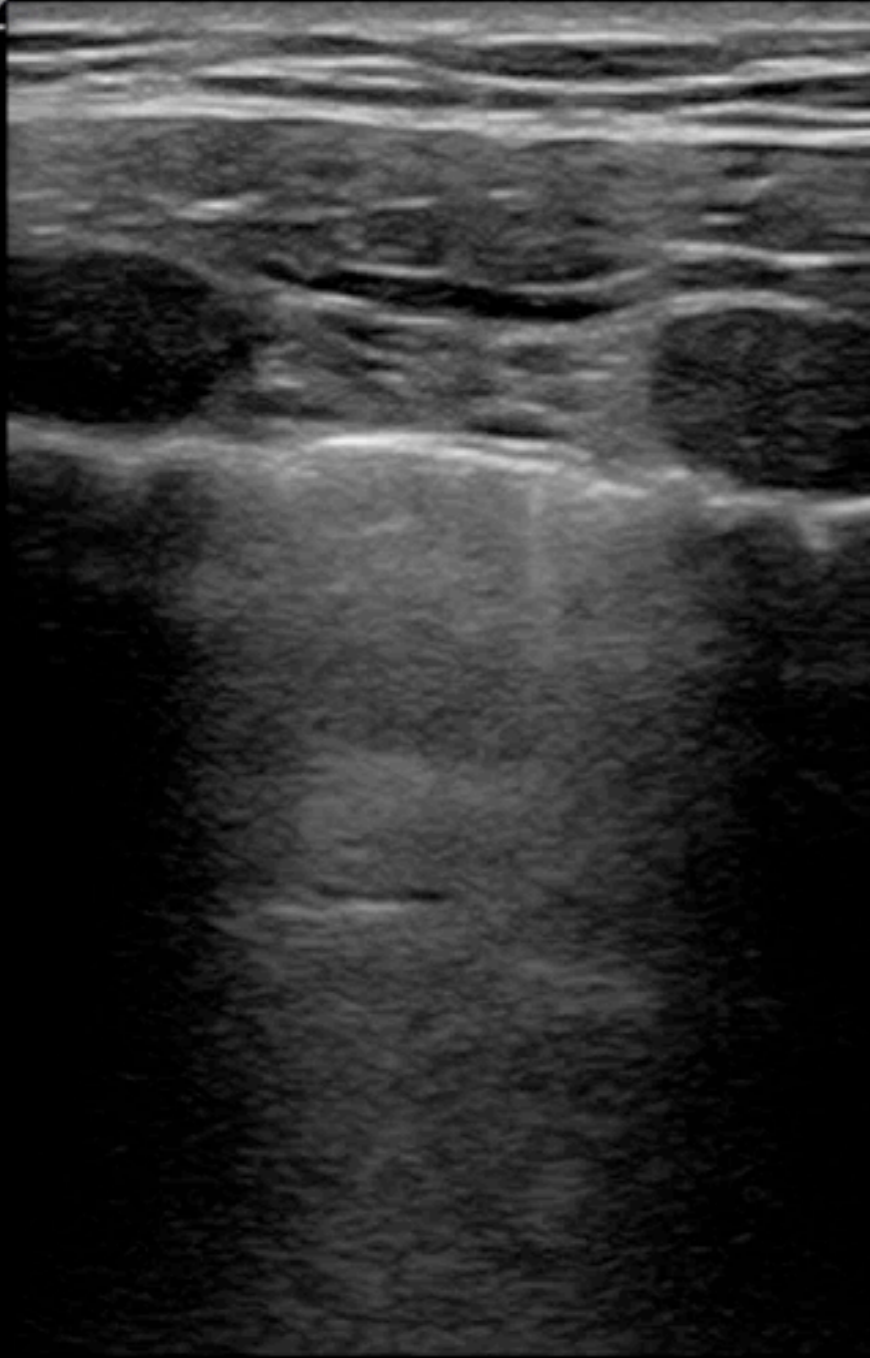
— Abd/PTX
L10-5/8.5MHz
· DR70/M3/P2
G92/E2/100%
- MI1.4 TIs0.1
6.0 cm
· 13 Hz
△ ZSI 0

Lung sliding

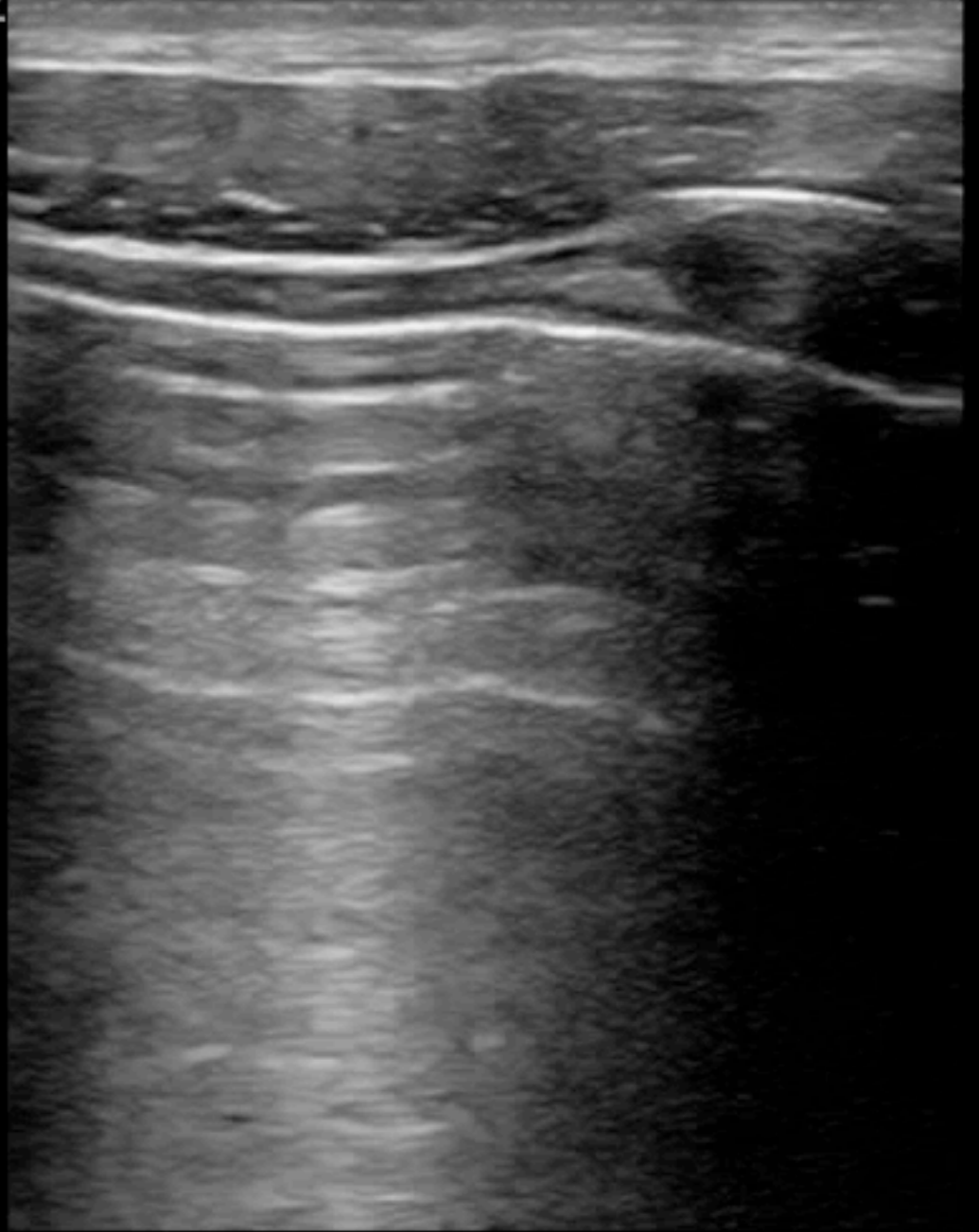

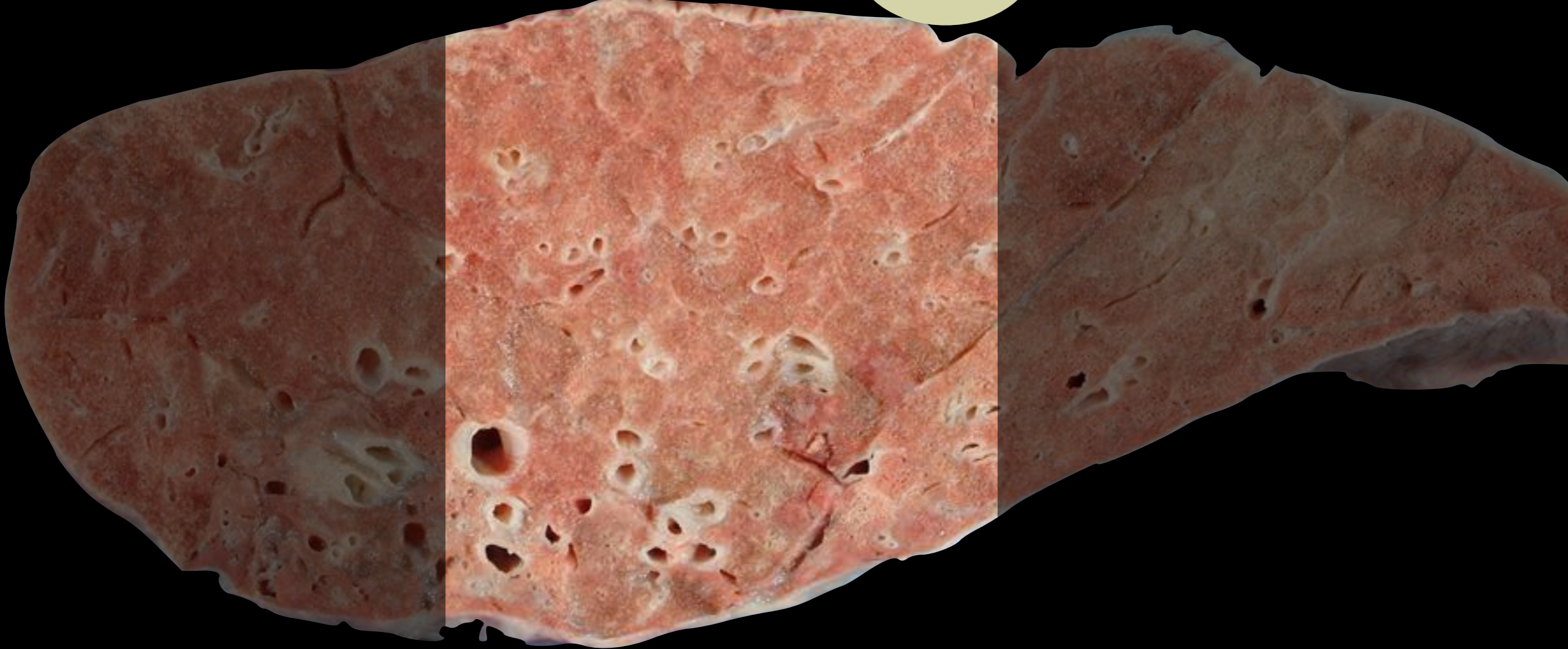
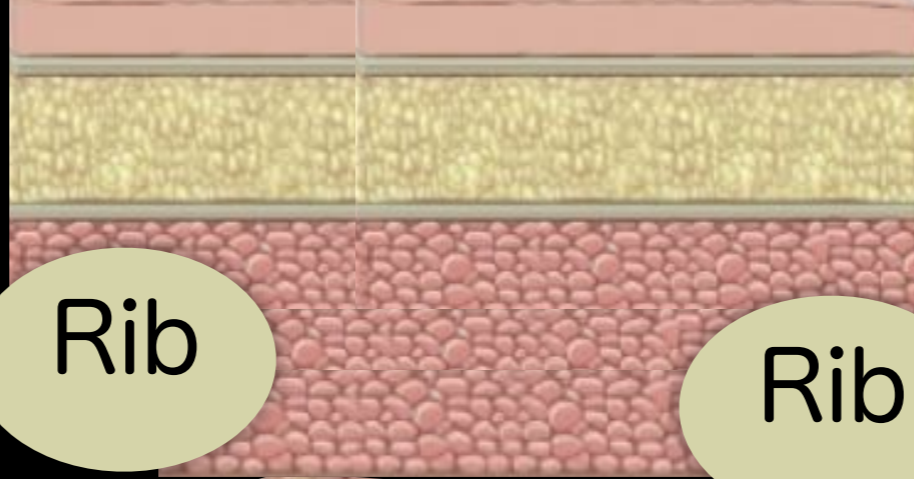
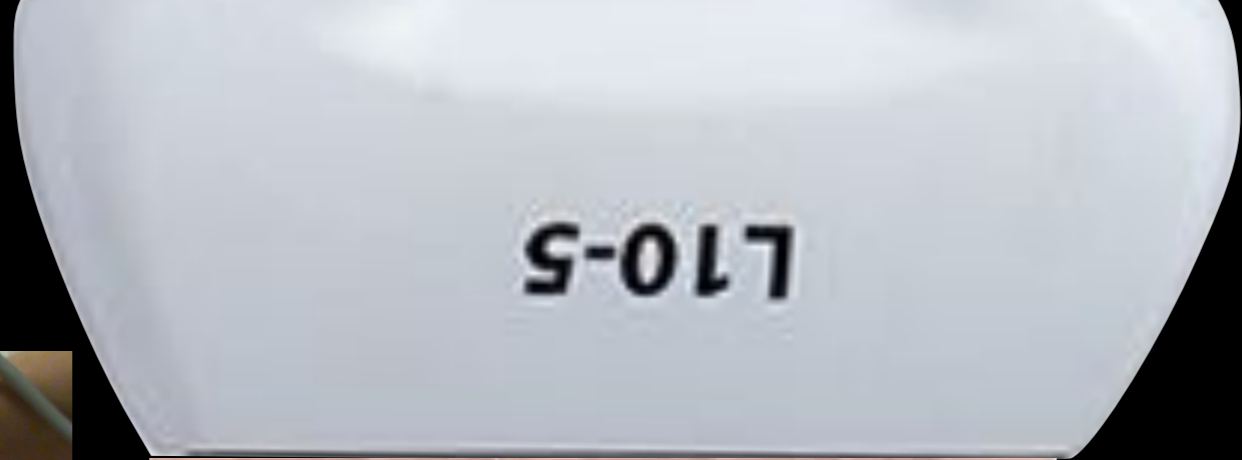— Abd/PTX
L10-5/8.5MHz
· DR70/M3/P2
G92/E2/100%
- MI1.4 TIs0.1
6.0 cm
· 13 Hz
△ ZSI 0

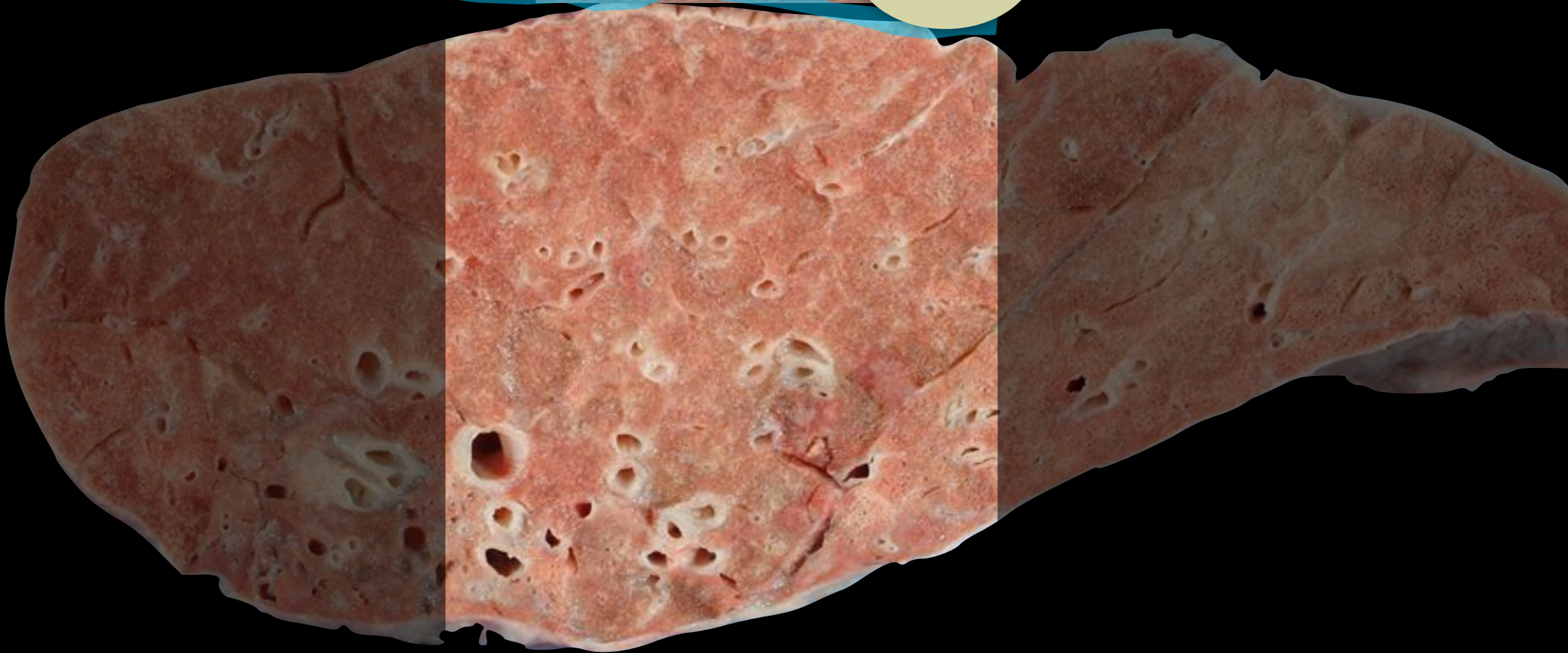
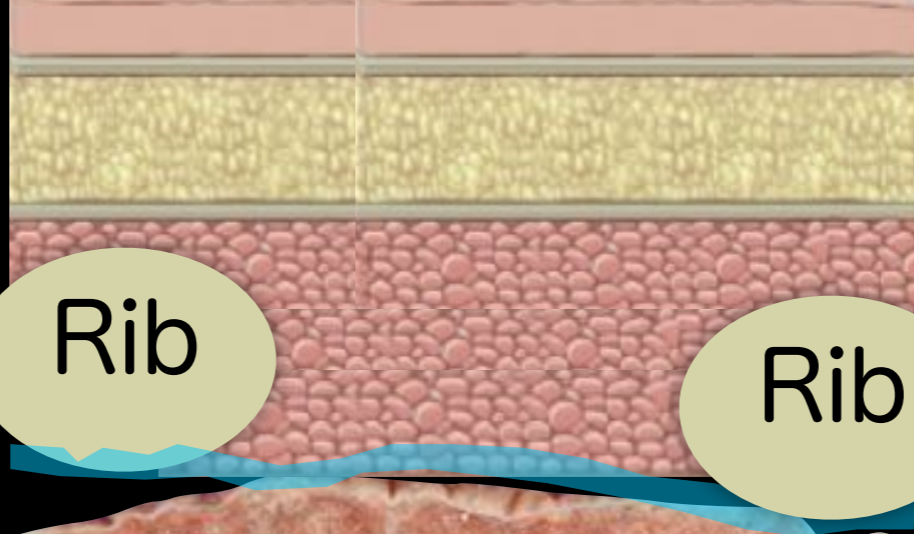
Z

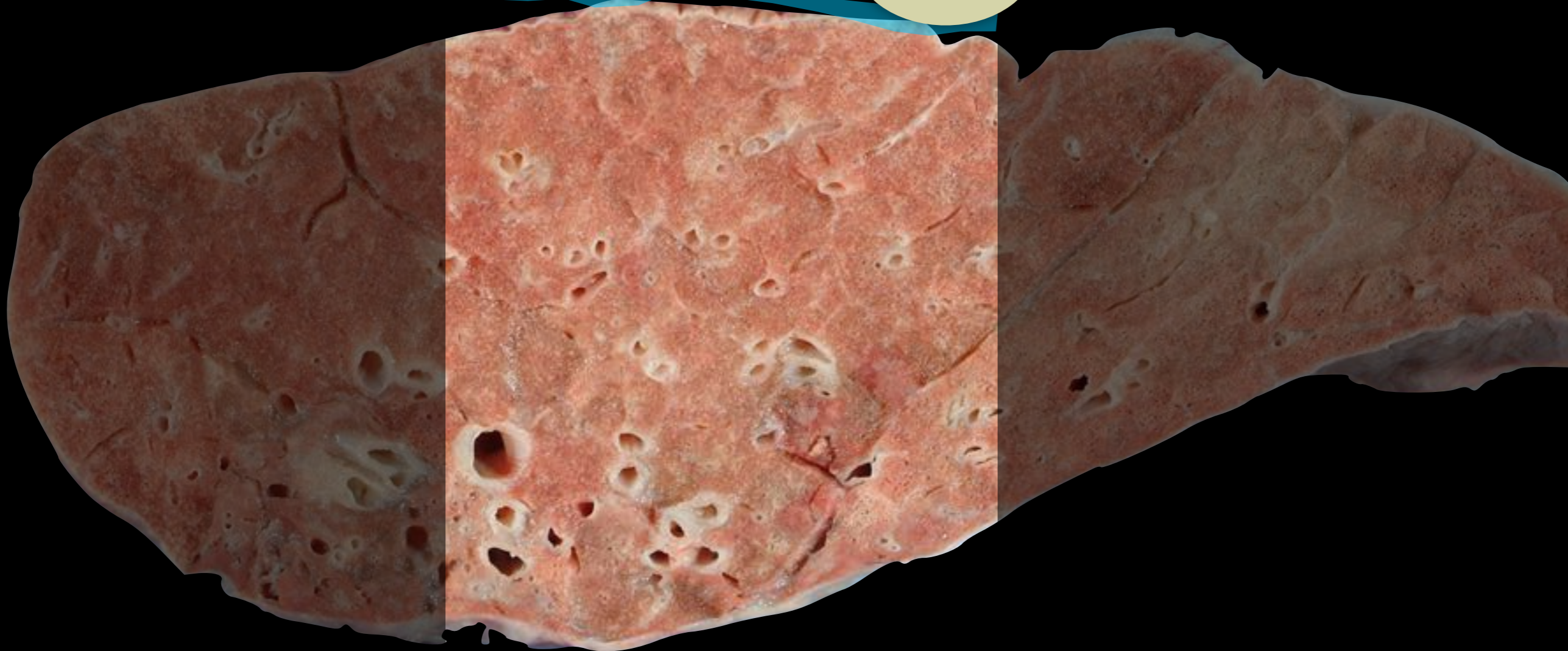
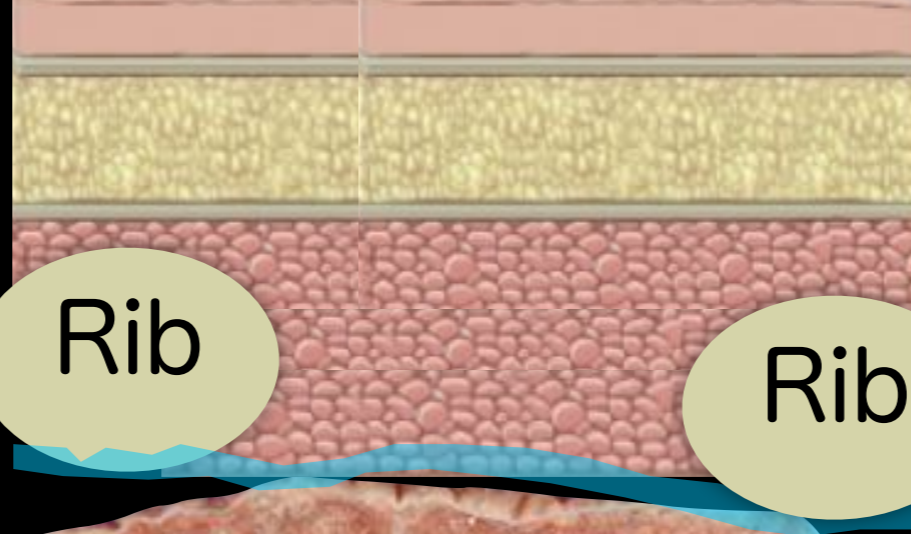
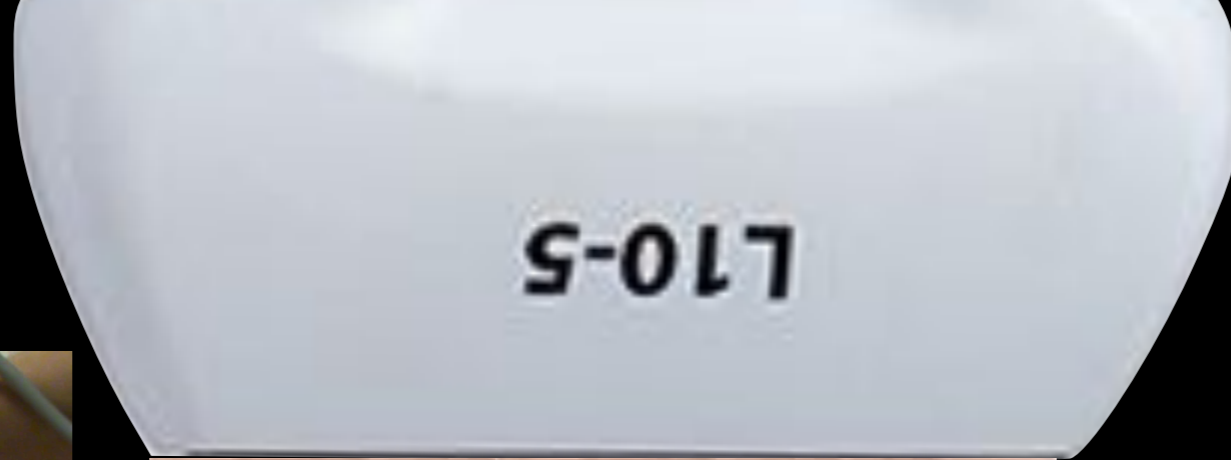

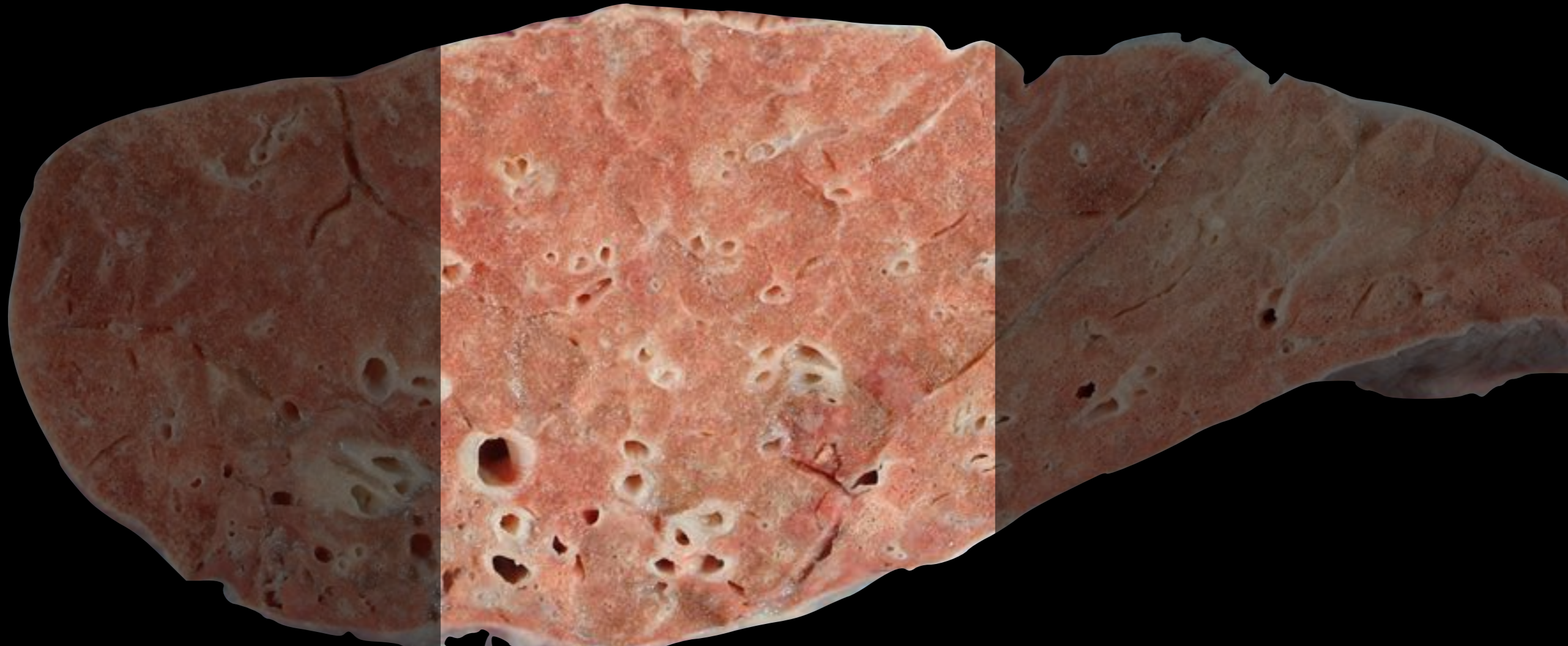
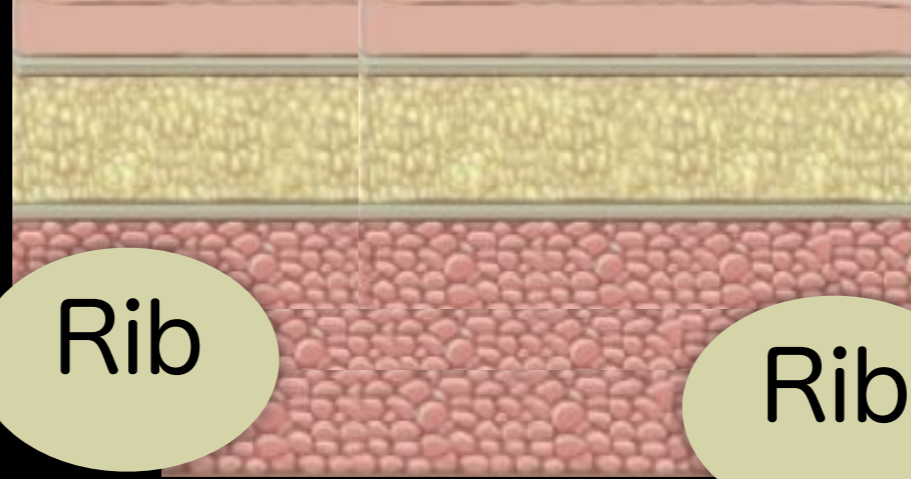
Z

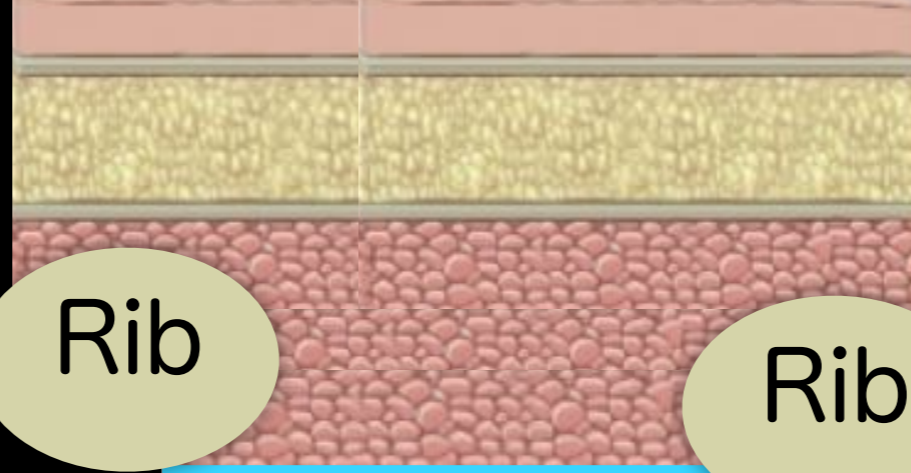






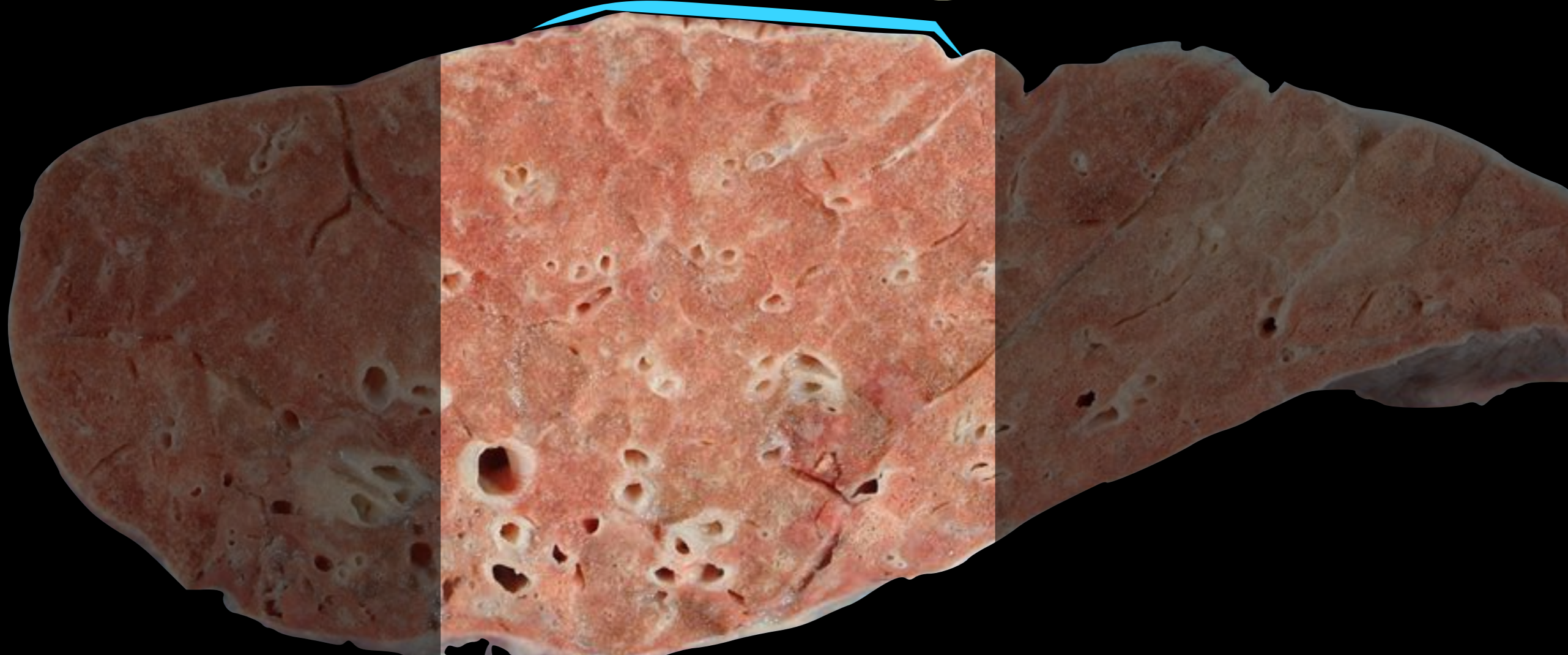


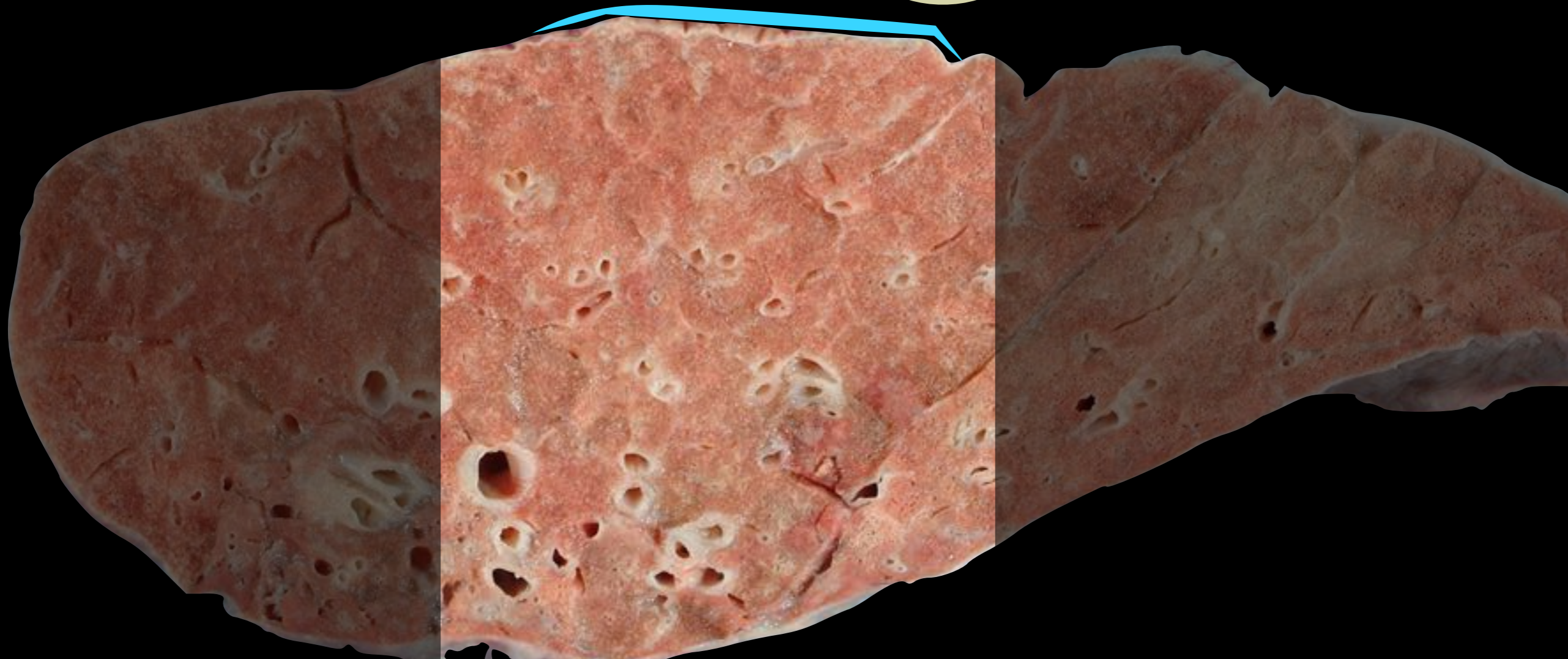
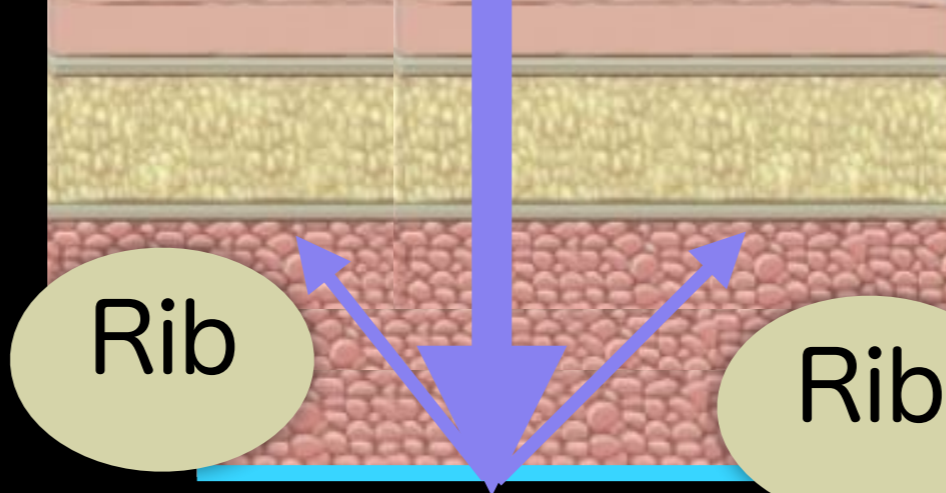
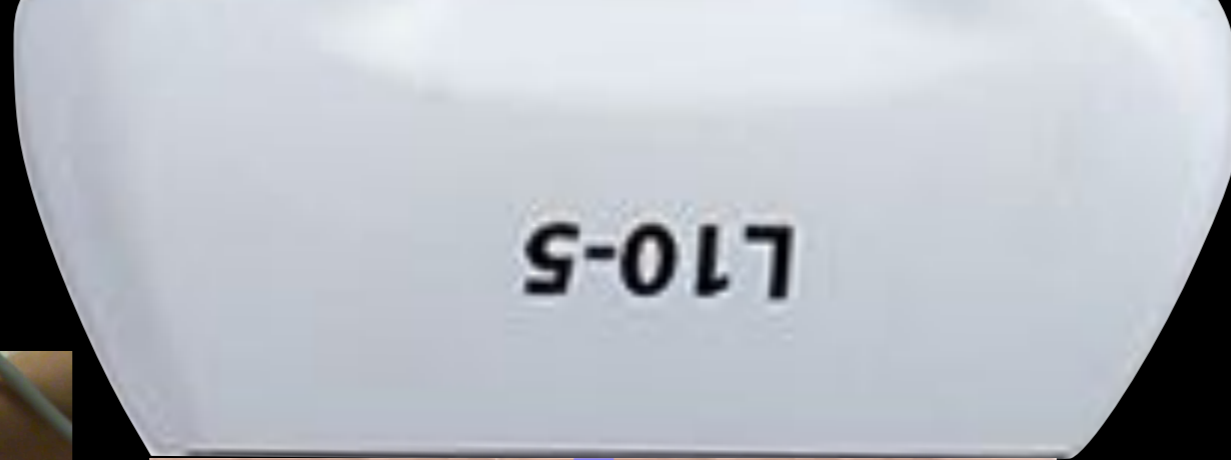


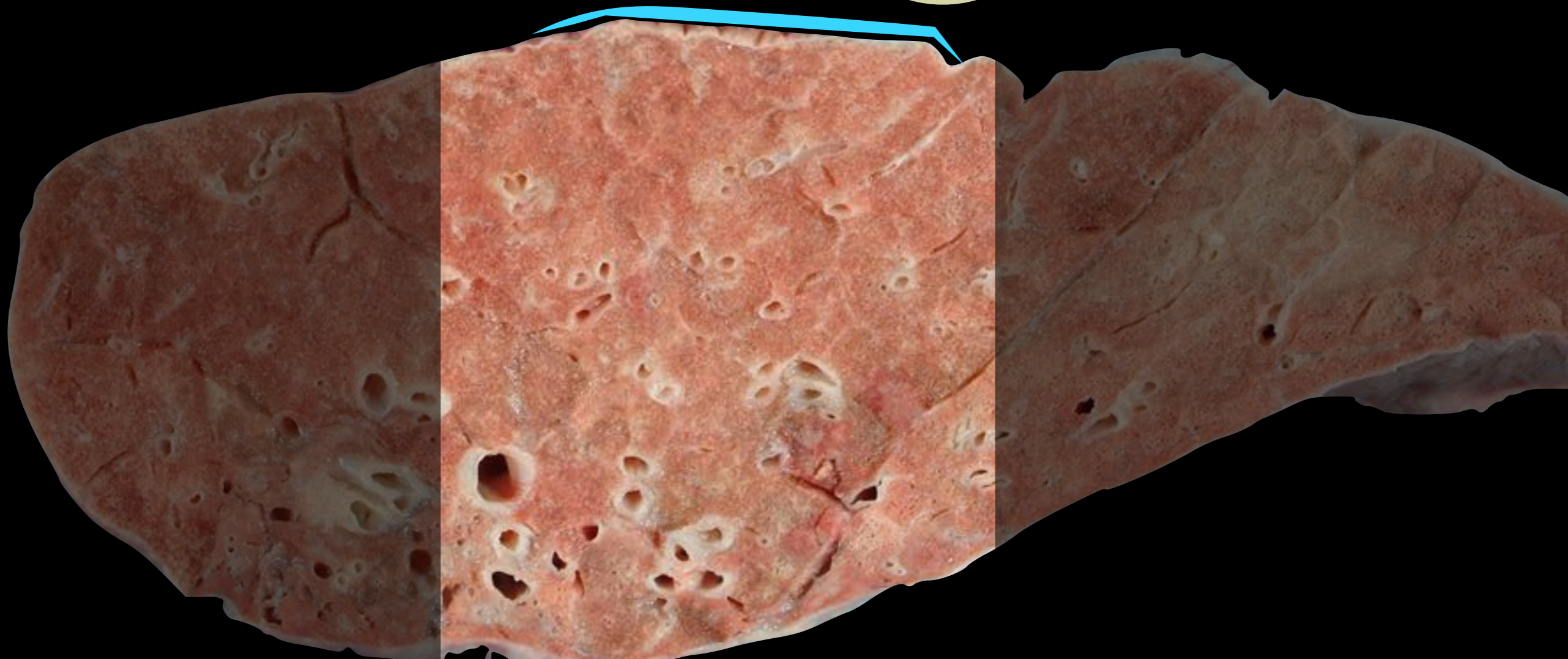
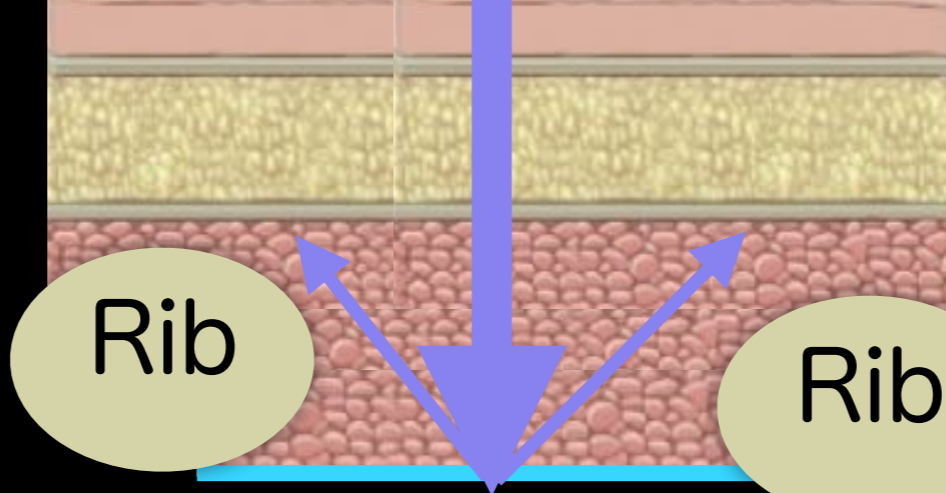
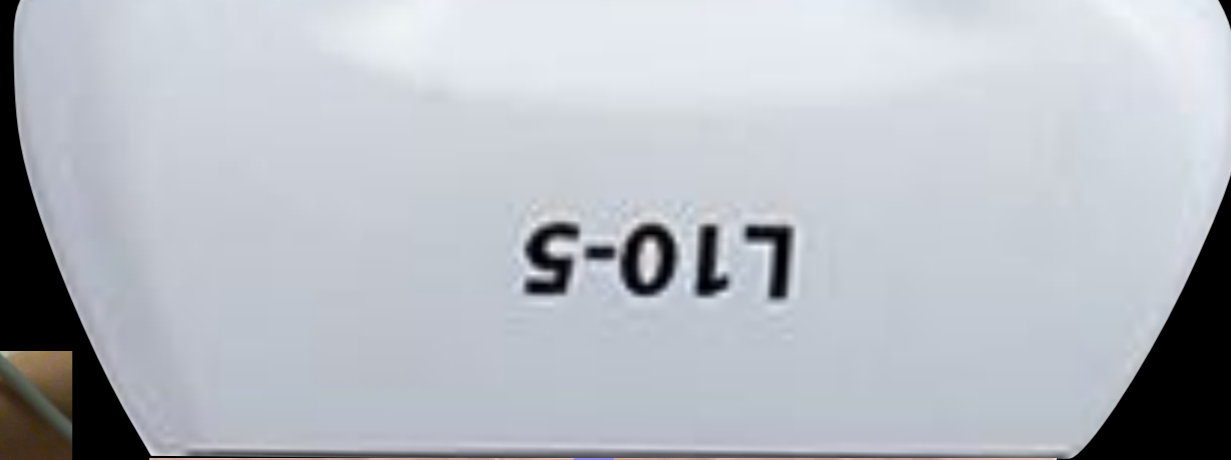


Rib

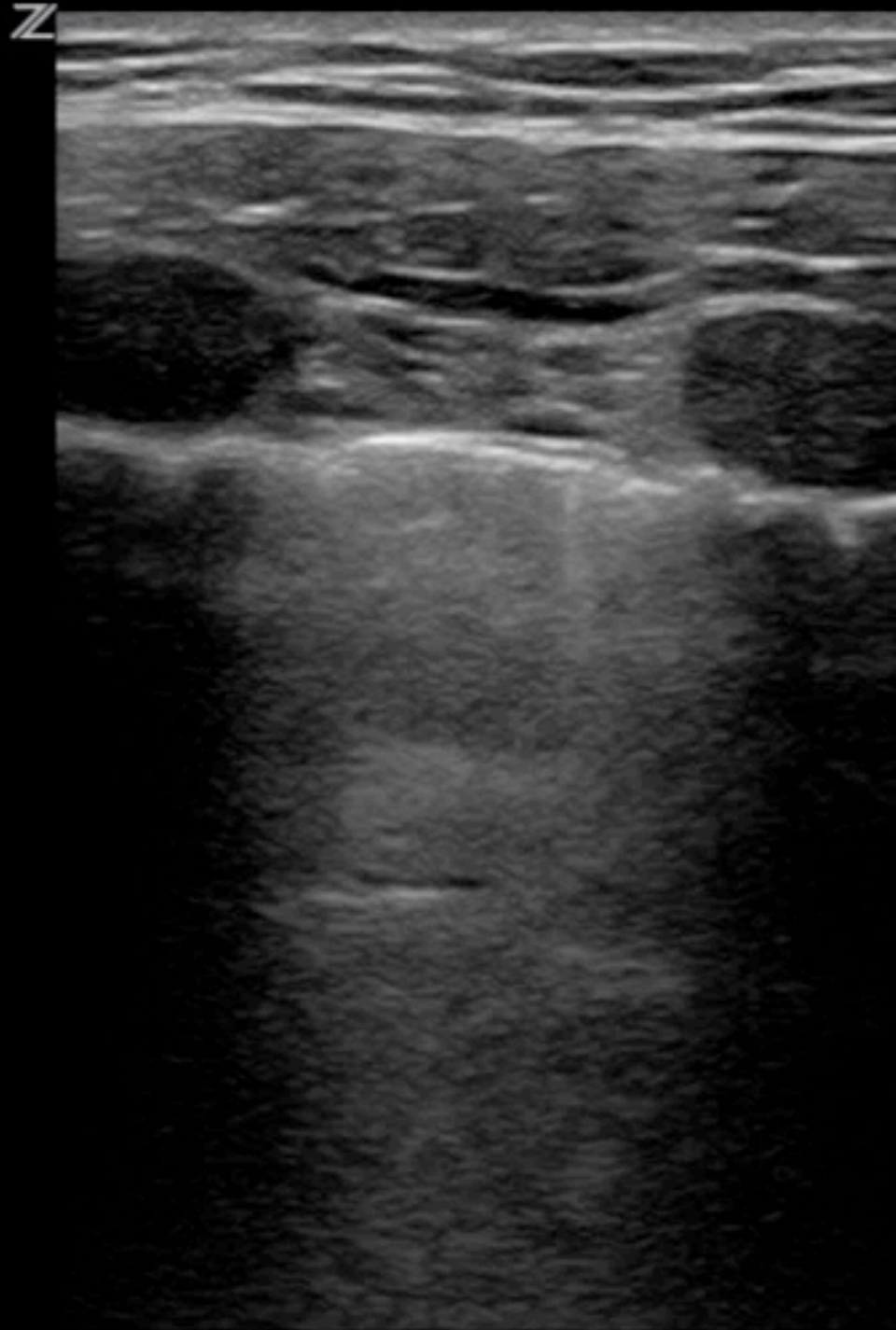
Rib





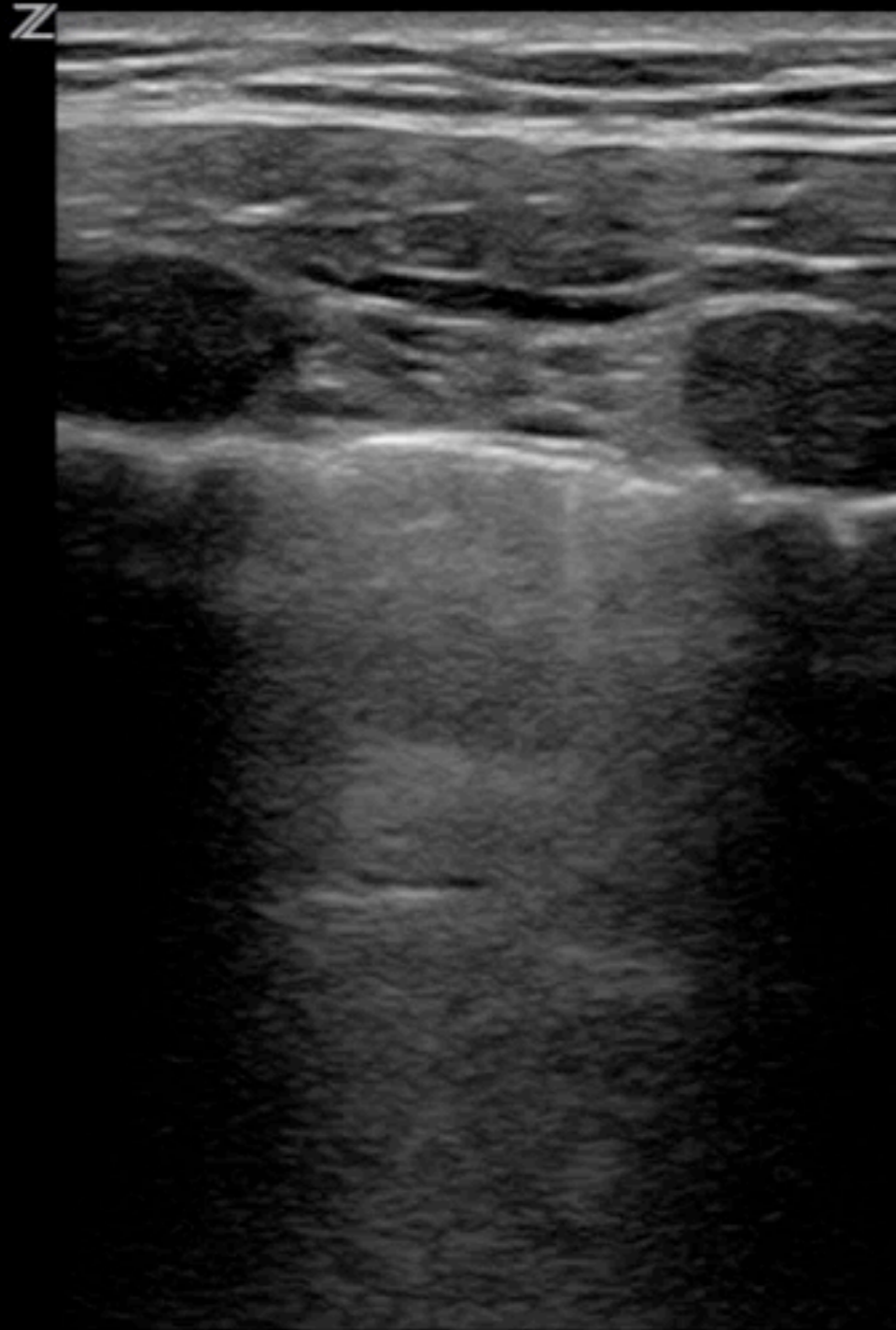


Lung sliding



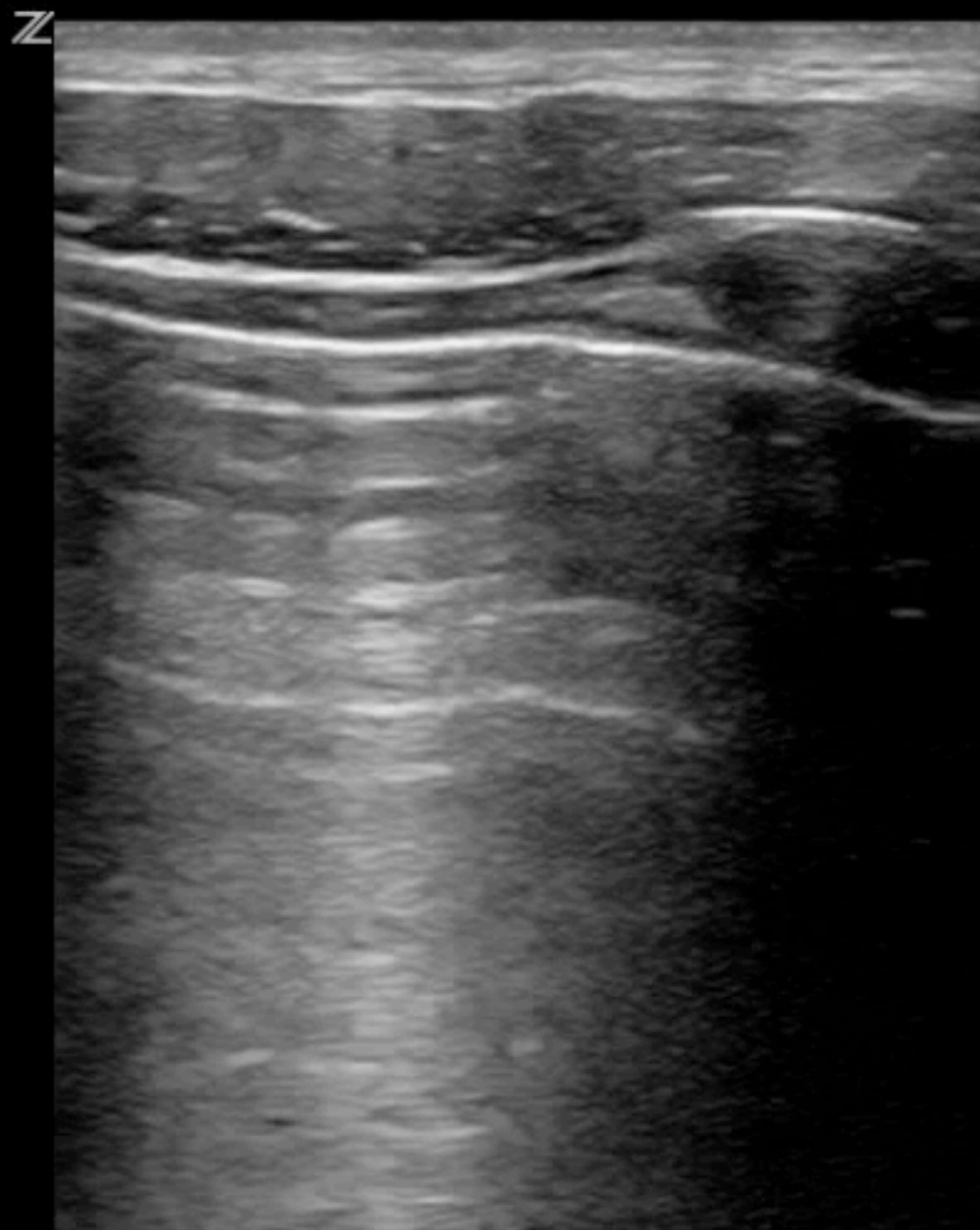
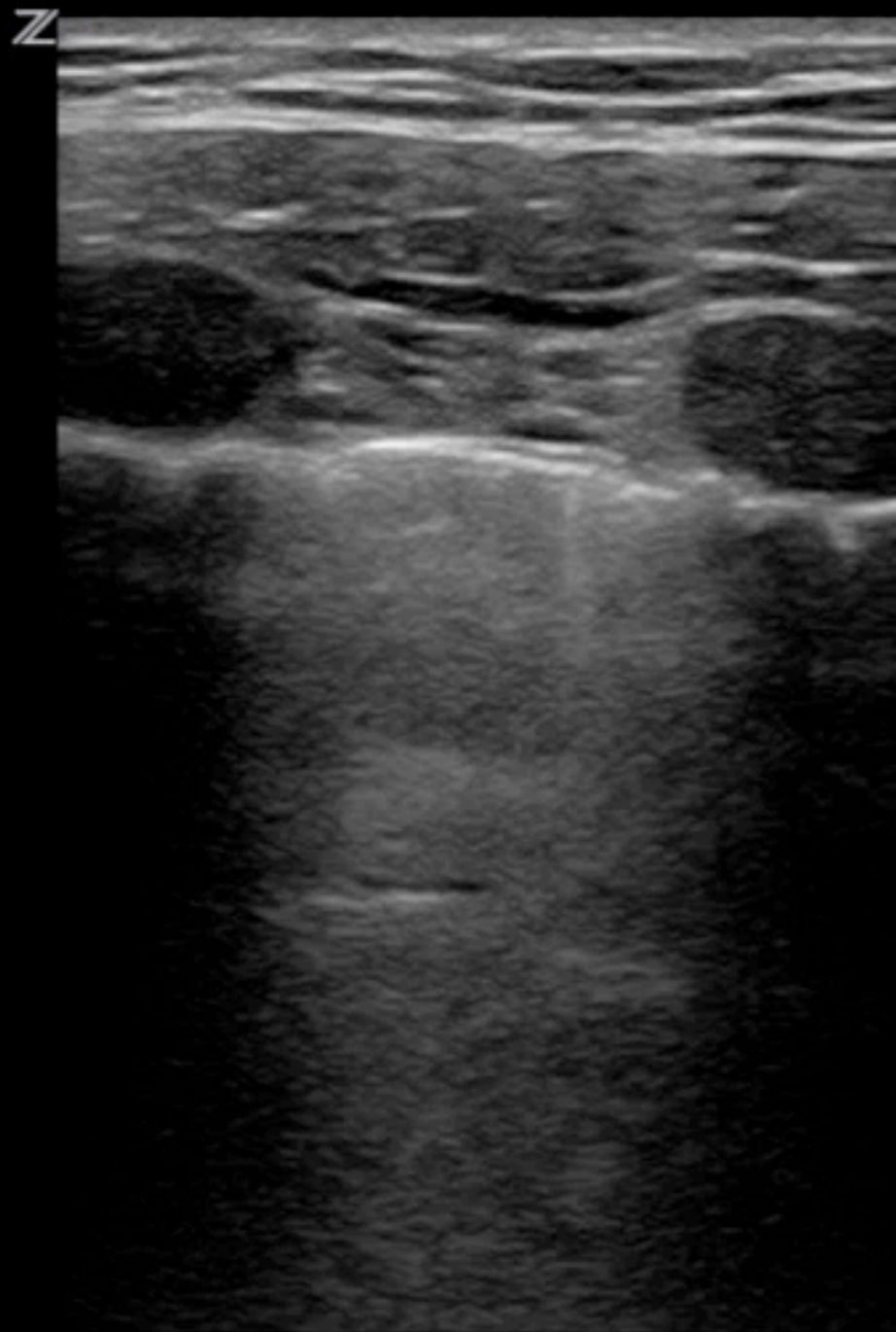
— Abd/PTX
L10-5/8.5MHz
· DR70/M3/P2
G92/E2/100%
- MI1.4 TIs0.1
6.0 cm
· 13 Hz
△ ZSI 0

Lung sliding



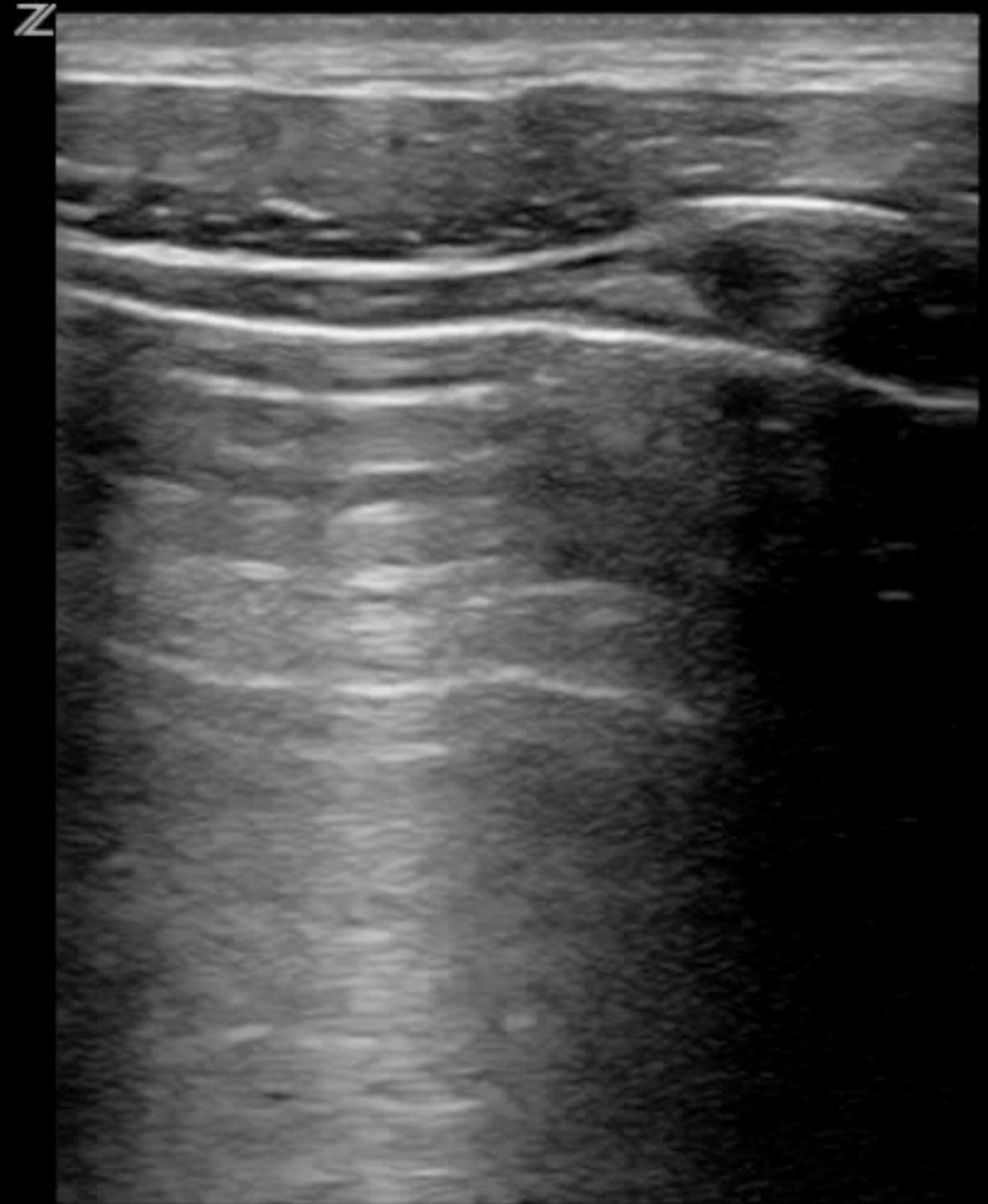— Abd/PTX
L10-5/8.5MHz
· DR70/M3/P2
G92/E2/100%
- MI1.4 TIs0.1
6.0 cm
· 13 Hz
△ ZSI 0

Lung sliding



Pitfall

Sliding rules out
a pneumothorax



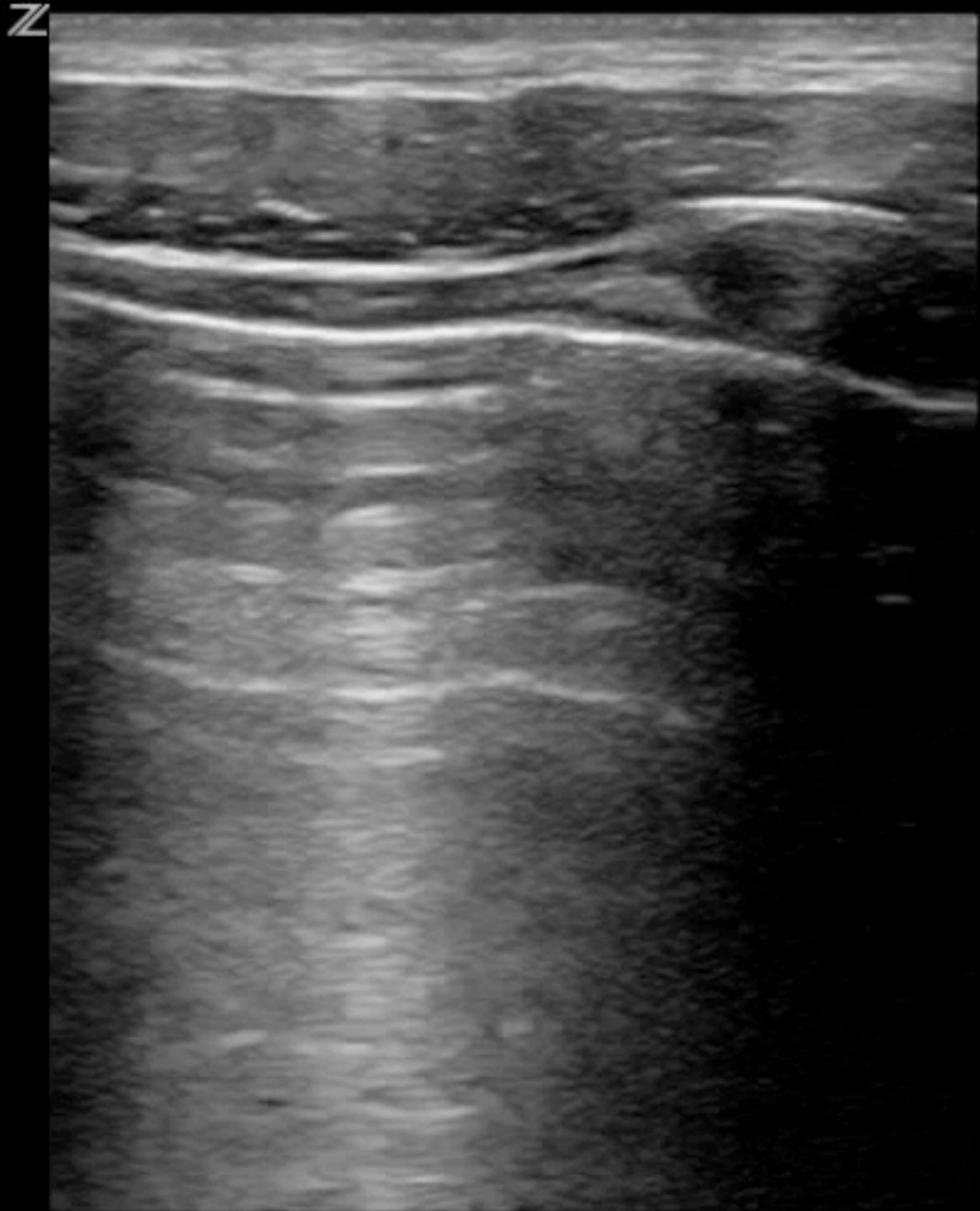Pitfall

Sliding rules out
a pneumothorax

Lack of sliding \neq
pneumothorax



Pitfall



Bullae

Pleurodesis

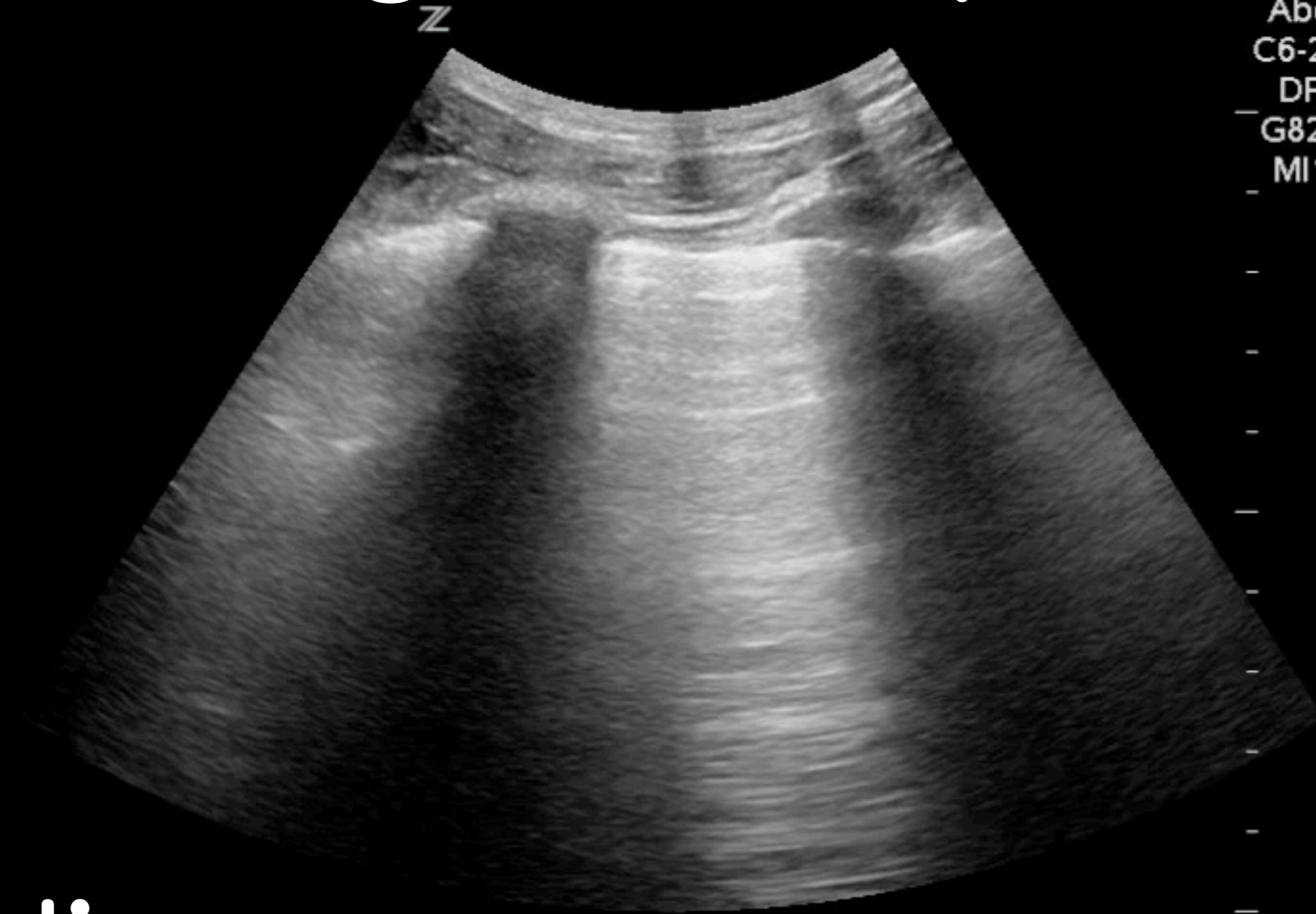Pneumonectomy

R main stem intubation

COPD

Cancer

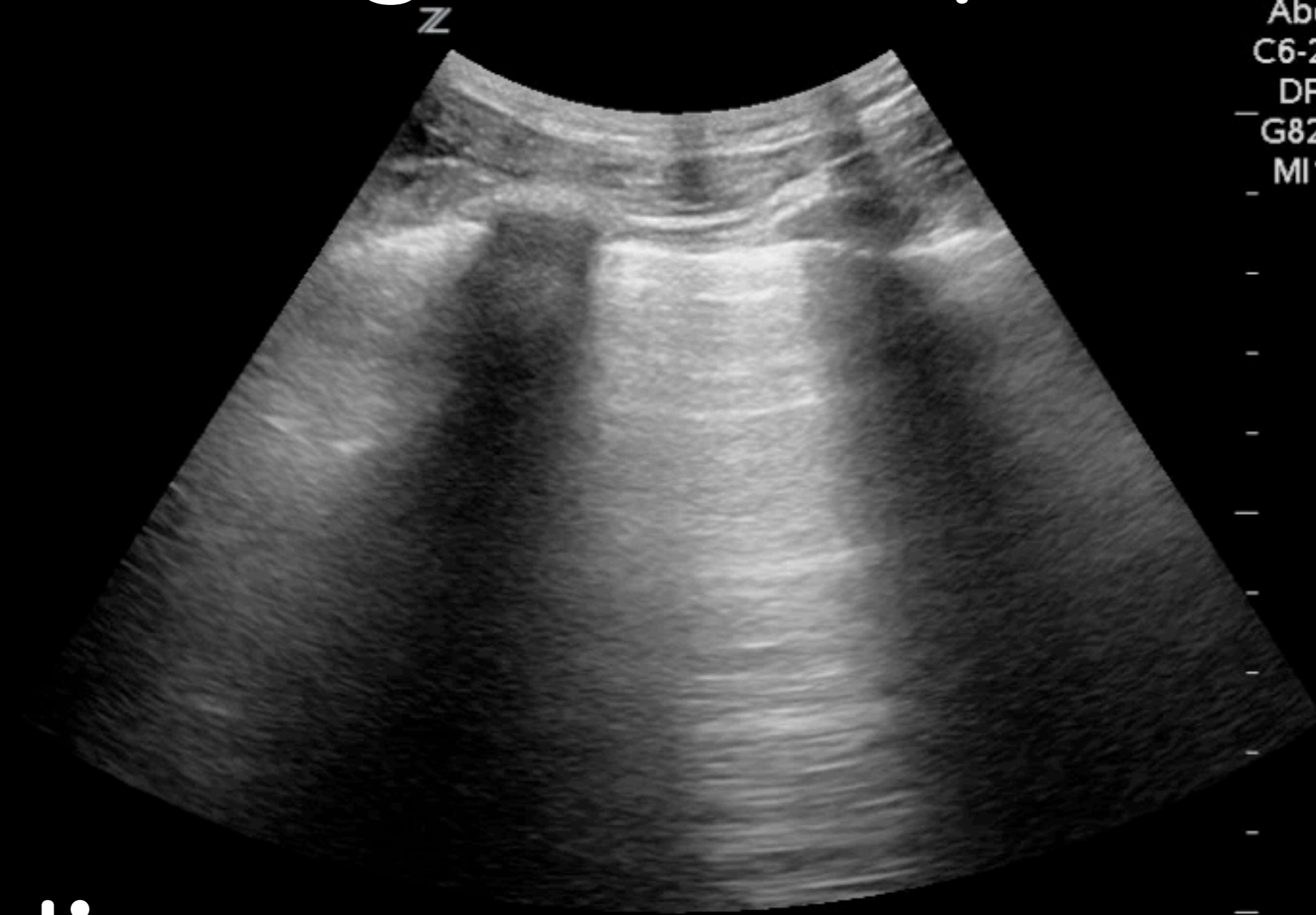Scanning technique



Abd/General
C6-2/CH6MHz
DR50/M2/P2
G82/E1/100%
MI1.4 TIs0.3
10.0 cm
15 Hz
ZSI 0

Sliding

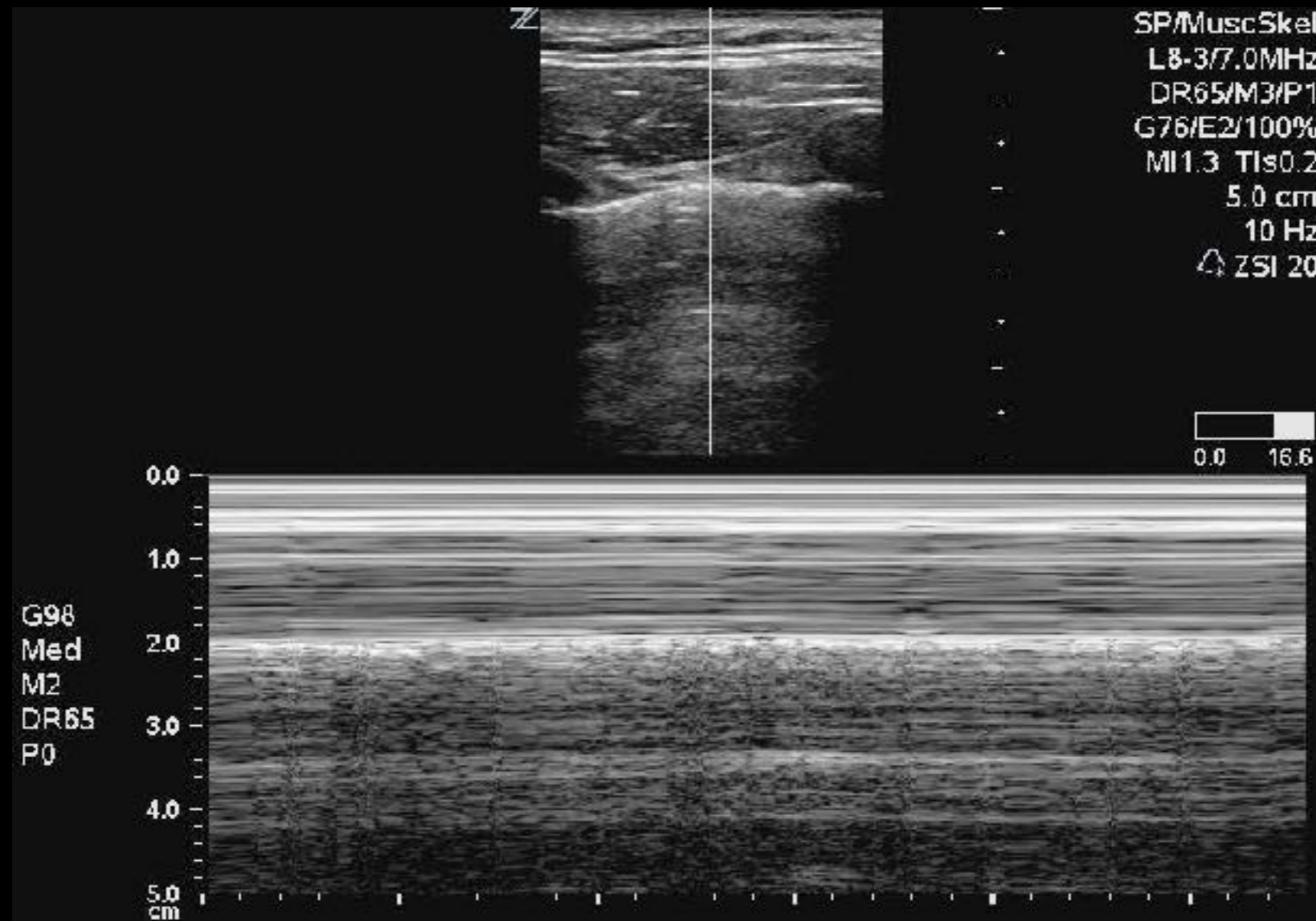
Scanning technique



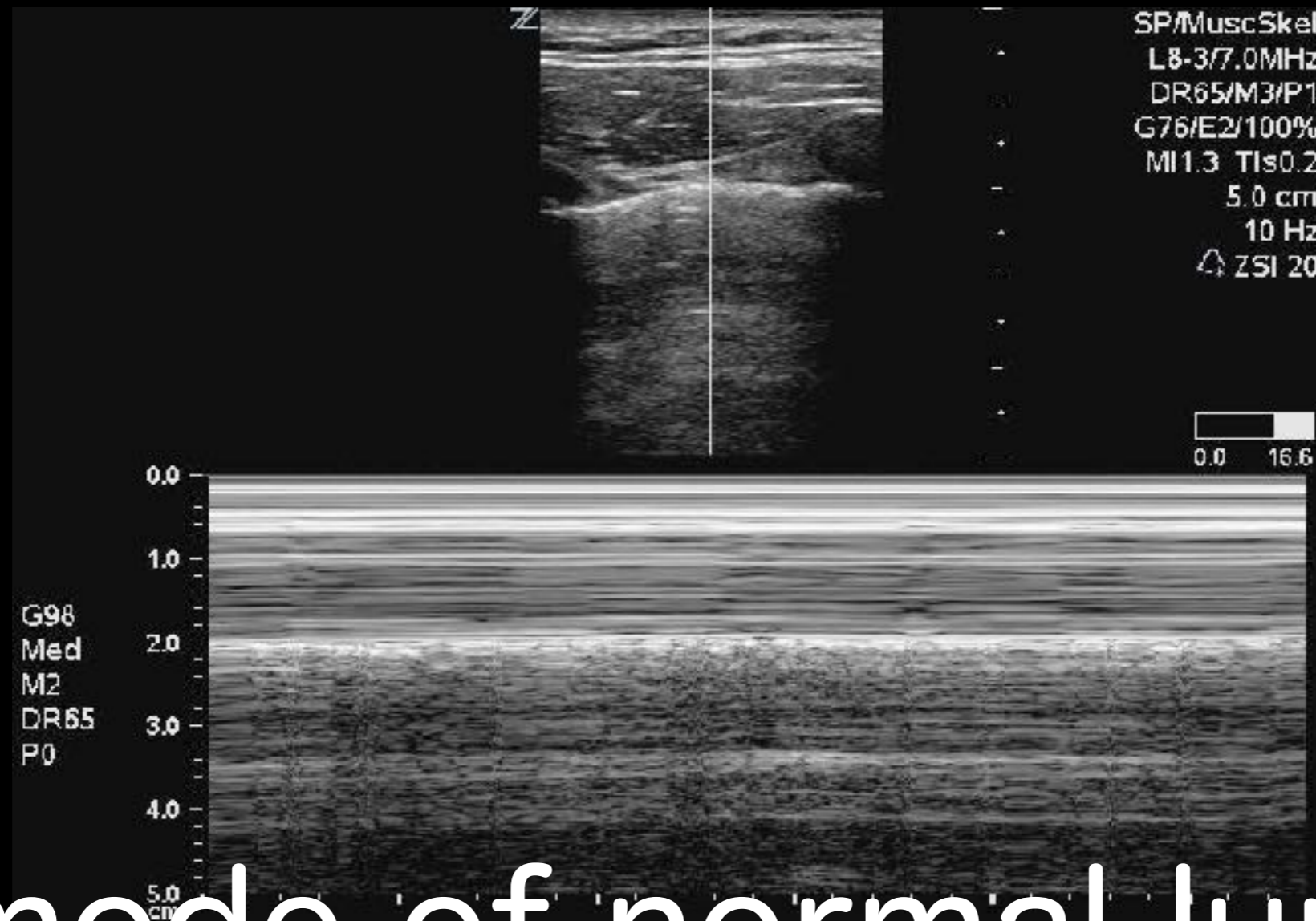
Abd/General
C6-2/CH6MHz
DR50/M2/P2
G82/E1/100%
MI1.4 TIs0.3
10.0 cm
15 Hz
ZSI 0

Sliding
Curvilinear probe

Beyond sliding

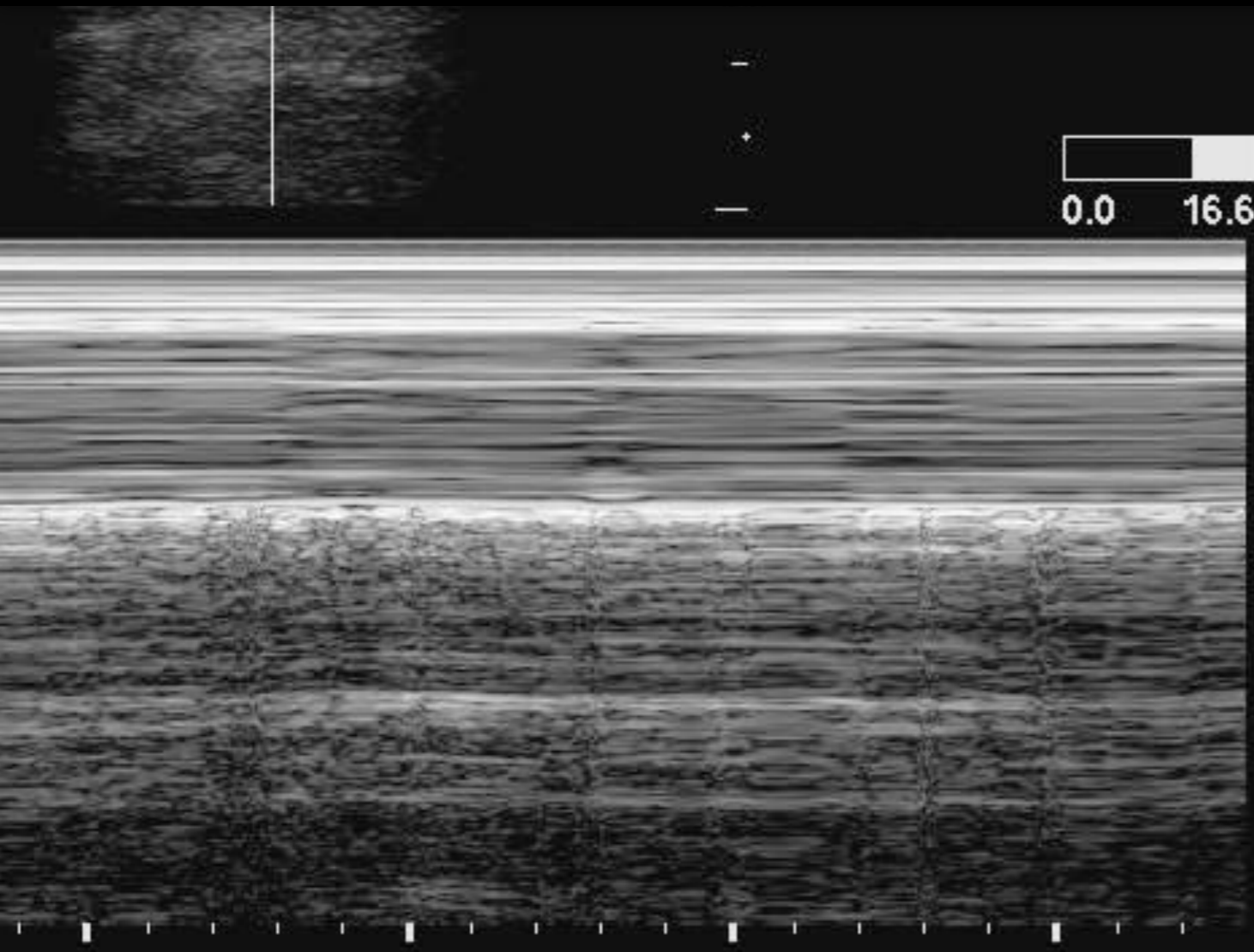


Beyond sliding



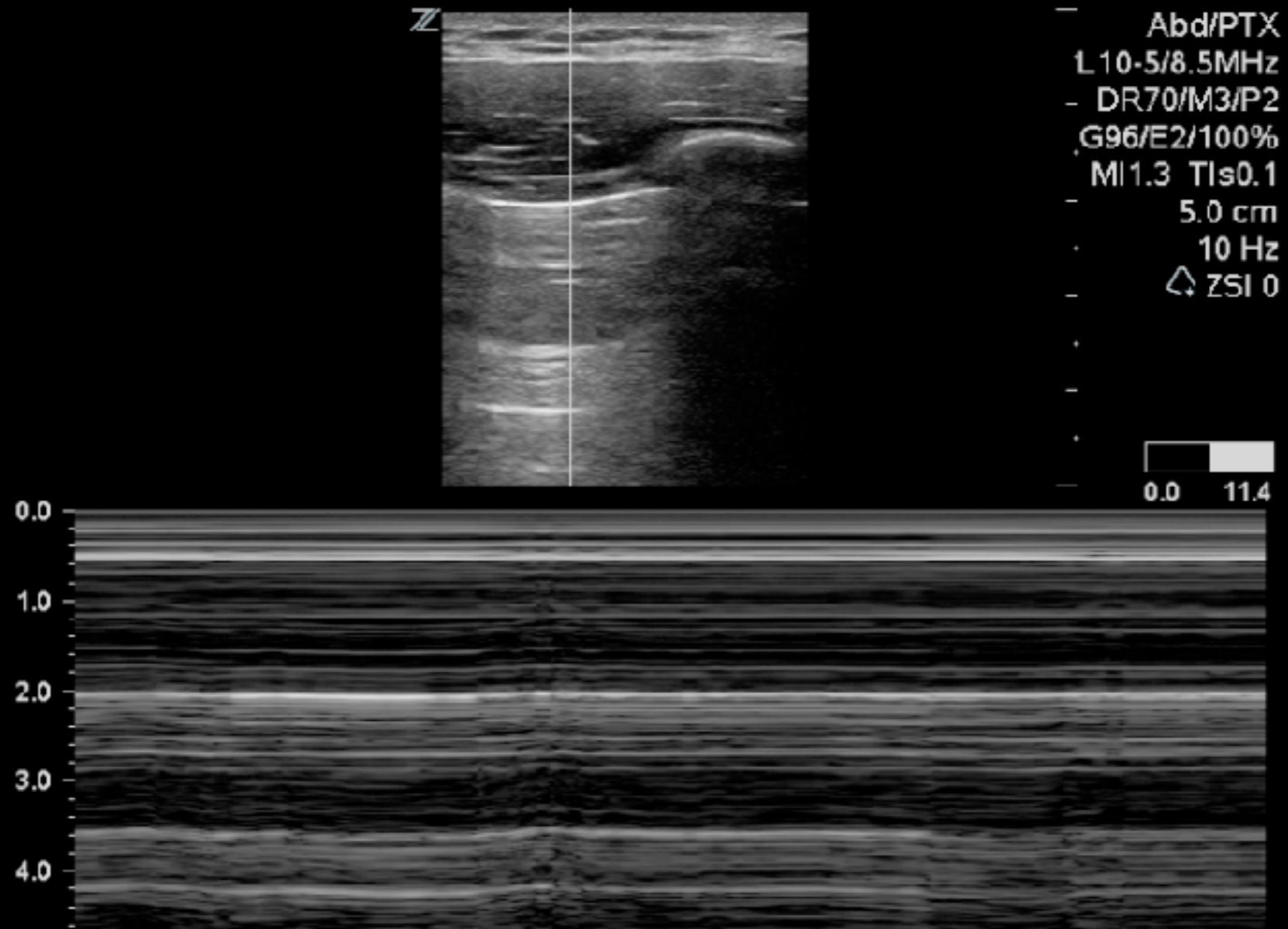
M-mode of normal lung

Beyond sliding



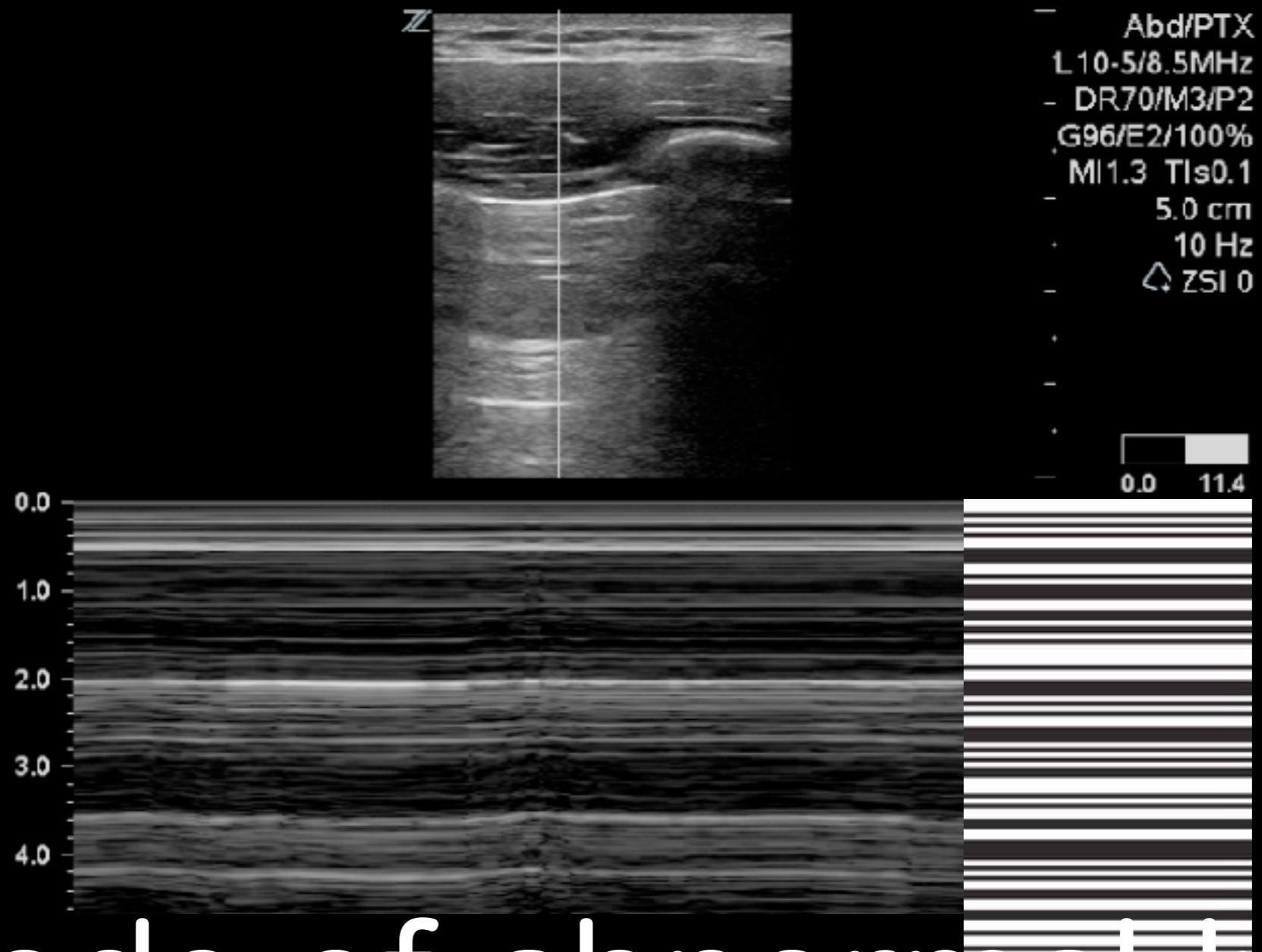
M-mode of normal lung
Seashore sign

Beyond sliding



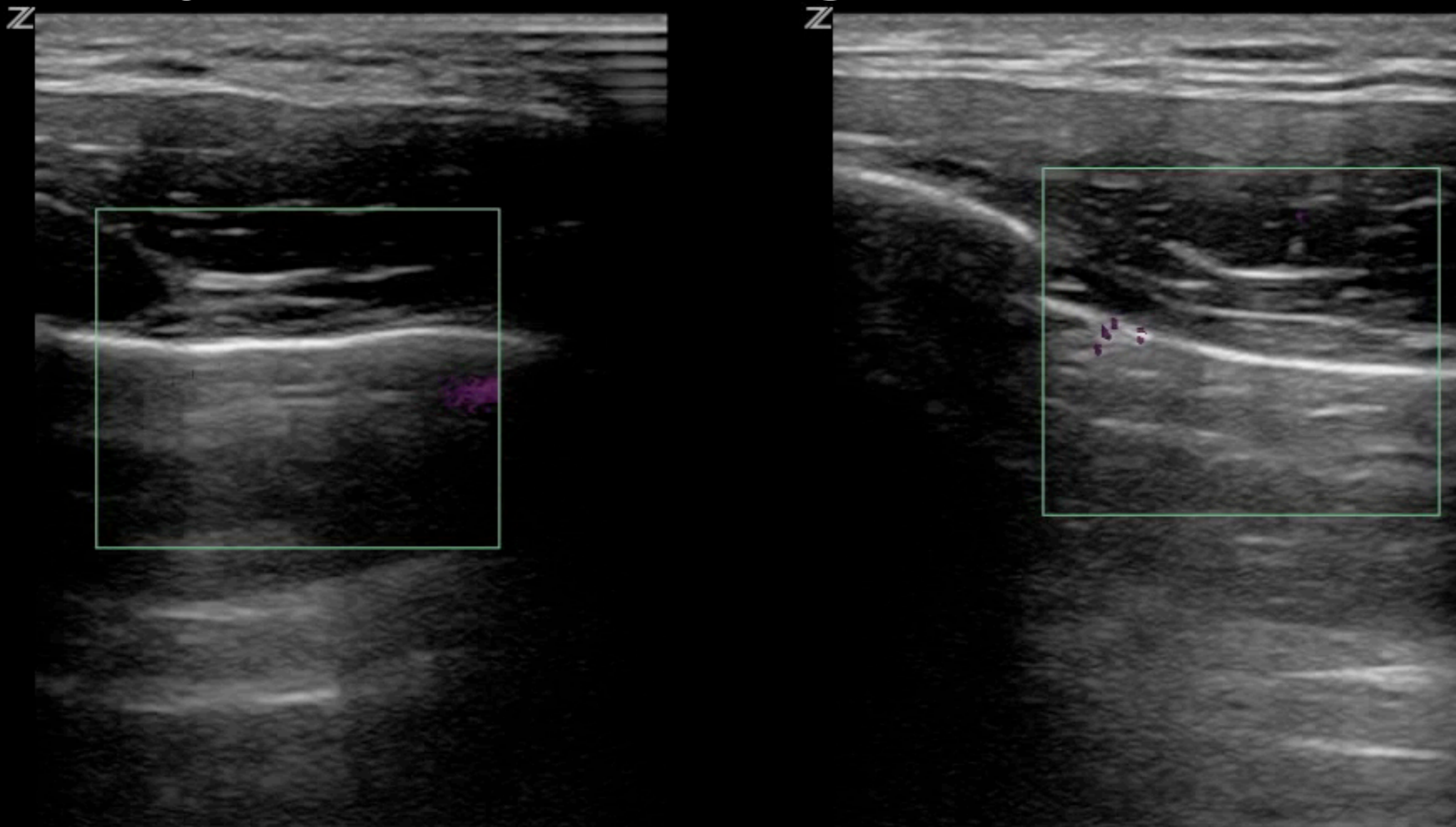
M-mode of abnormal lung

Beyond sliding

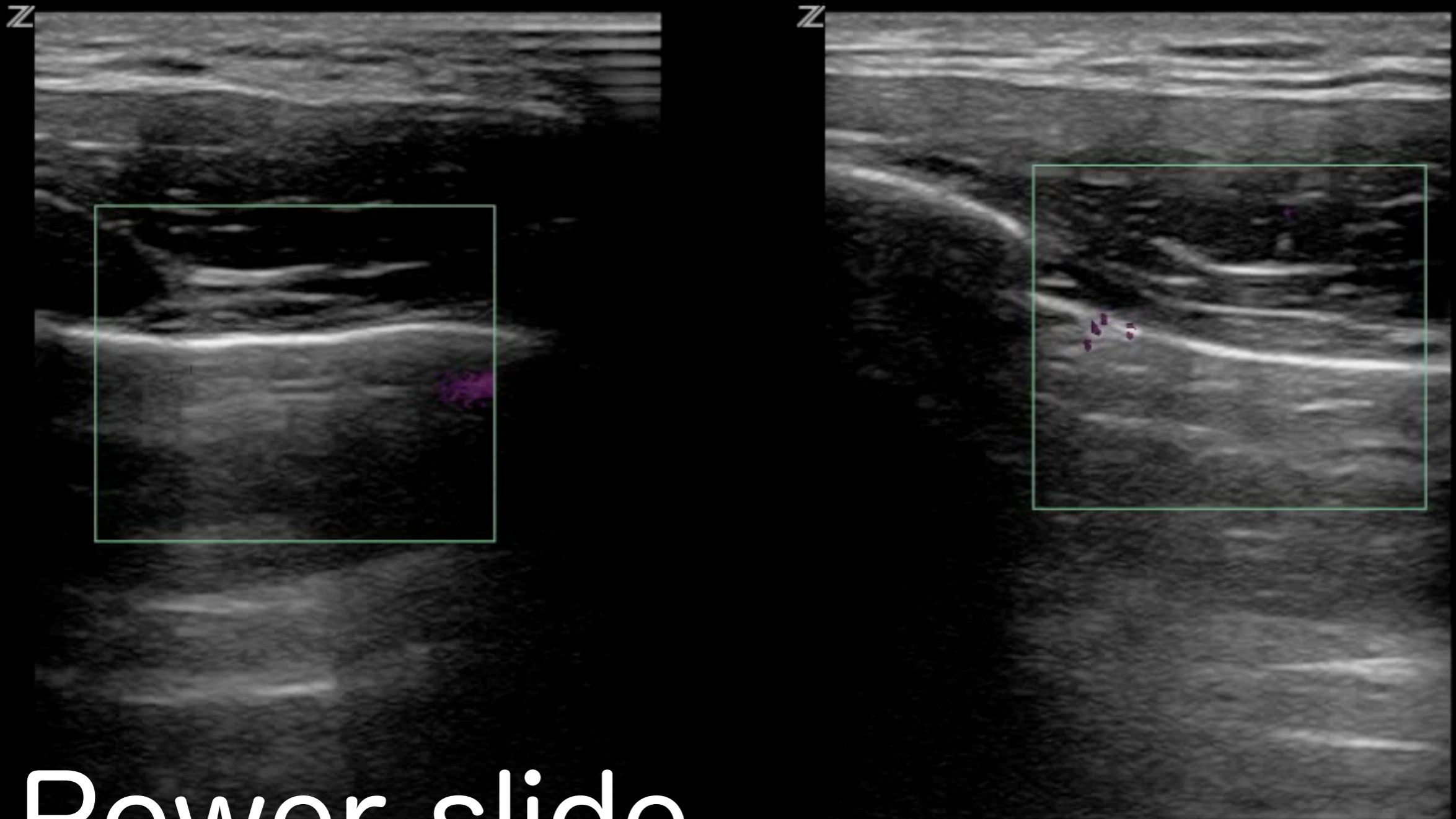


M-mode of abnormal lung
Stratosphere or Barcode sign

Beyond sliding



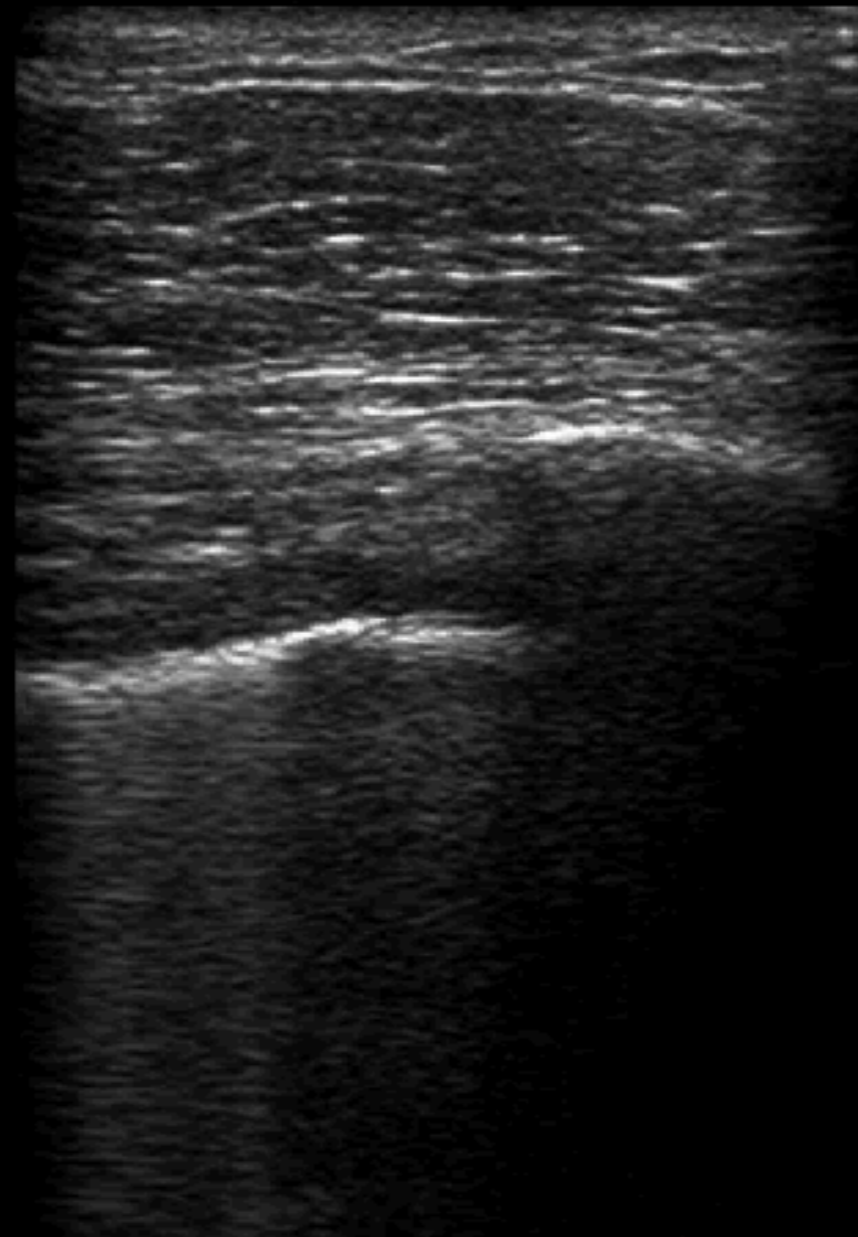
Beyond sliding



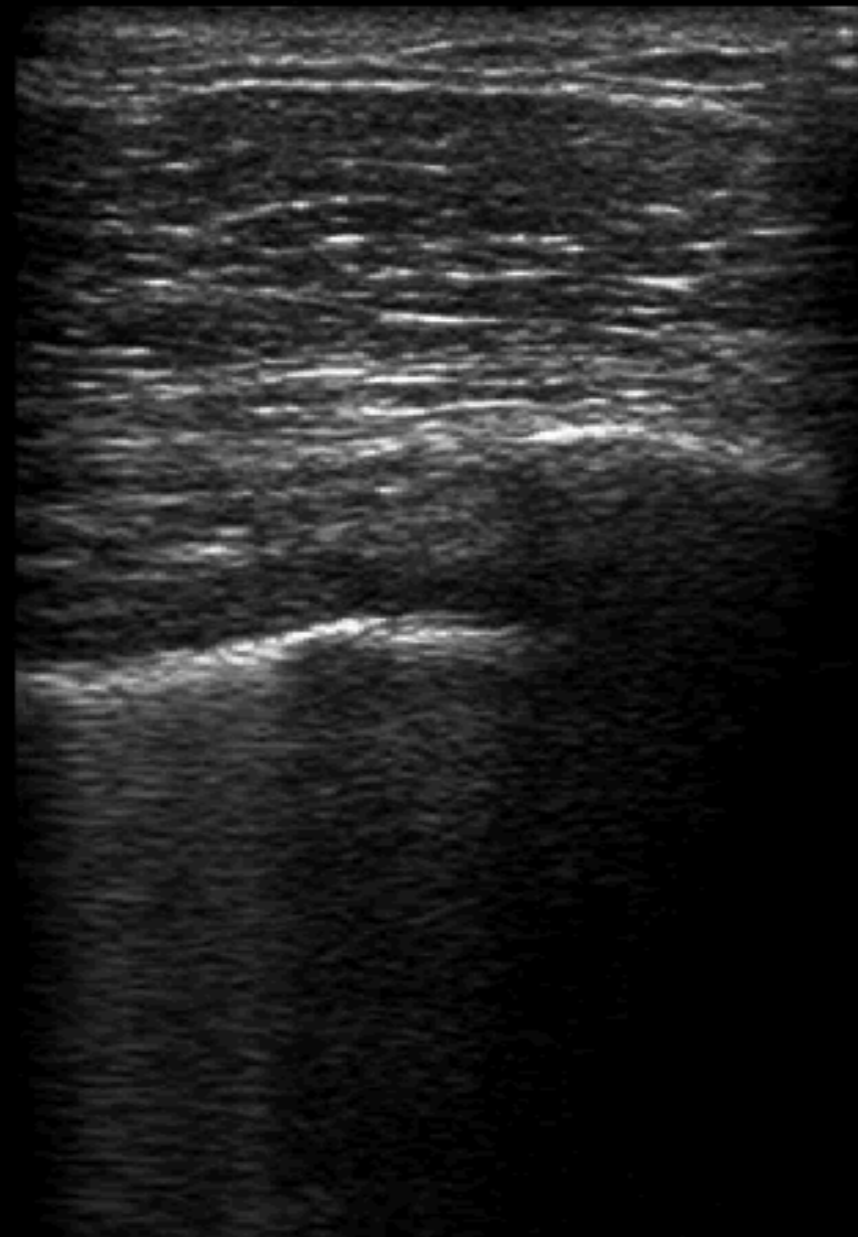
Power slide

Cautions with adjusting gain, probe movement

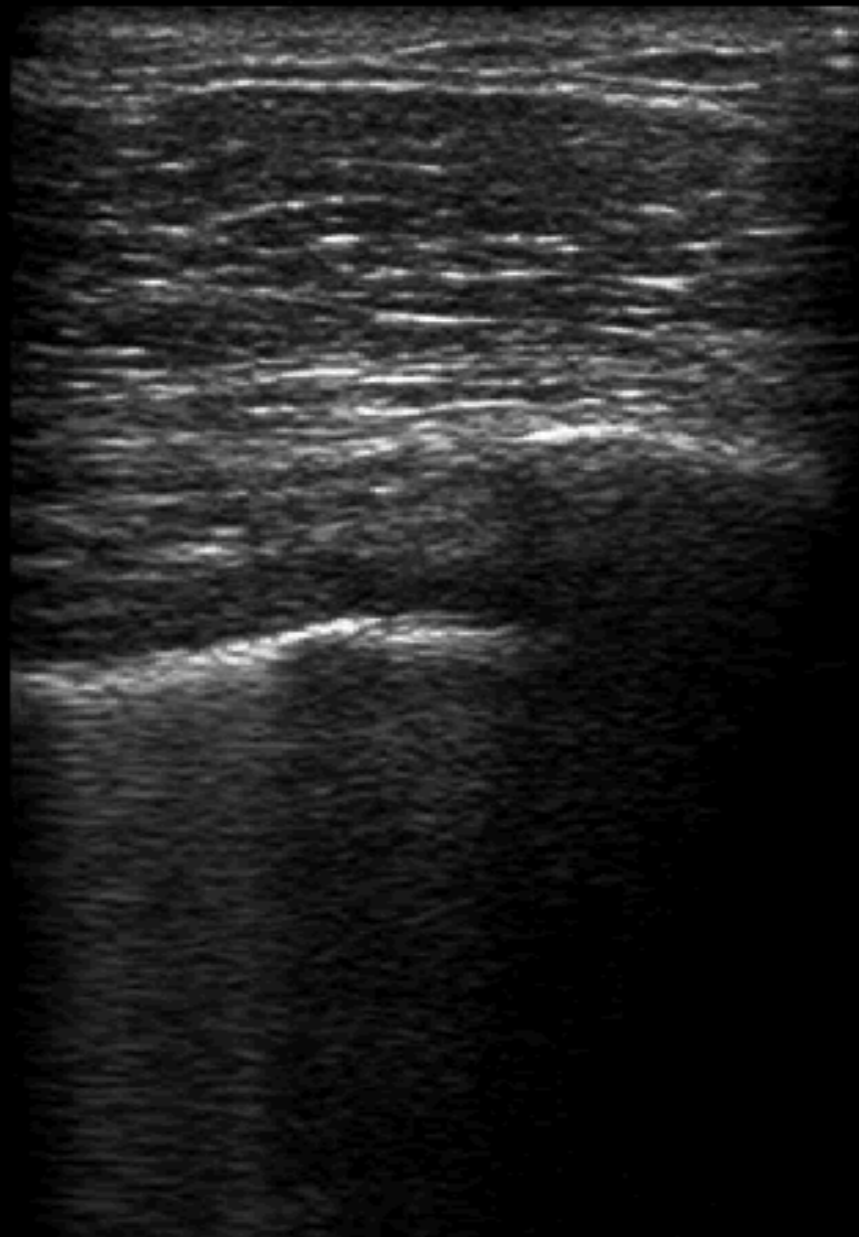
HD



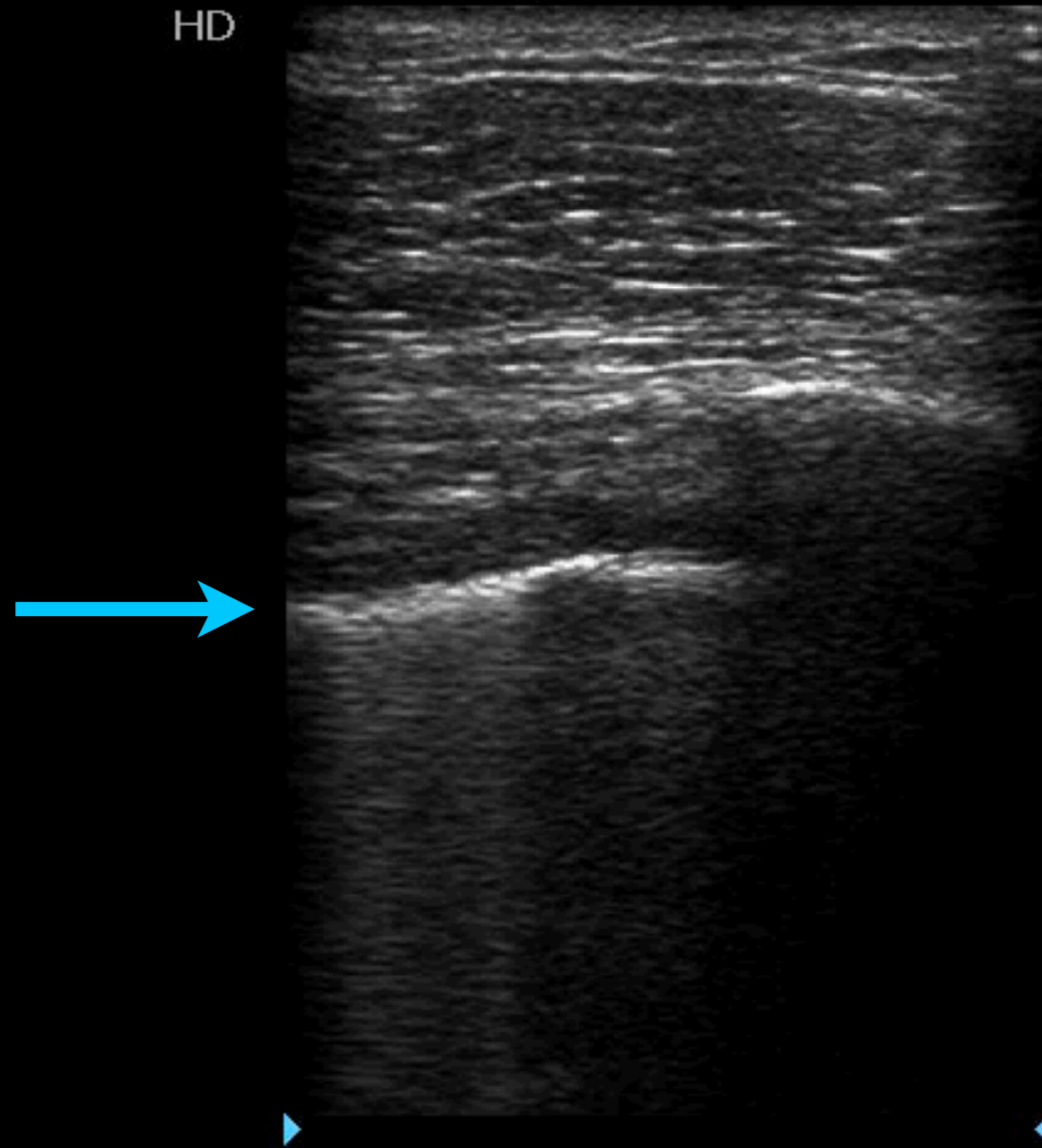
HD



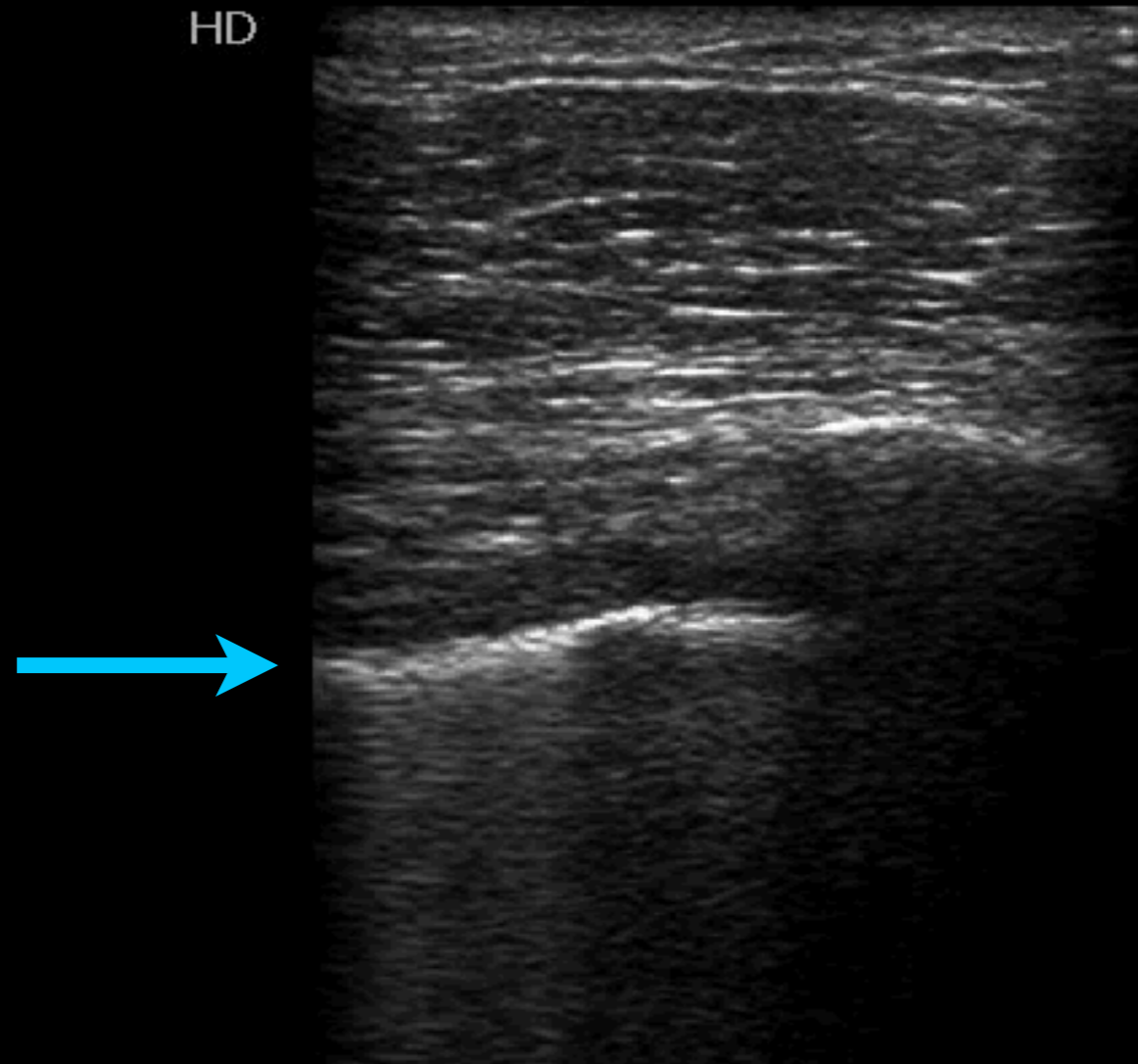
HD



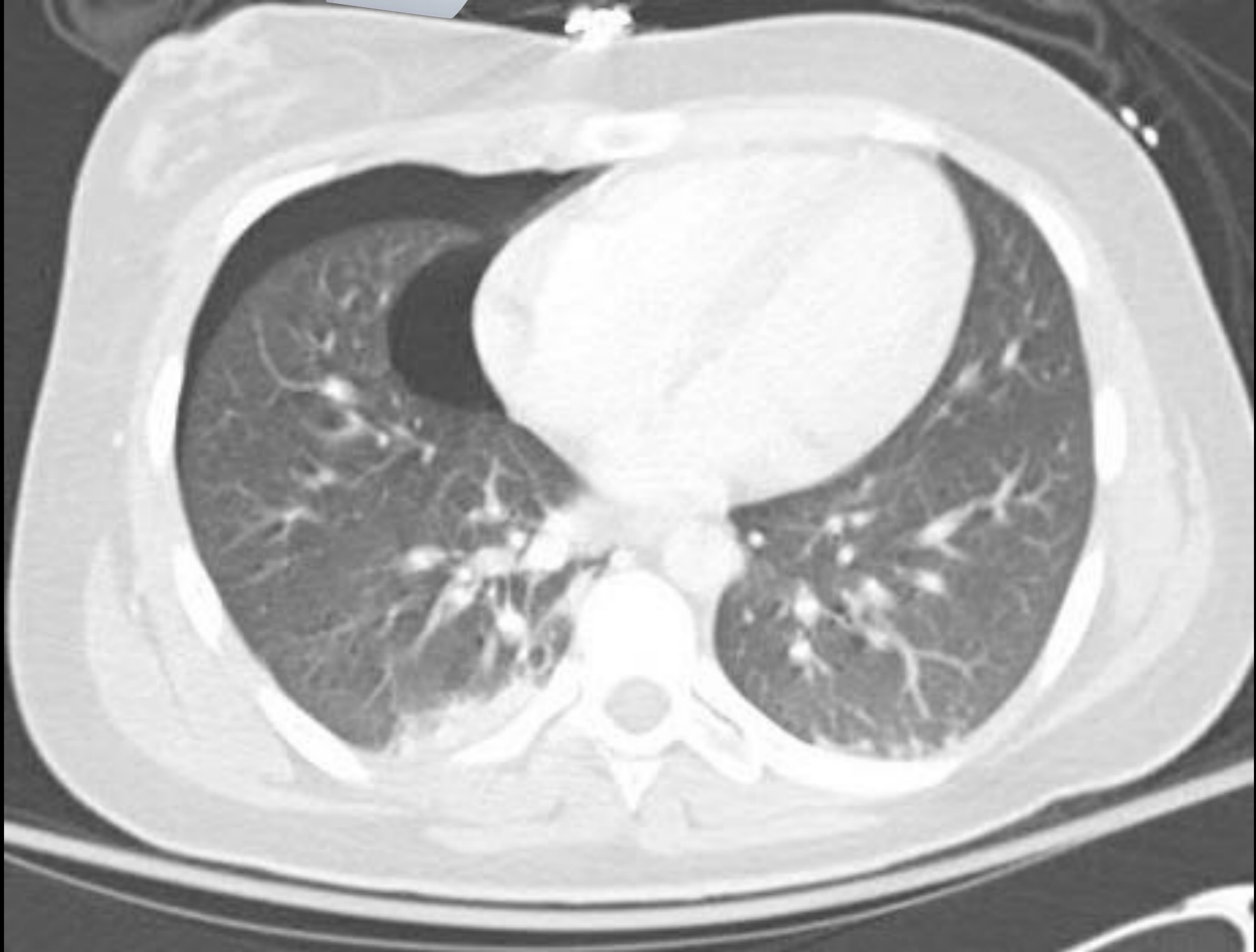Lung point

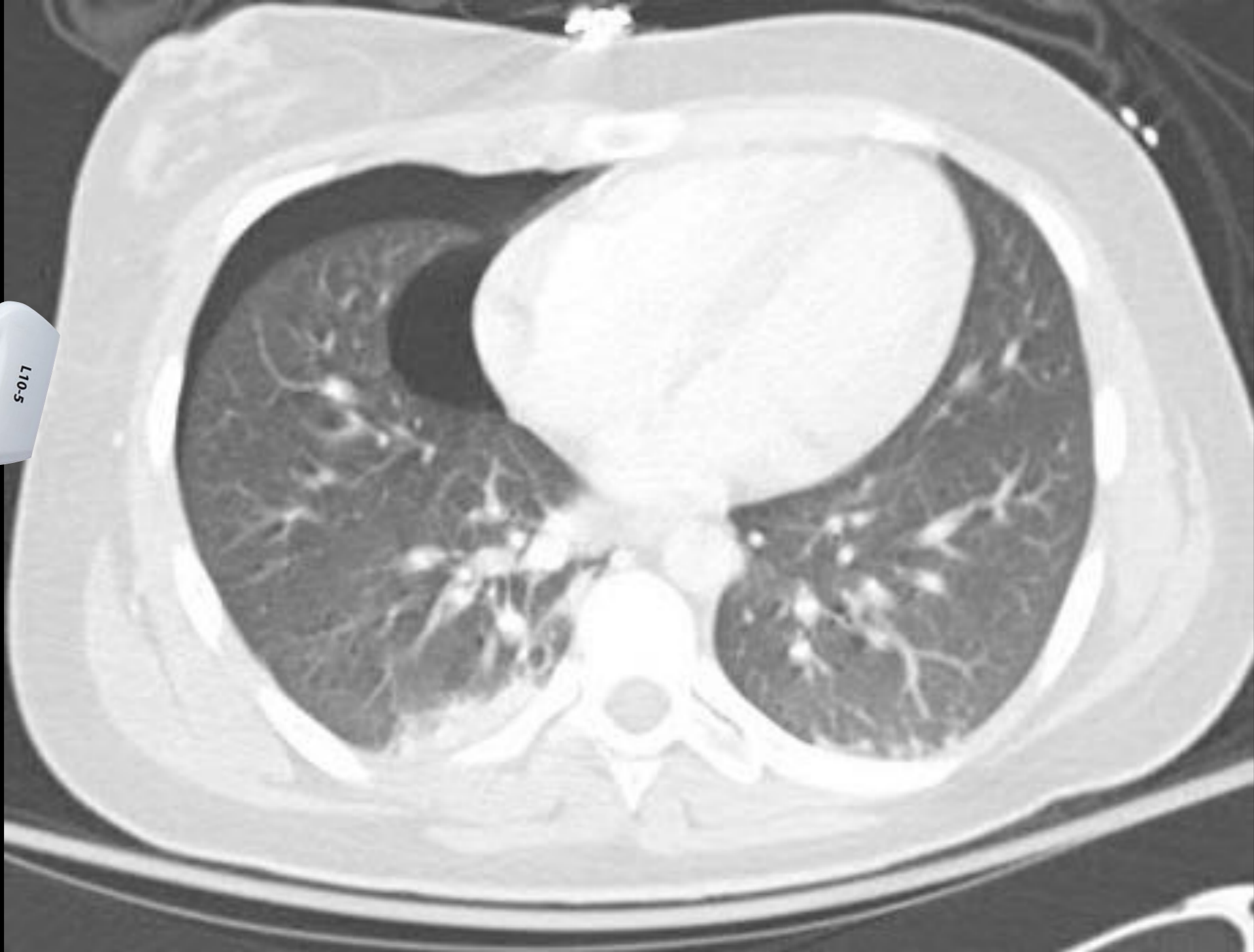

Lung point

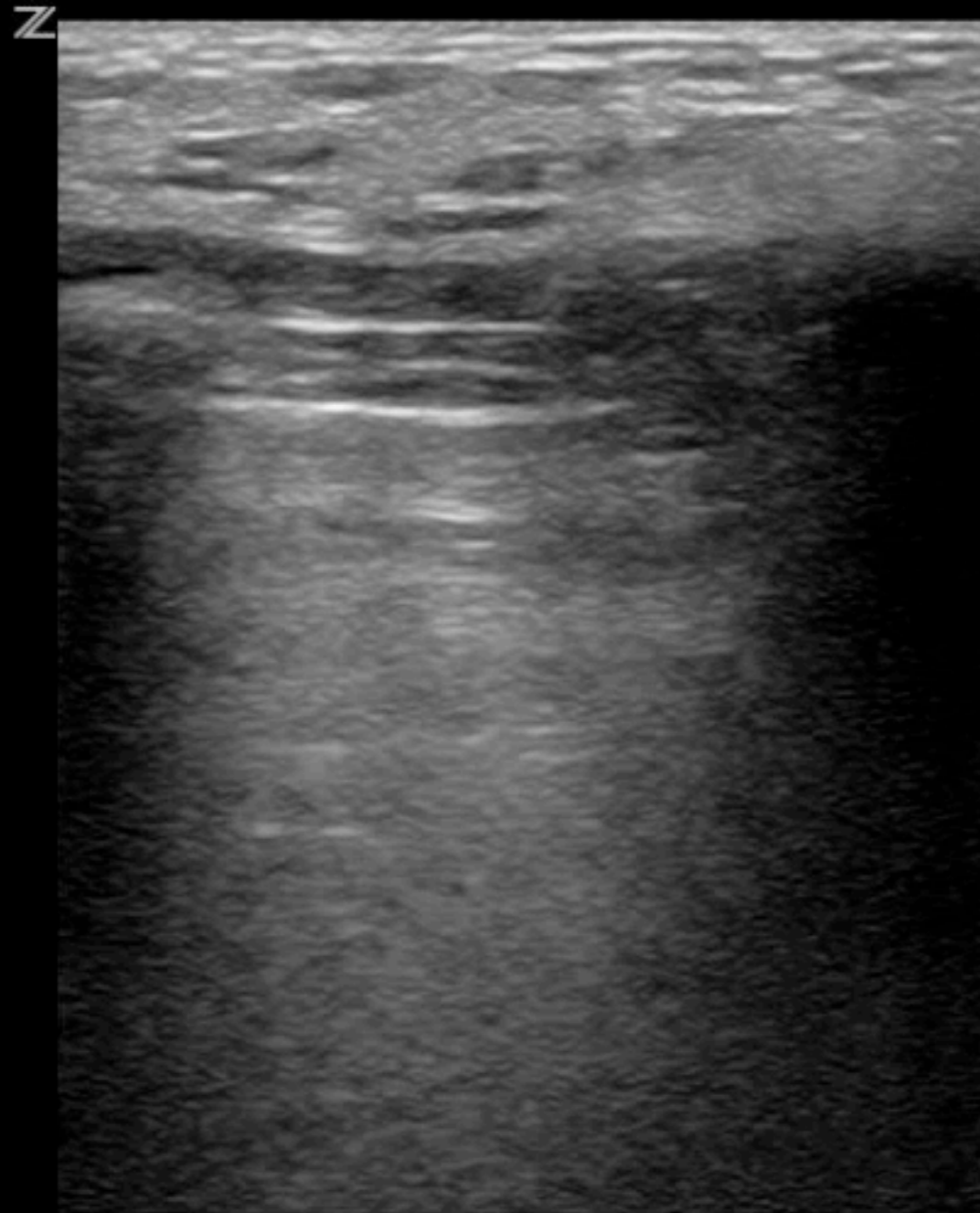


Confirms pneumothorax
Border of pneumothorax

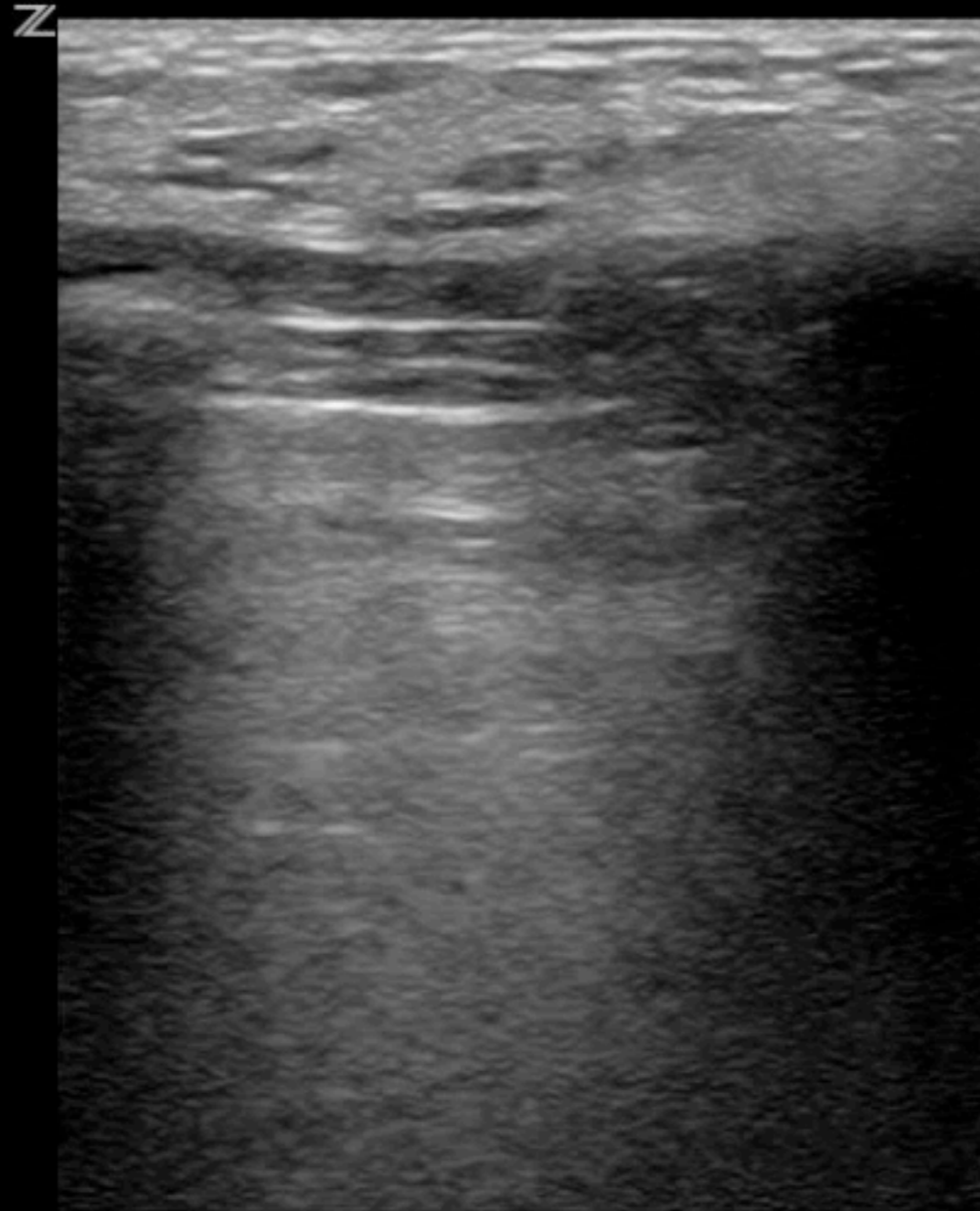



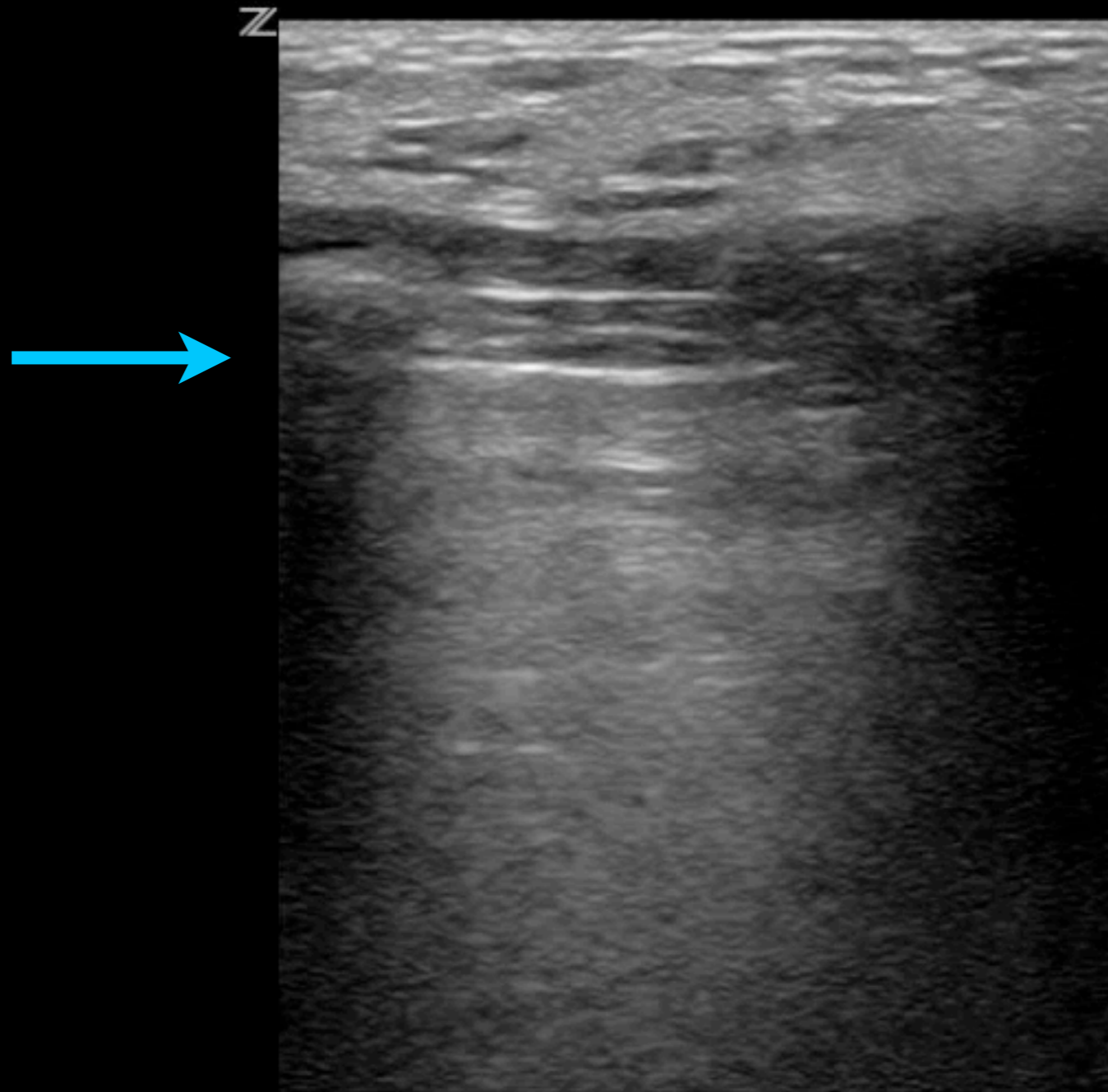
Lung point



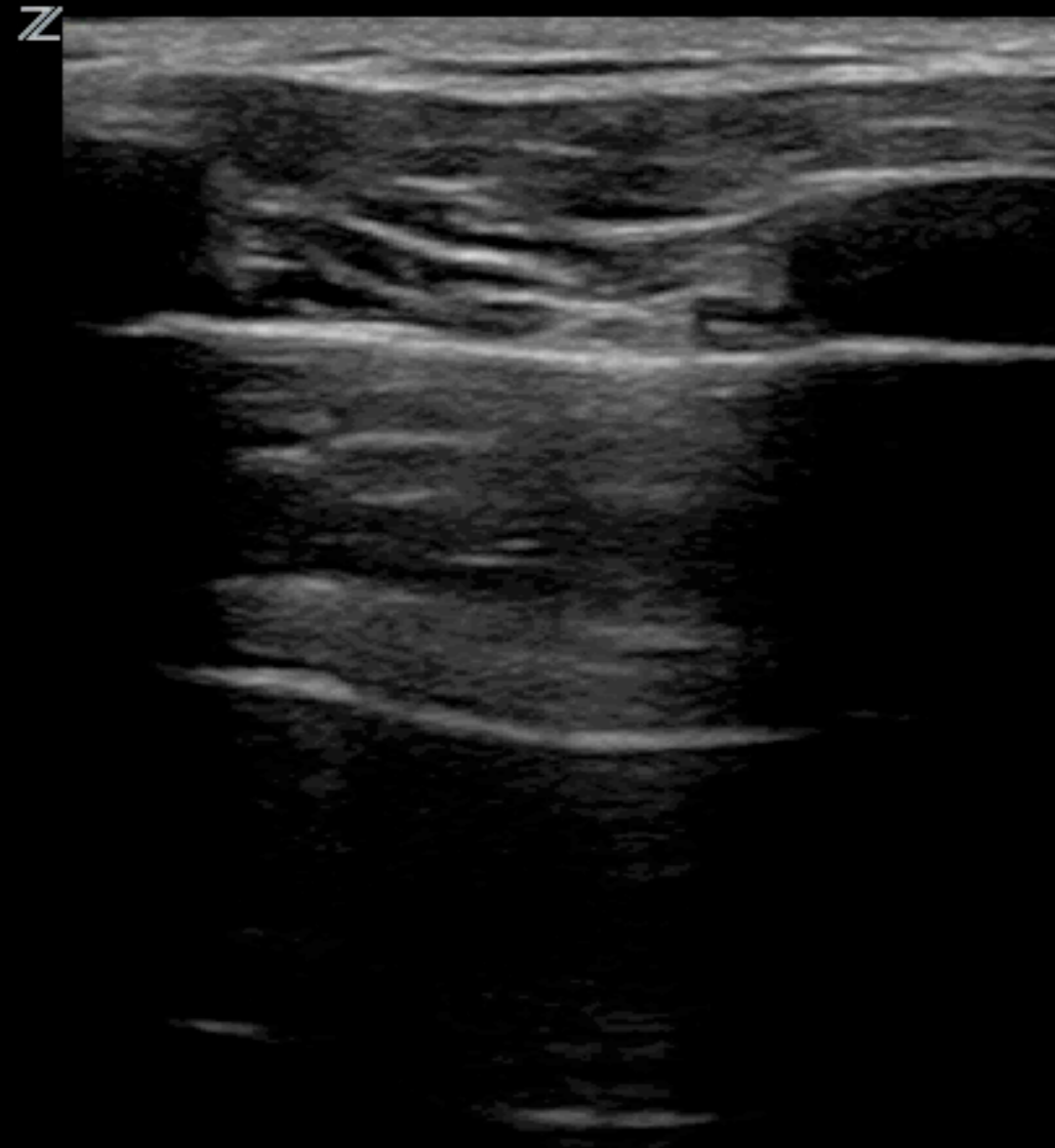
Lung point



Lung point

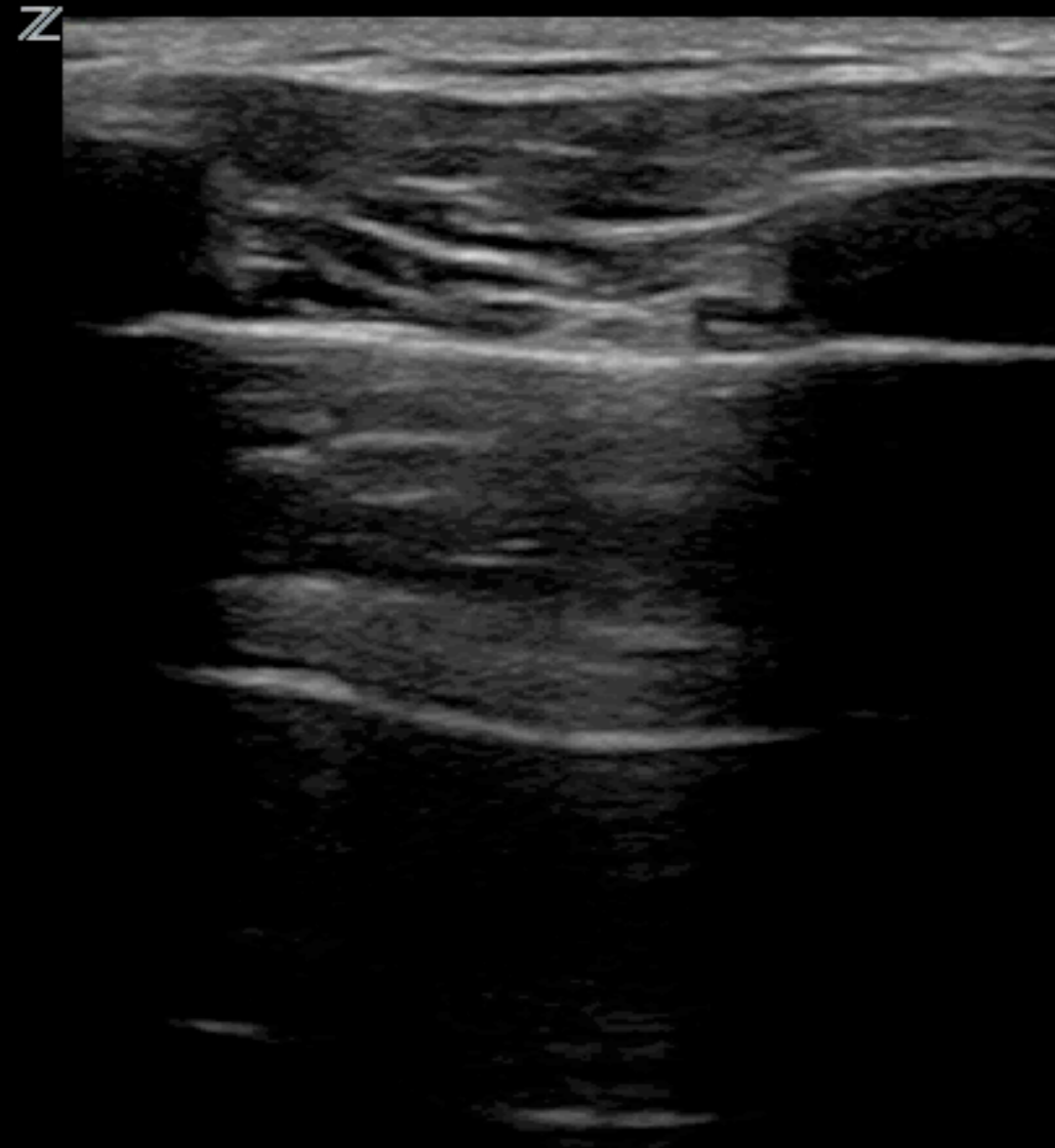


Lung point



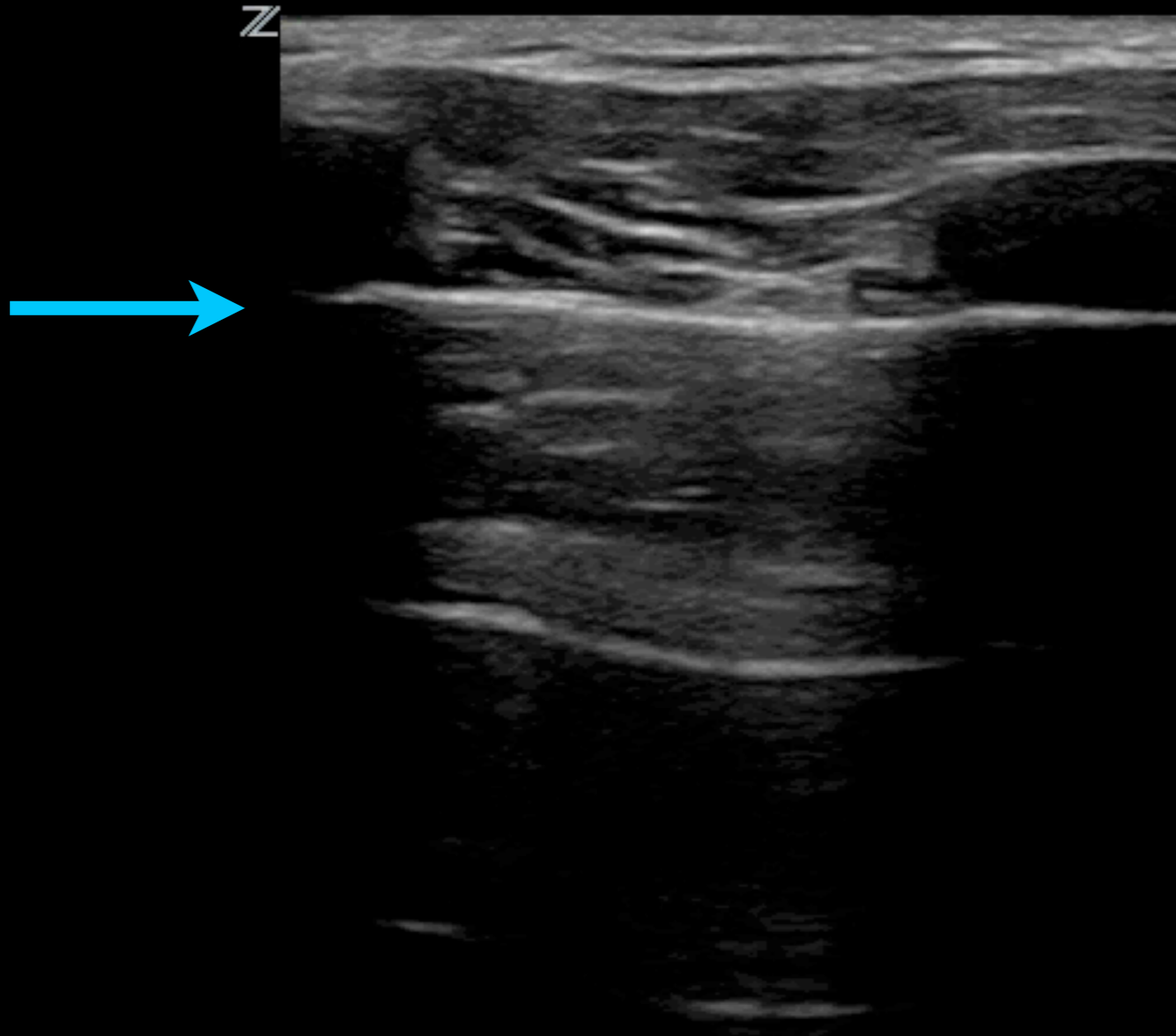
— Abd/General
L10-5/CH8MHz
DR70/M3/P2
G70/E2/100%
MI1.4 TIs0.2
— 5.0 cm
12 Hz
ZSI 0
Image

Lung point



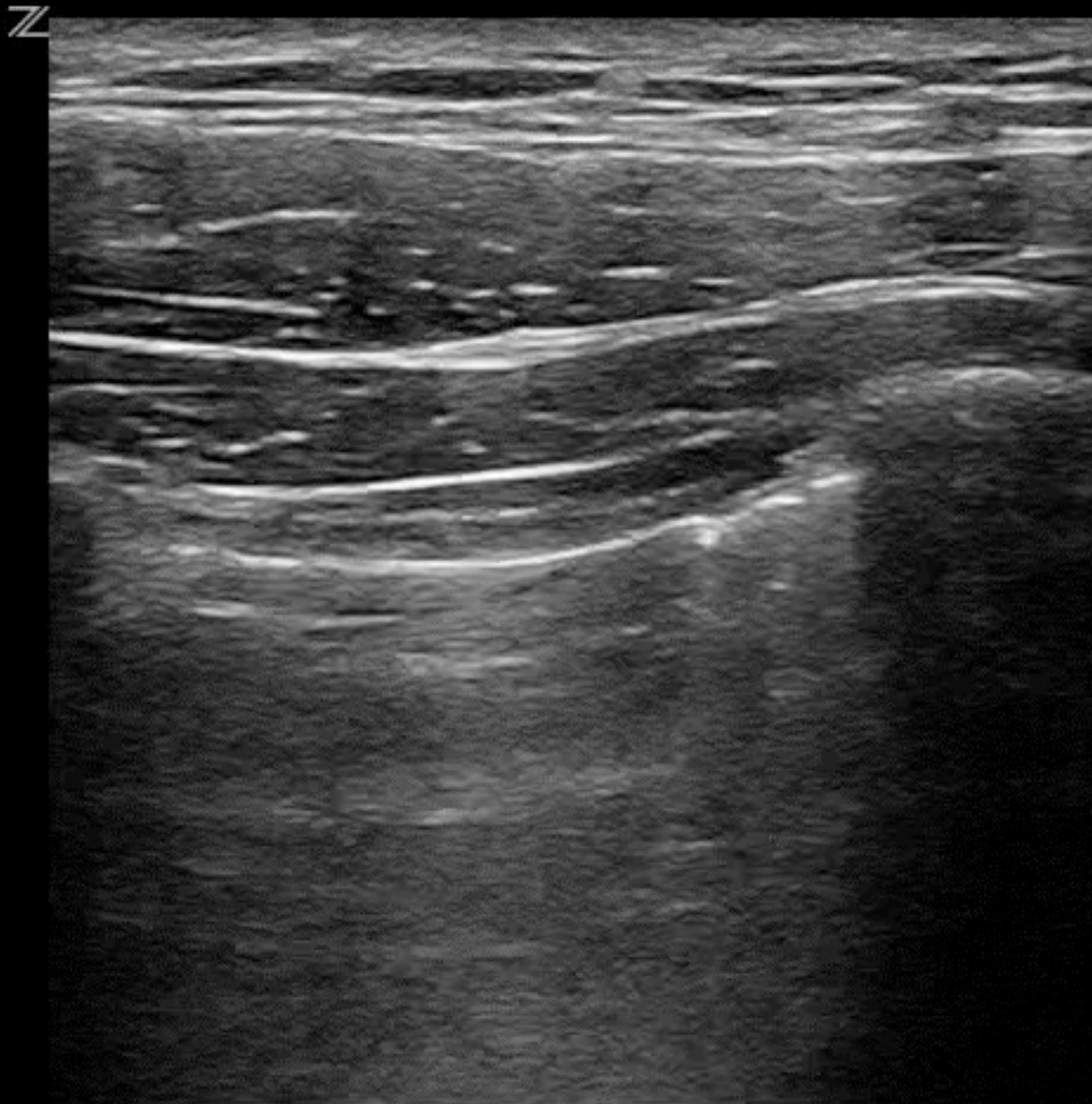
— Abd/General
L10-5/CH8MHz
DR70/M3/P2
G70/E2/100%
MI1.4 TIs0.2
— 5.0 cm
12 Hz
ZSI 0
Image

Lung point



— Abd/General
L10-5/CH8MHz
DR70/M3/P2
G70/E2/100%
MI1.4 TIs0.2
— 5.0 cm
12 Hz
ZSI 0
Image

Lung point



L10-5/8.5
DR80/M3/P2
G76/E2/75%
MI1.4 TIs0.1
4.0 cm
32/32 Hz
△ ZSI 0
Image

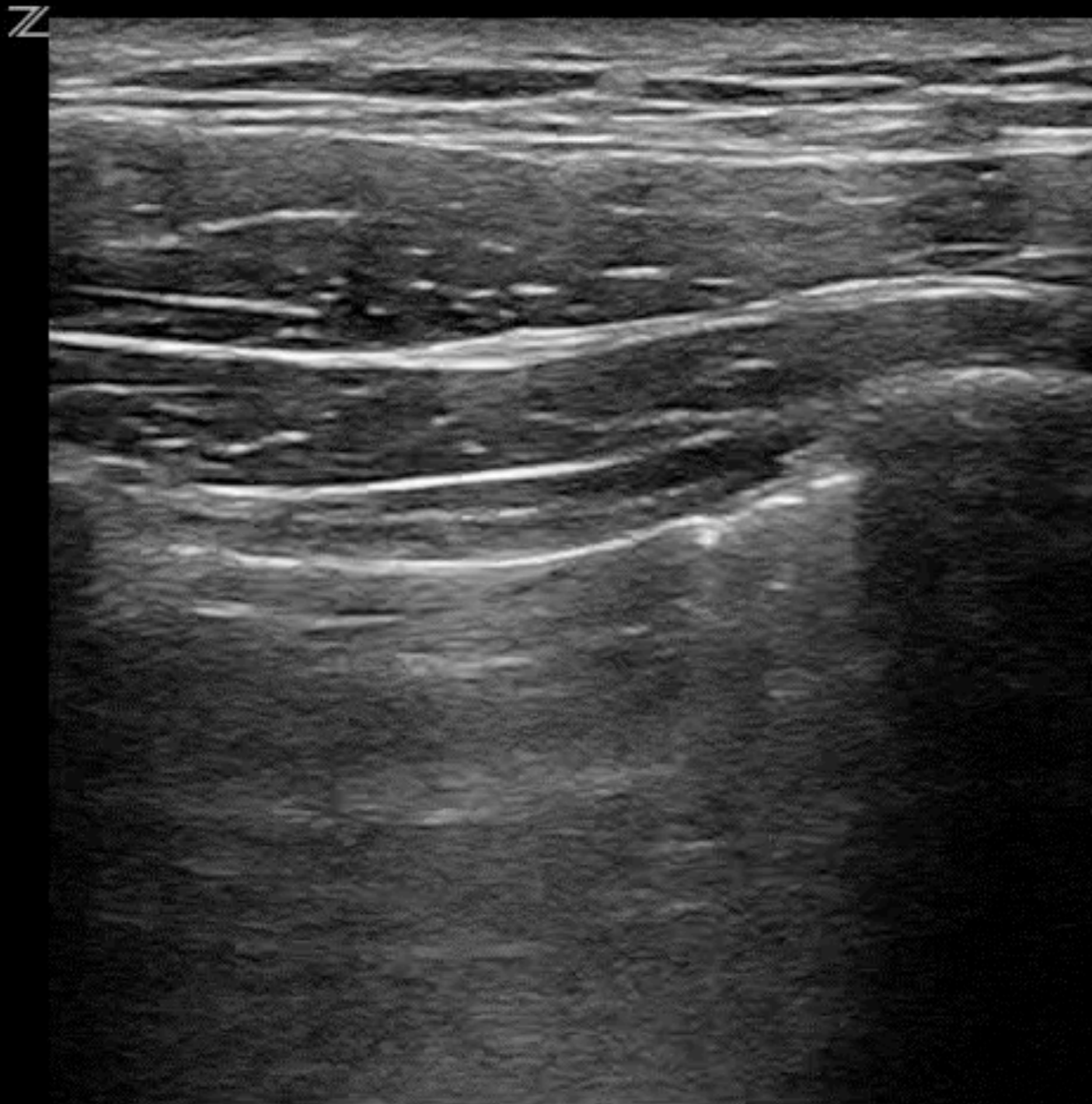
-1

-2

-3

-4
cm

Lung point



L10-5/8.5
DR80/M3/P2
G76/E2/75%
MI1.4 TIs0.1
4.0 cm
32/32 Hz
△ ZSI 0
Image

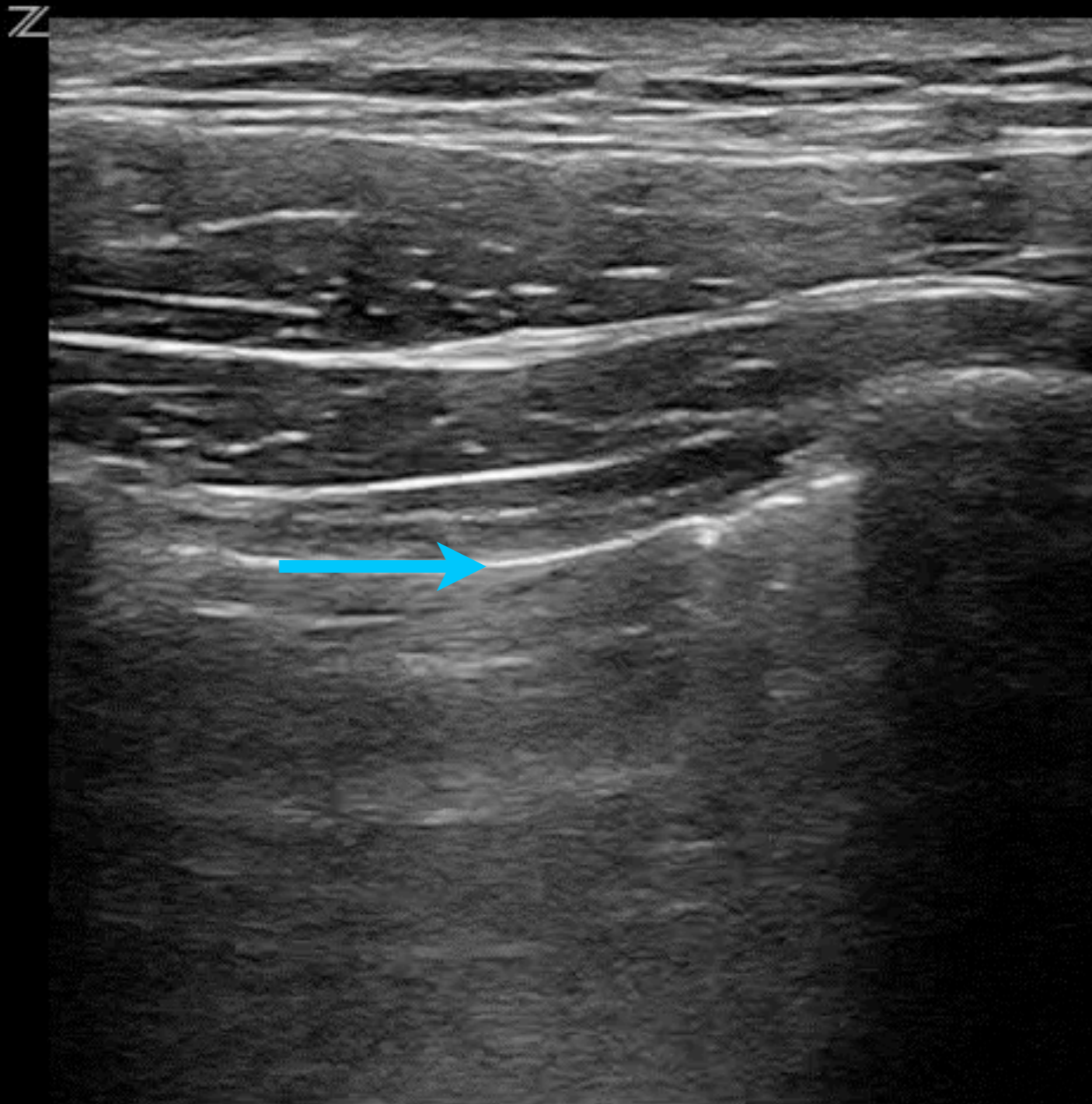
-1

-2

-3

-4
cm

Lung point



L10-5/8.5
DR80/M3/P2
G76/E2/75%
MI1.4 TIs0.1
4.0 cm
32/32 Hz
△ ZSI 0
Image

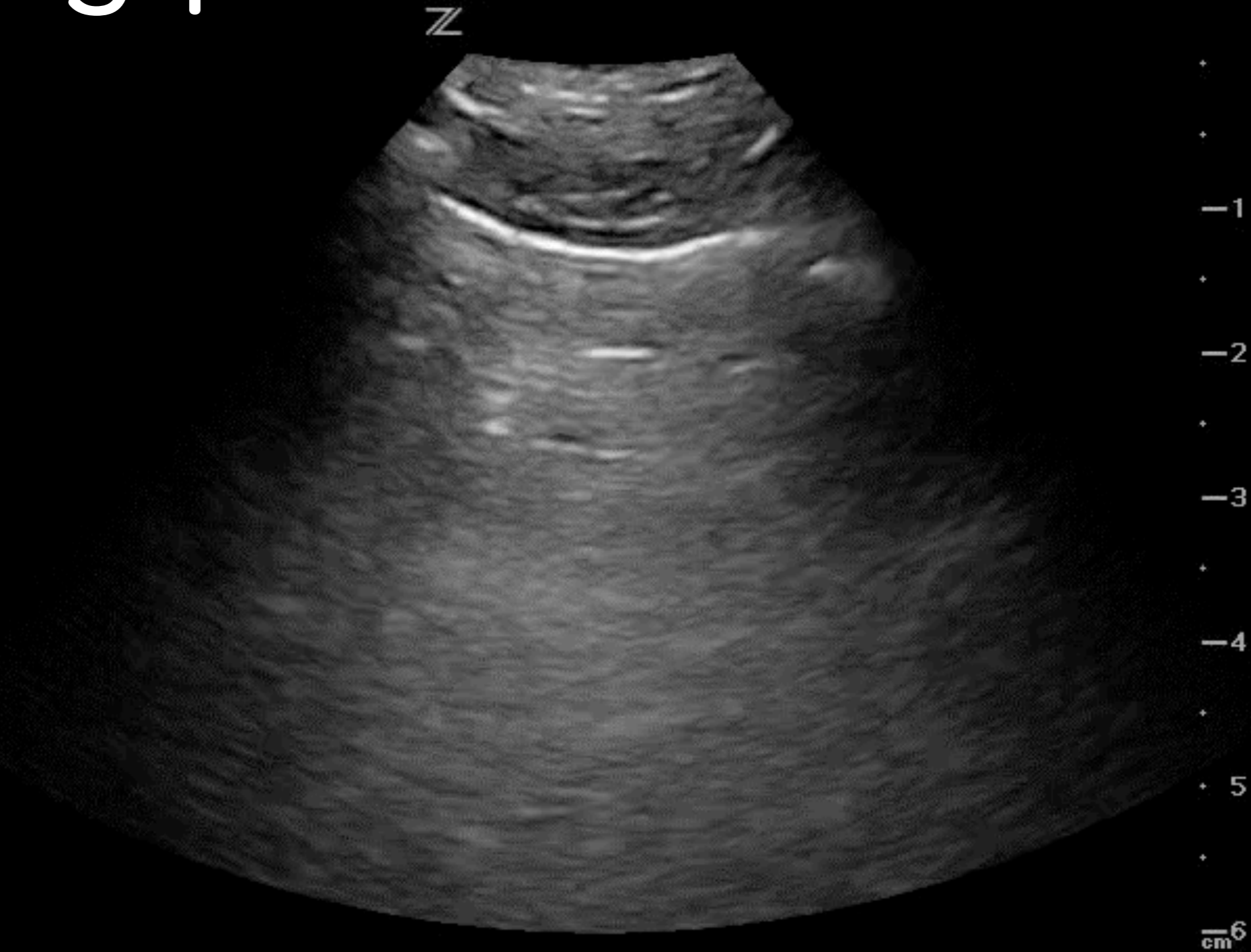
-1

-2

-3

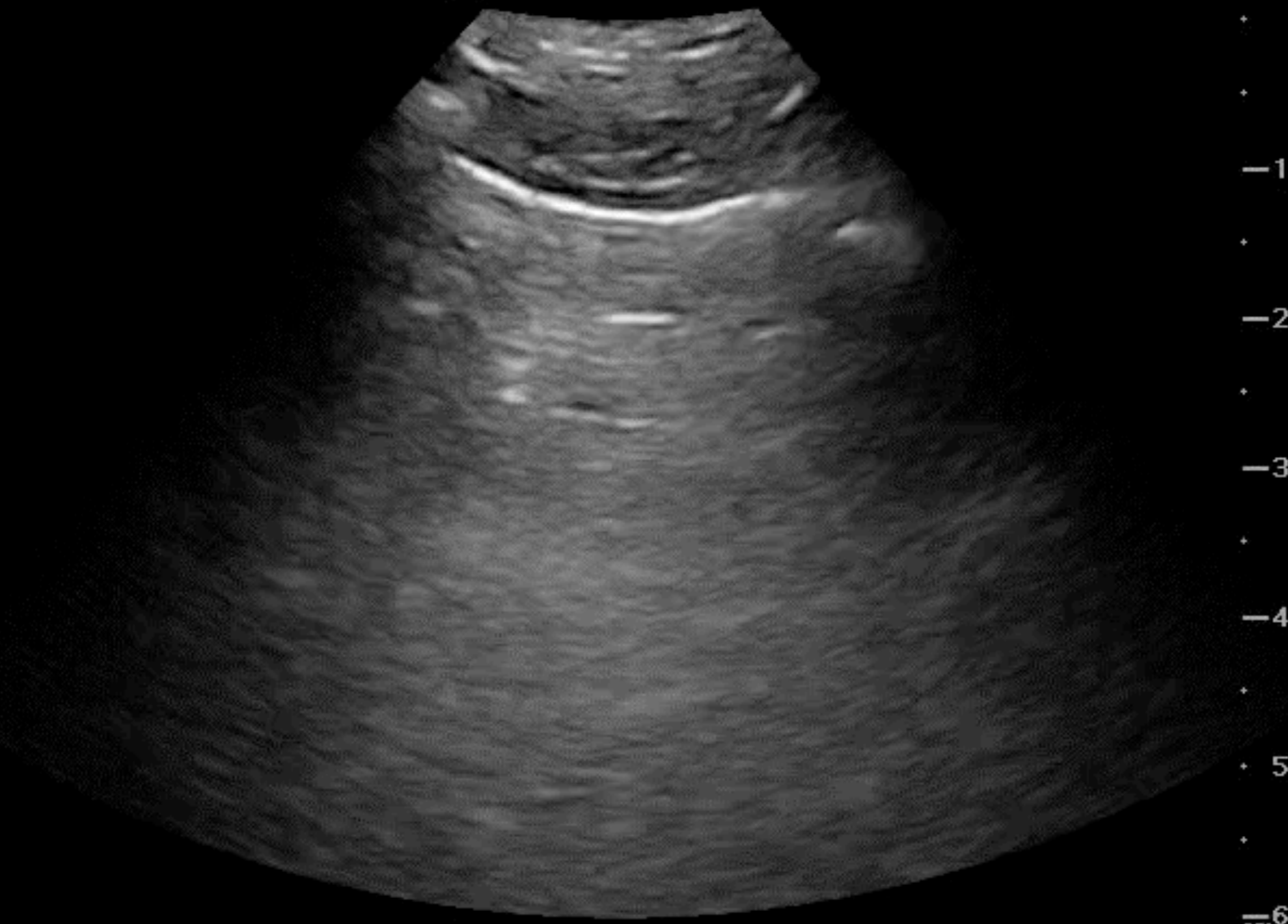cm⁴

Lung point



Lung point

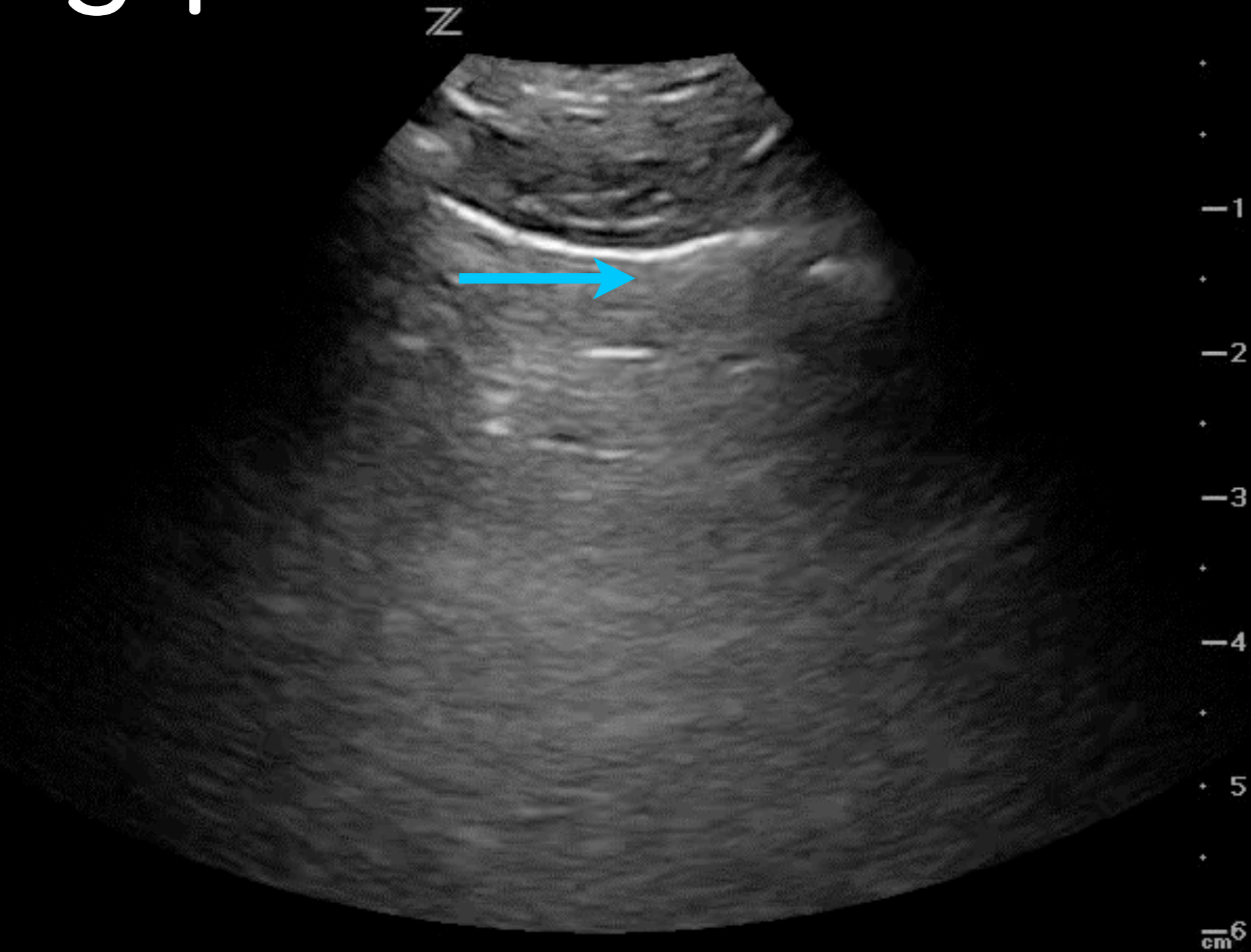
Z



P4-1c/4.0
DR75/M2/P2
G60/E1/100%
MI0.9 TIs0.3
6.0 cm
15/15 Hz
△ ZSI 0
Image

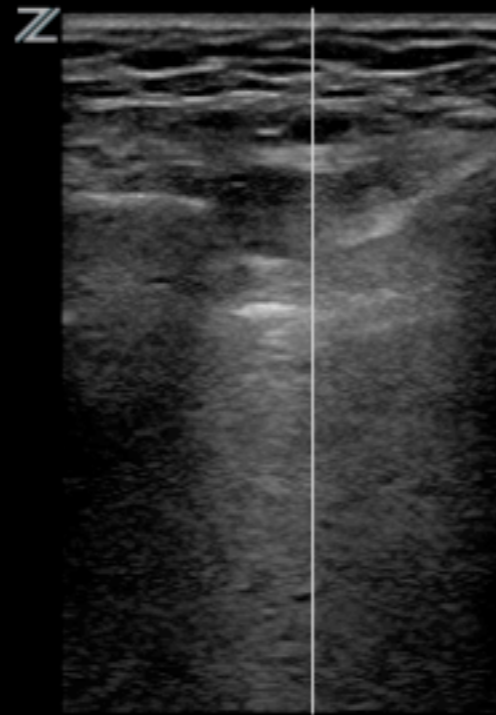
+
+
-1
+
-2
+
-3
+
-4
+
5
+
6
cm

Lung point



P4-1c/4.0
DR75/M2/P2
G60/E1/100%
MI0.9 TIs0.3
6.0 cm
15/15 Hz
△ ZSI 0
Image

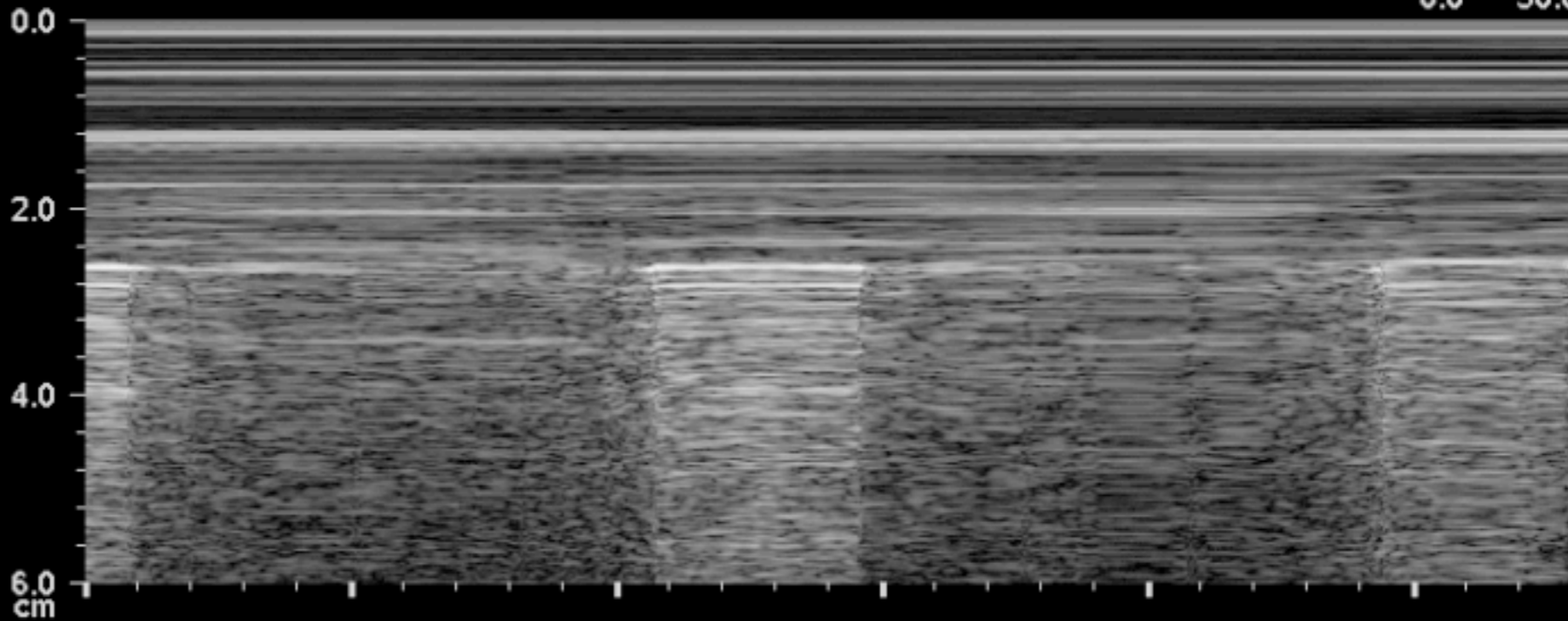
Lung point



SP/Thyroid
L10-5/8.5MHz
DR75/M4/P2
G78/E1/100%
MI1.4 TIs0.1
6.0 cm
10 Hz
ZSI 40
Cine

0.0 30.0

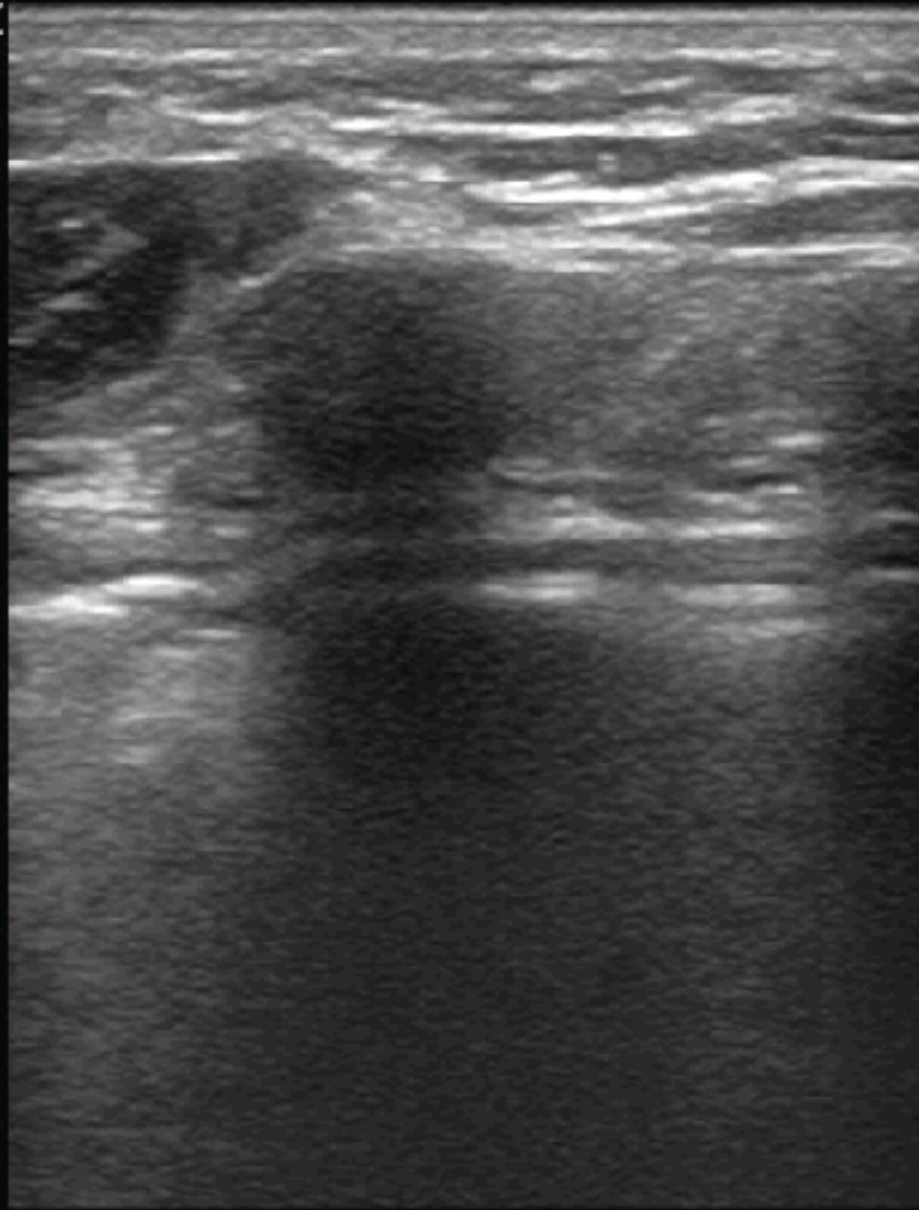
G86
Med
M2
DR65
P0



M-mode

Lung point

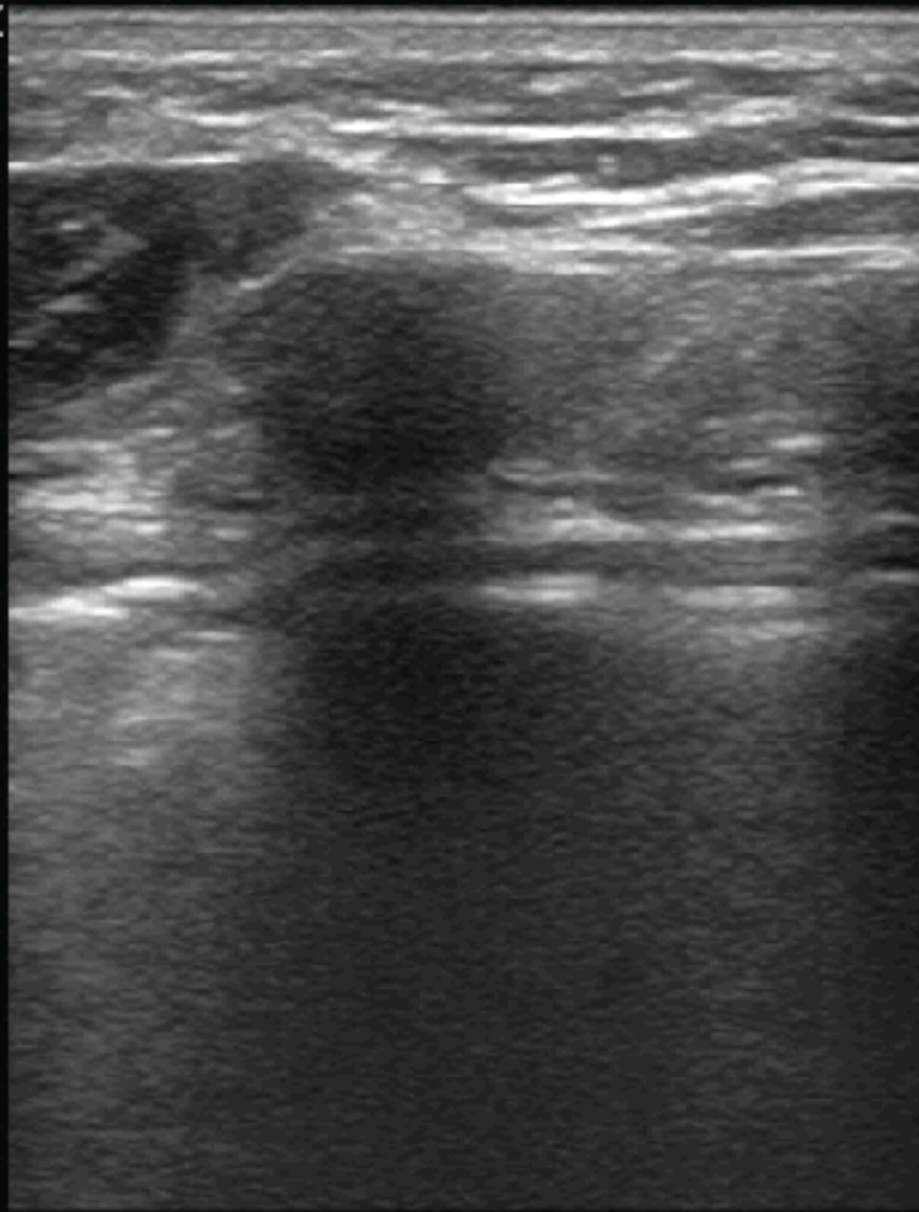
Z



-SP/MuscSkel
L8-3/CH7MHz
DR65/M3/P1
G100/E2/100%
MI1.5 TIs0.3
- 5.0 cm
12 Hz
△ ZSI 20

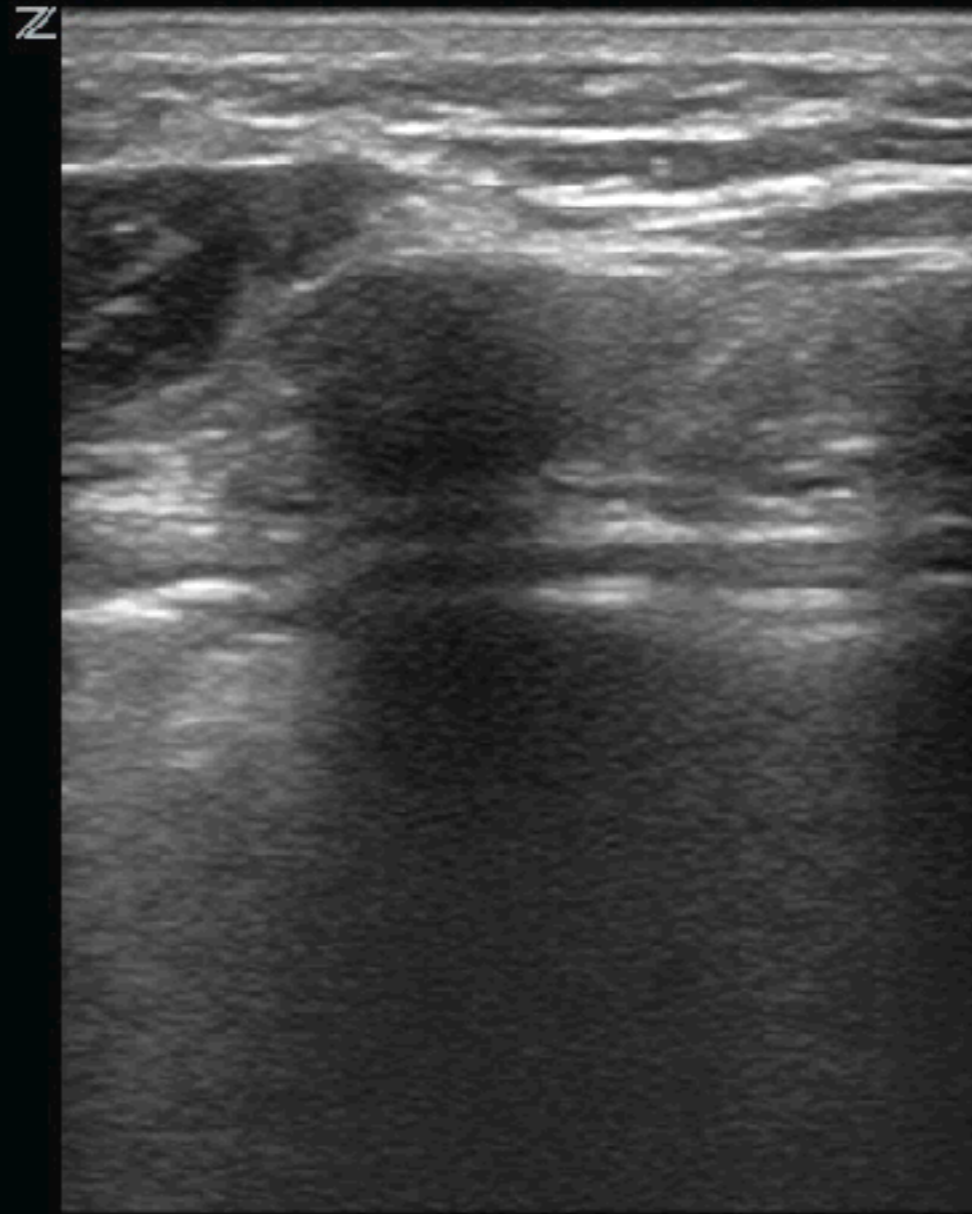
Lung point

Z



-SP/MuscSkel
L8-3/CH7MHz
DR65/M3/P1
G100/E2/100%
MI1.5 TIs0.3
- 5.0 cm
12 Hz
△ ZSI 20

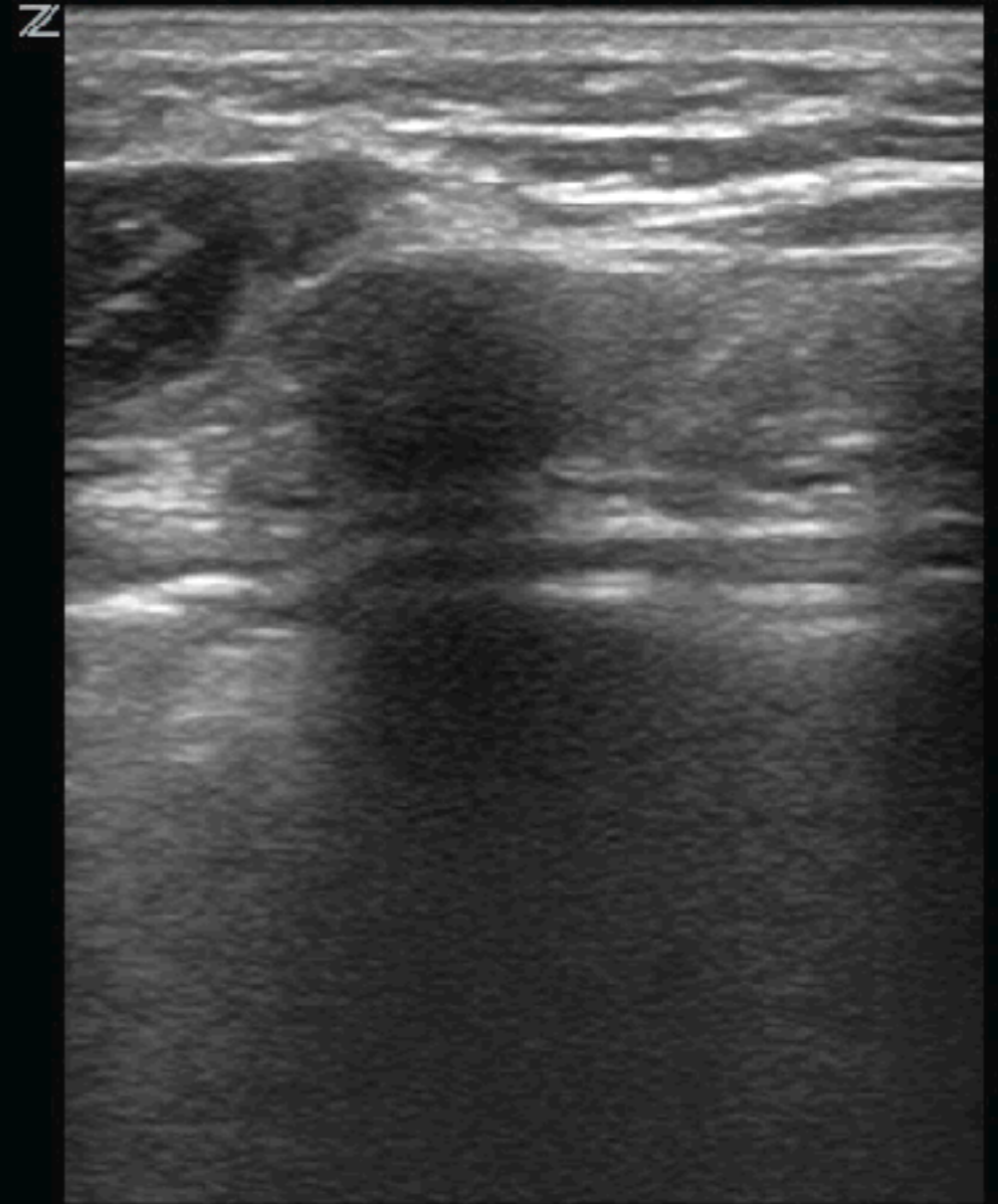
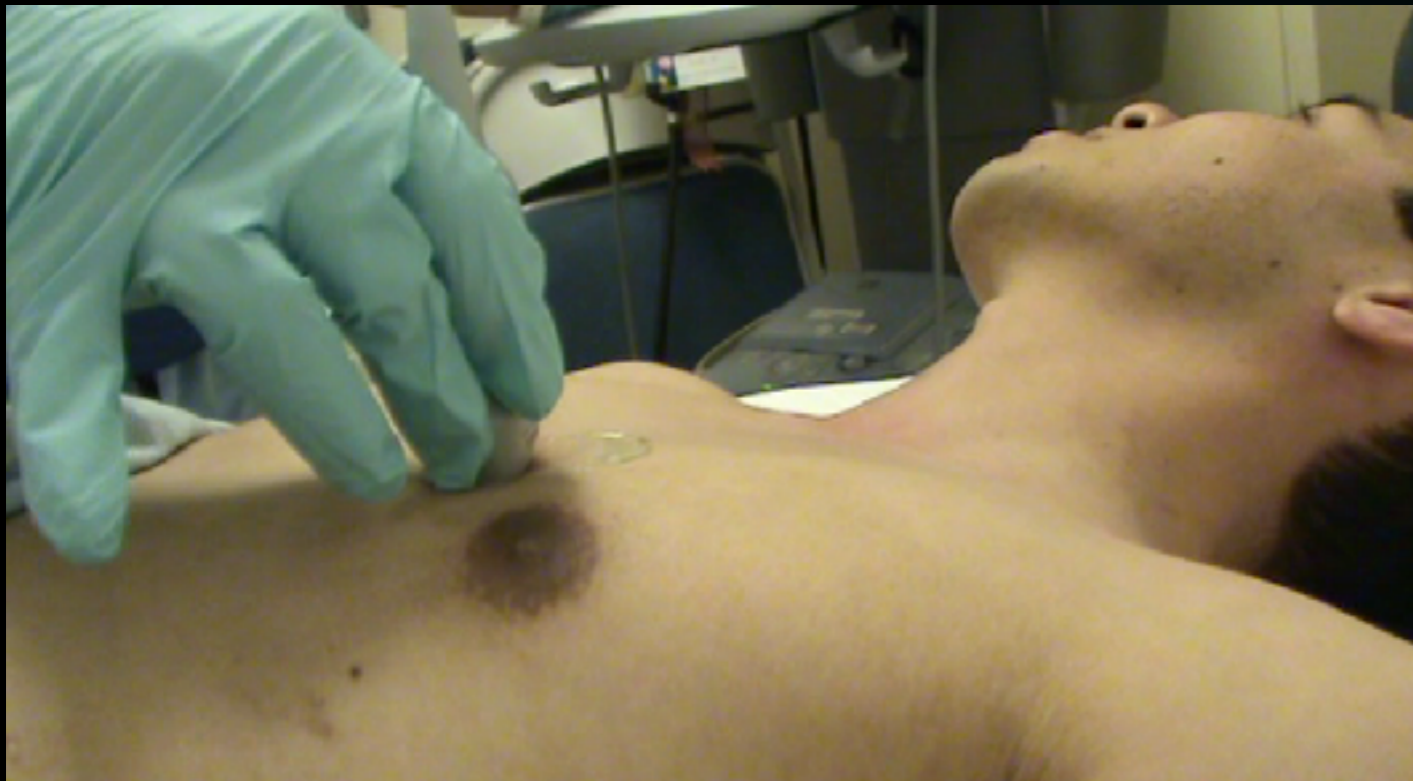Pitfall



-SP/MuscSkel
L8-3/CH7MHz
DR65/M3/P1
G100/E2/100%
MI1.5 TIs0.3
- 5.0 cm
12 Hz
△ ZSI 20

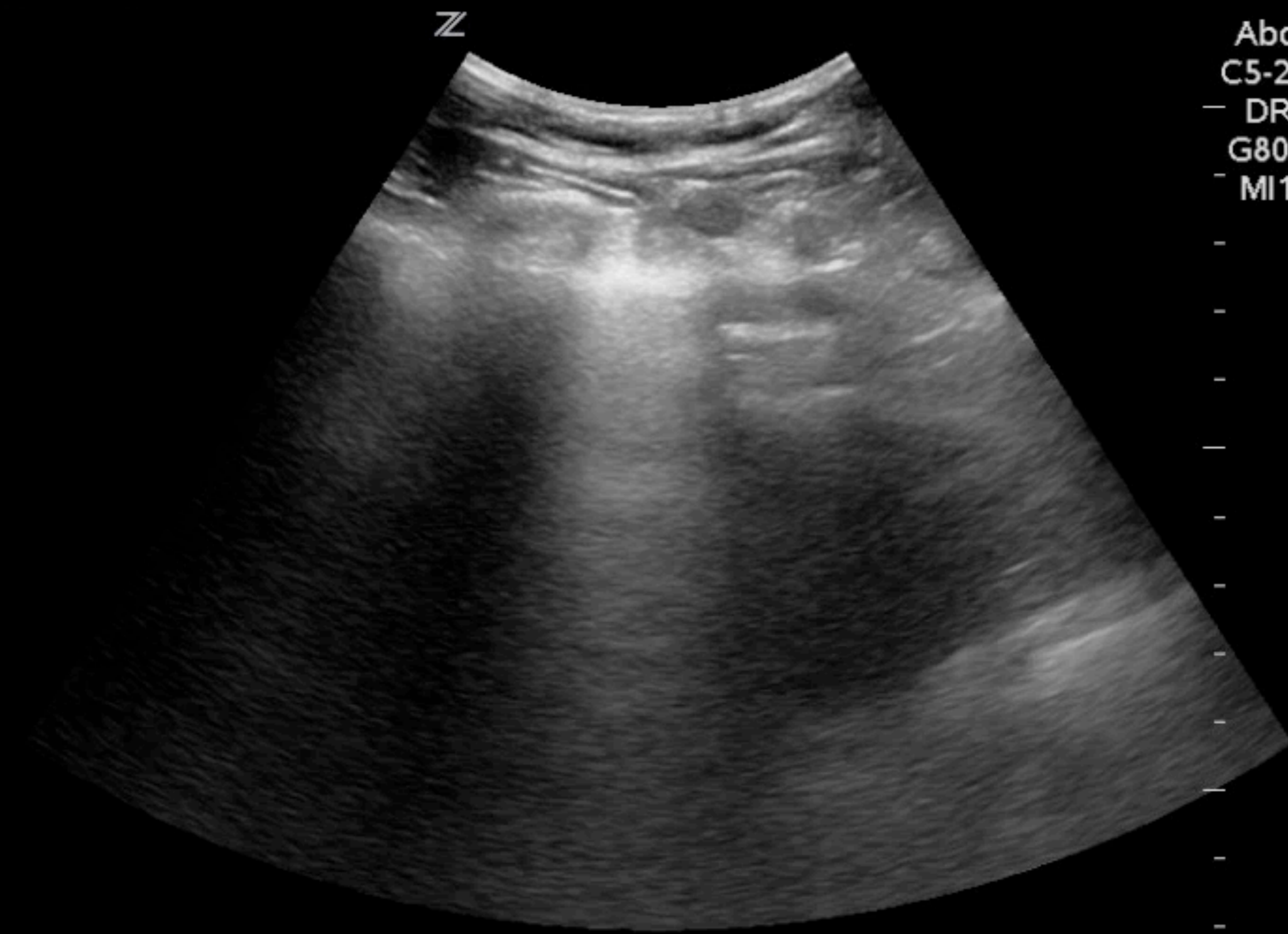Heart

Pitfall



Heart

Be aware of probe location



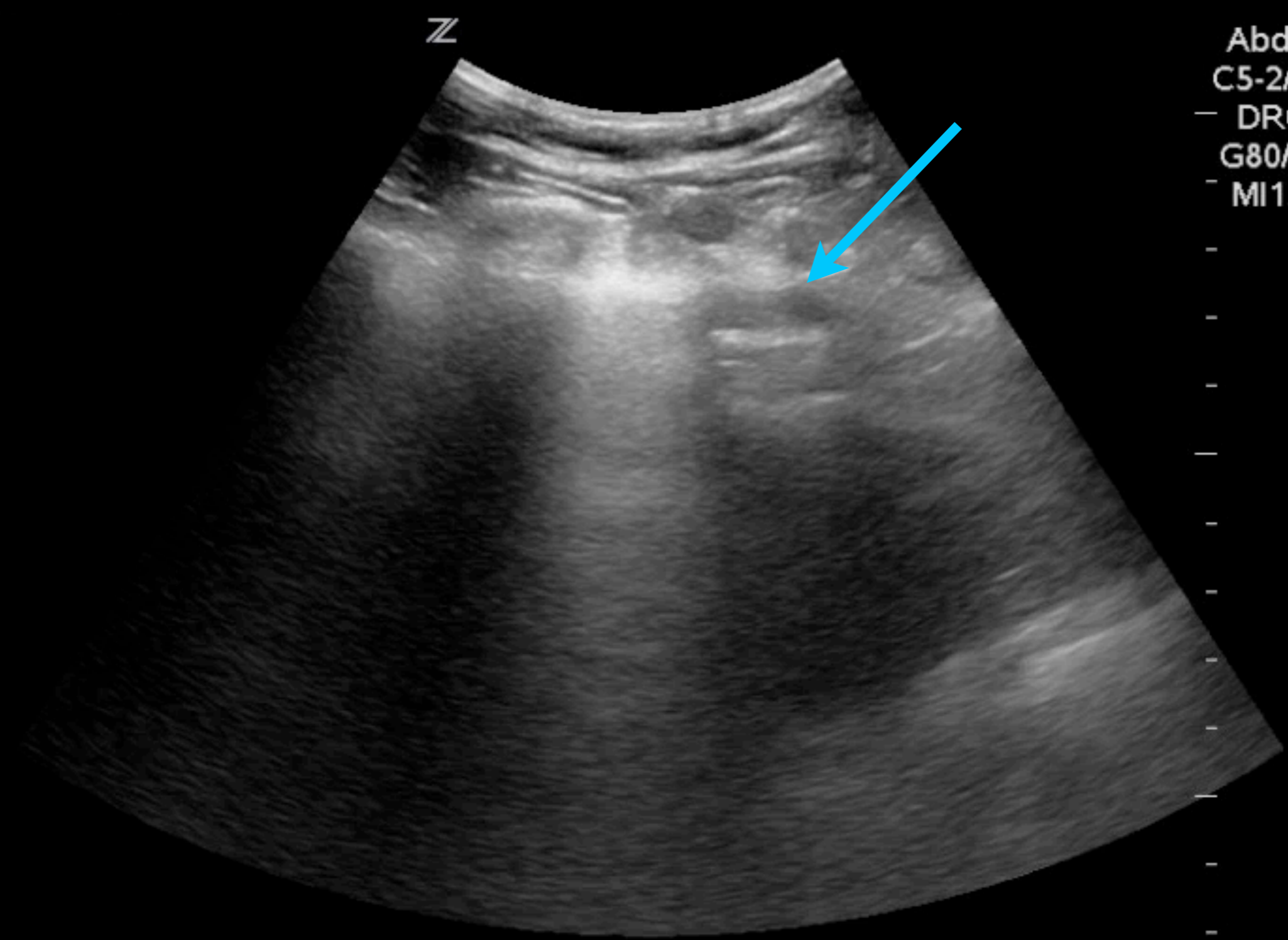
Abd/General
C5-2/CH4MHz
— DR60/M3/P2
G80/E1/100%
— MI1.1 TIs0.1
12.0 cm
16 Hz
△ ZSI 0

Heart



Abd/General
C5-2/CH4MHz
— DR60/M3/P2
G80/E1/100%
— MI1.1 TIs0.1
12.0 cm
16 Hz
△ ZSI 0

Heart

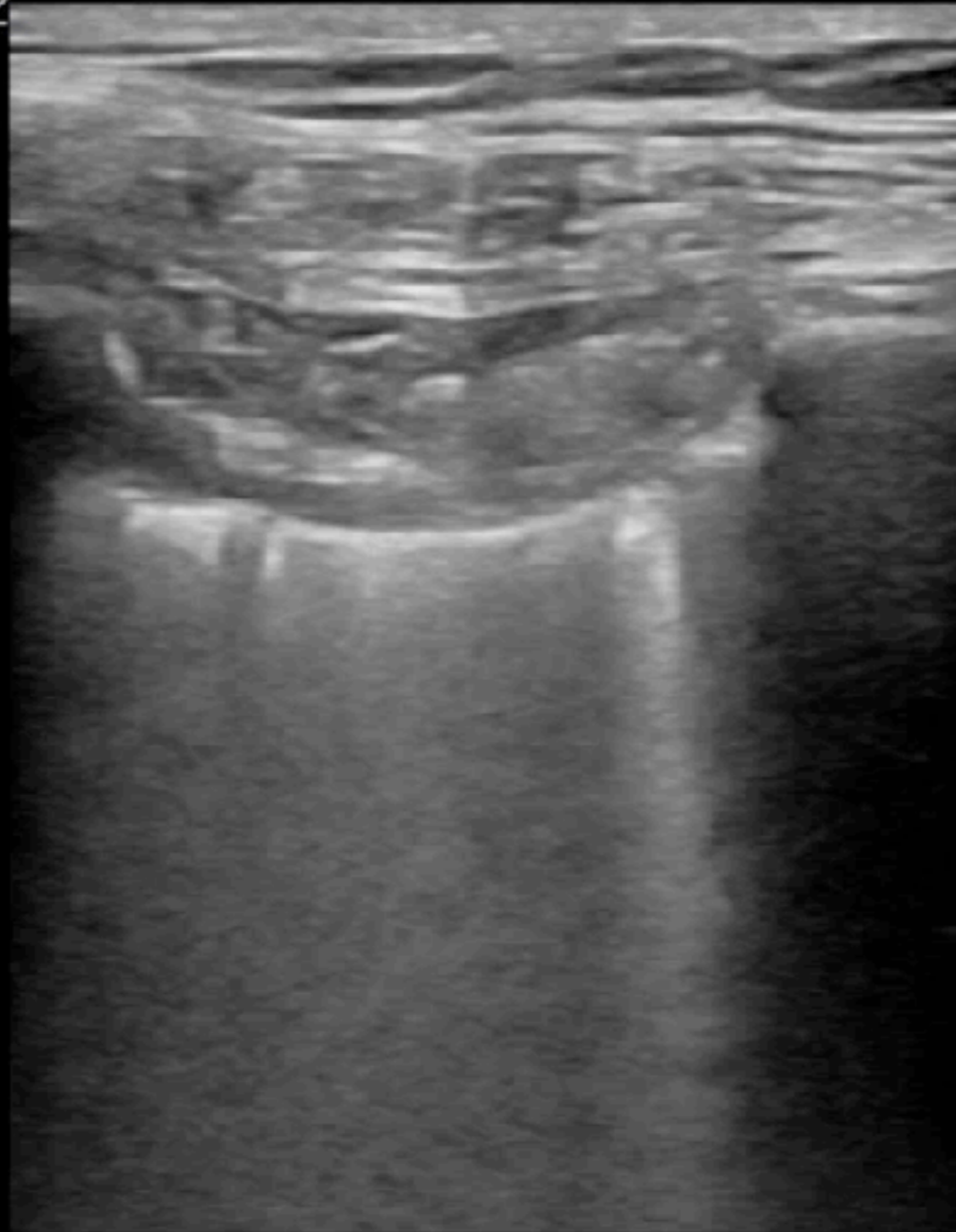

Abd/General
C5-2/CH4MHz
— DR60/M3/P2
G80/E1/100%
— MI1.1 TIs0.1
12.0 cm
16 Hz
△ ZSI 0

Heart

Don't confuse with lung point

Z



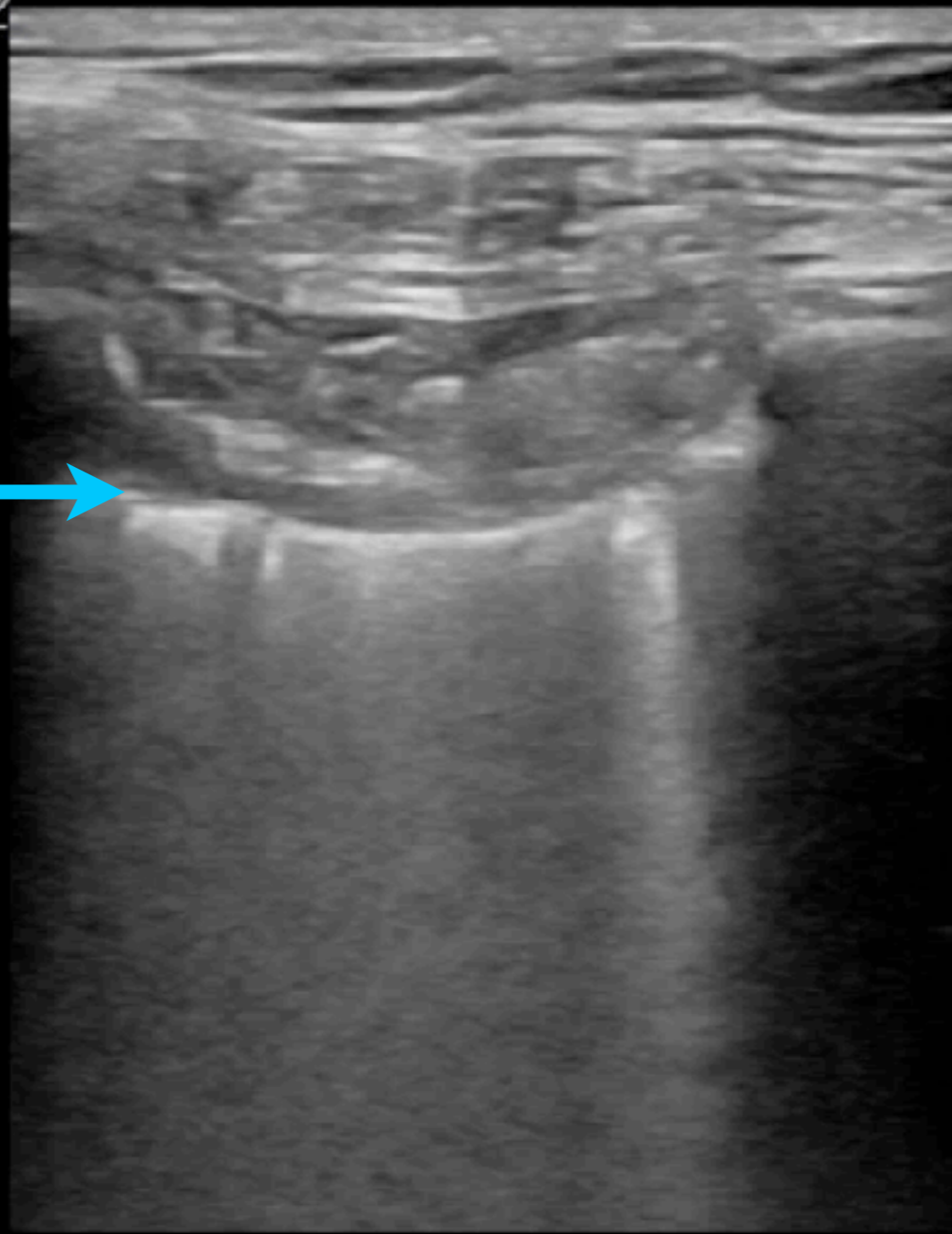
SPV asc_Access
L10-5/CH8MHz
DR65/M5/P3

Z

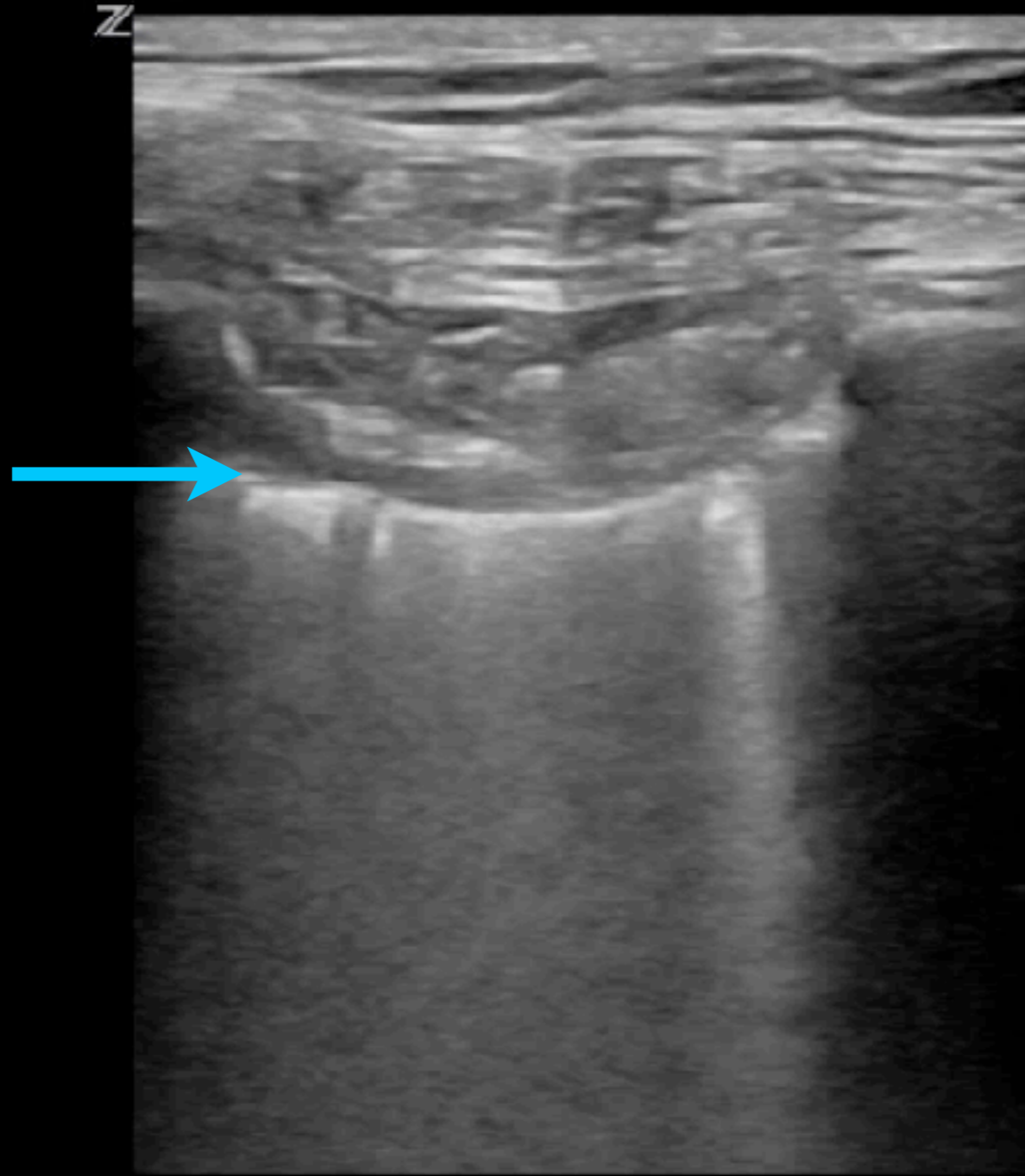


SPV asc_Access
L10-5/CH8MHz
DR65/M5/P3

Z



SPA/asc_Access
L10-5/CH8MHz
DR65/M5/P3




SPA/asc_Access
L10-5/CH8MHz
DR65/M5/P3

Lung pulse

= non-ventilated lung, excludes pneumothorax

Interpretation



Lung sliding?

Lung sliding?

A-lines?

Lung sliding?

A-lines?

B-lines?

Lung sliding?

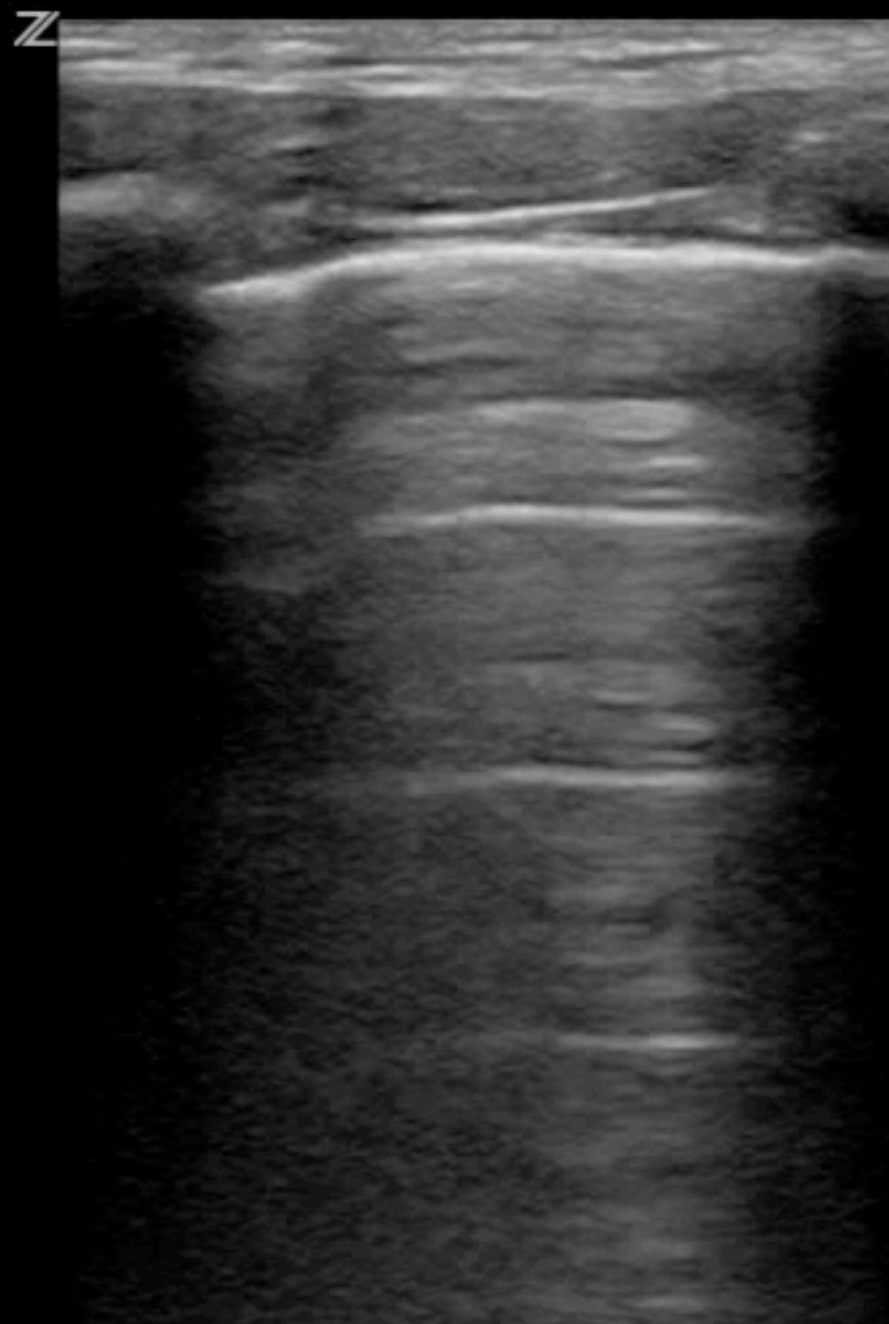
A-lines?

B-lines?

Consolidations or Effusions?

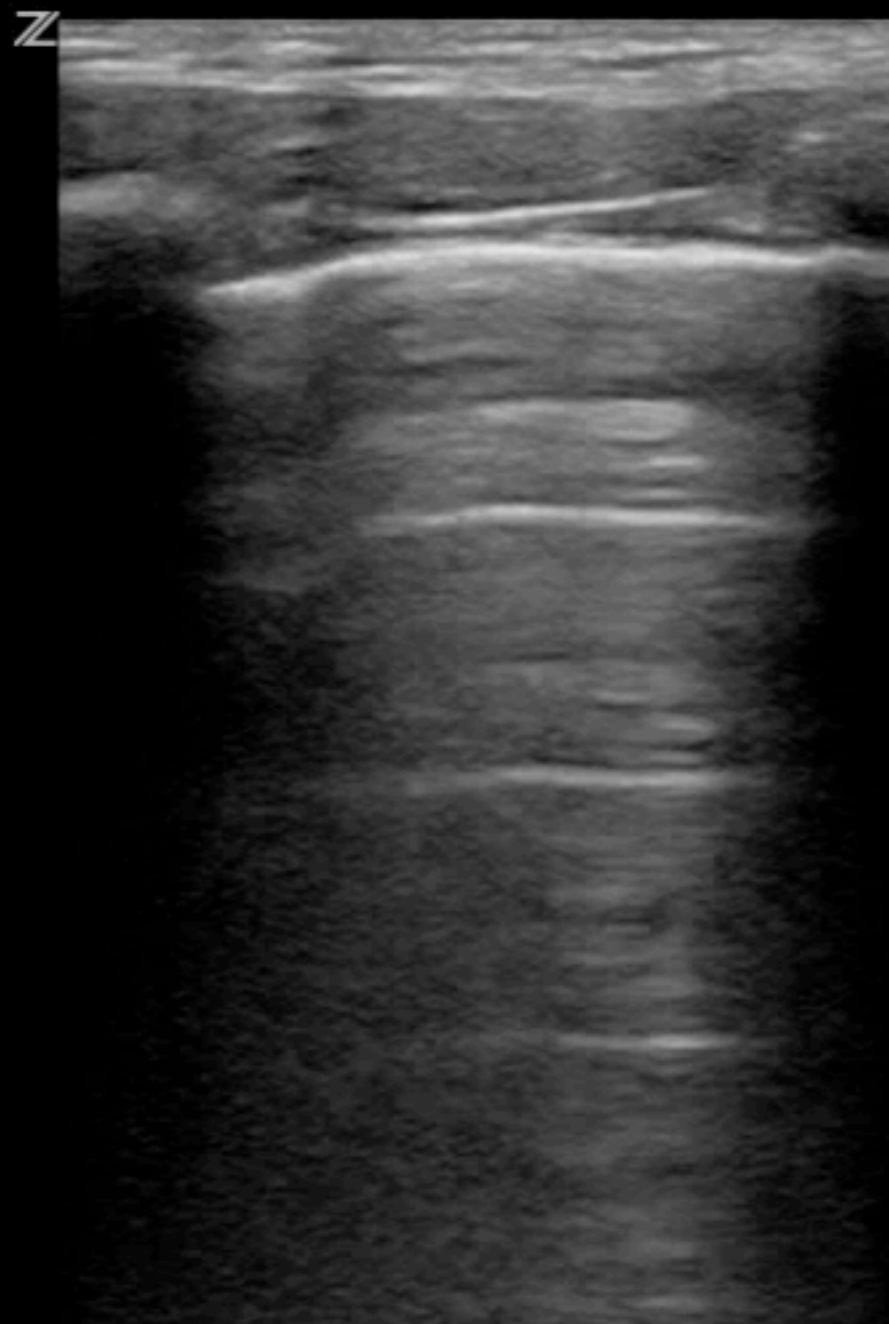
A-lines?

A-lines



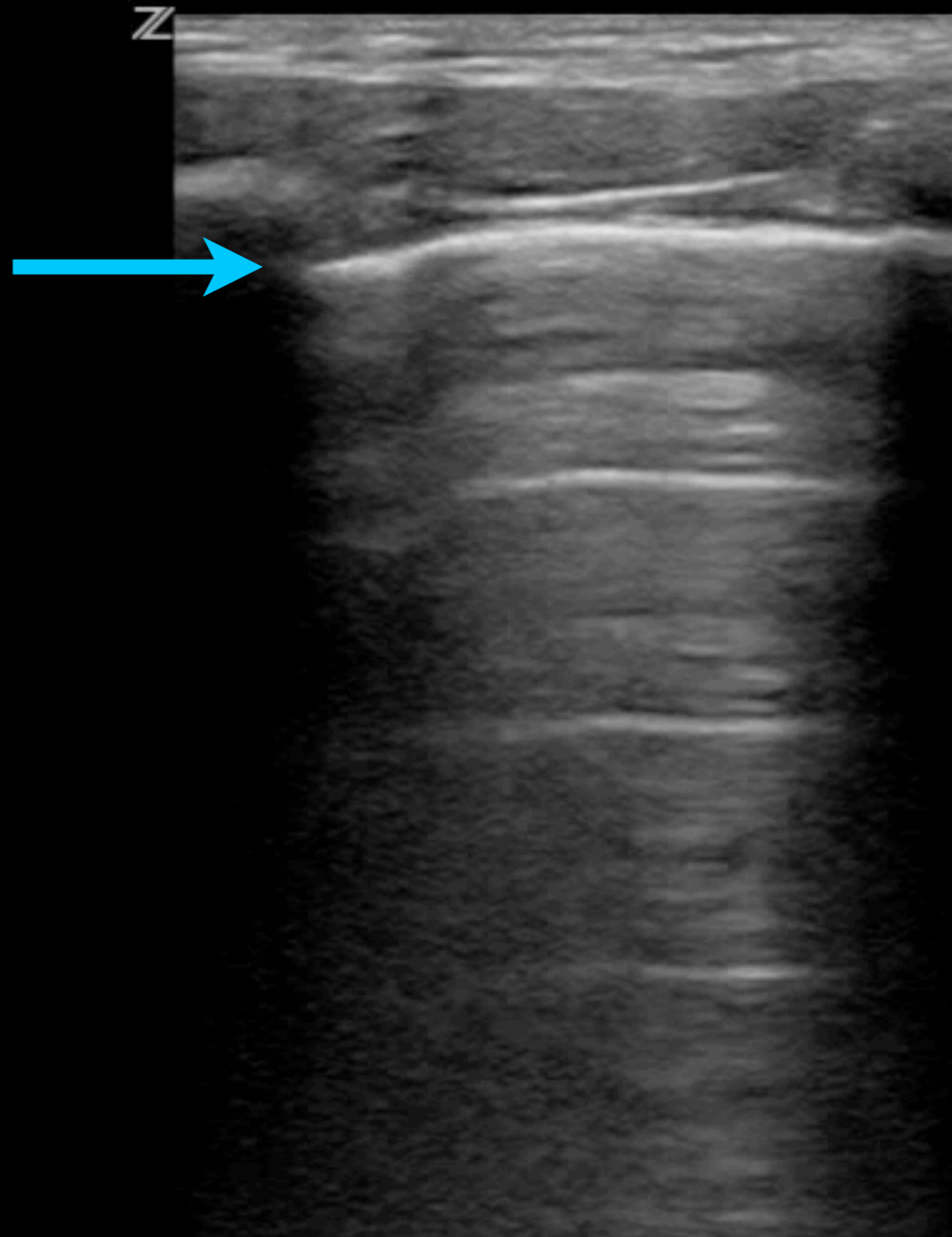
— Abd/PTX
L10-5/CH8MHz
· DR70/M3/P2
G86/E2/100%
- MI1.3 TIs0.1
6.0 cm
· 12 Hz
△ ZSI 0

A-lines



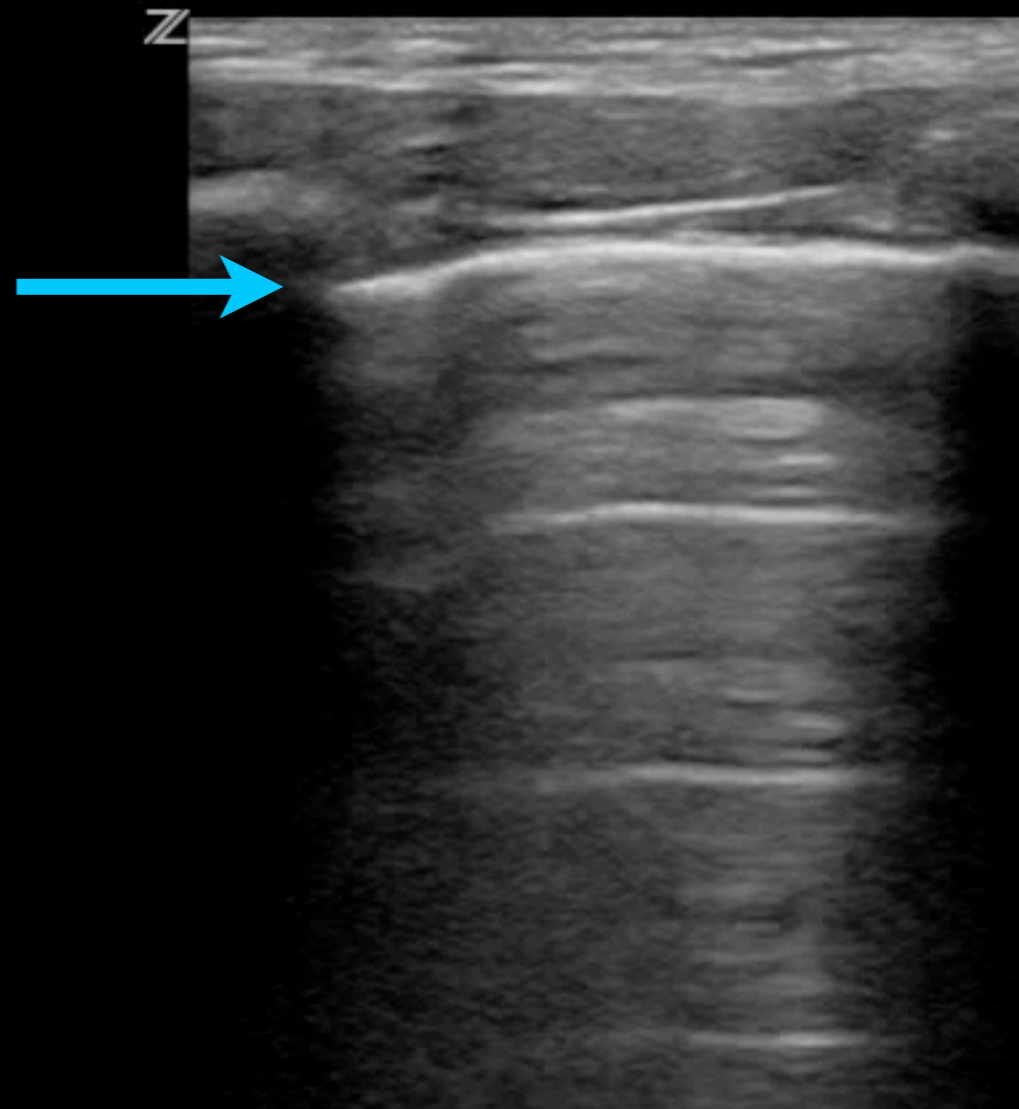
— Abd/PTX
L10-5/CH8MHz
· DR70/M3/P2
G86/E2/100%
- MI1.3 TIs0.1
6.0 cm
· 12 Hz
△ ZSI 0

A-lines



— Abd/PTX
L10-5/CH8MHz
· DR70/M3/P2
G86/E2/100%
- MI1.3 TIs0.1
6.0 cm
· 12 Hz
△ ZSI 0

A-lines

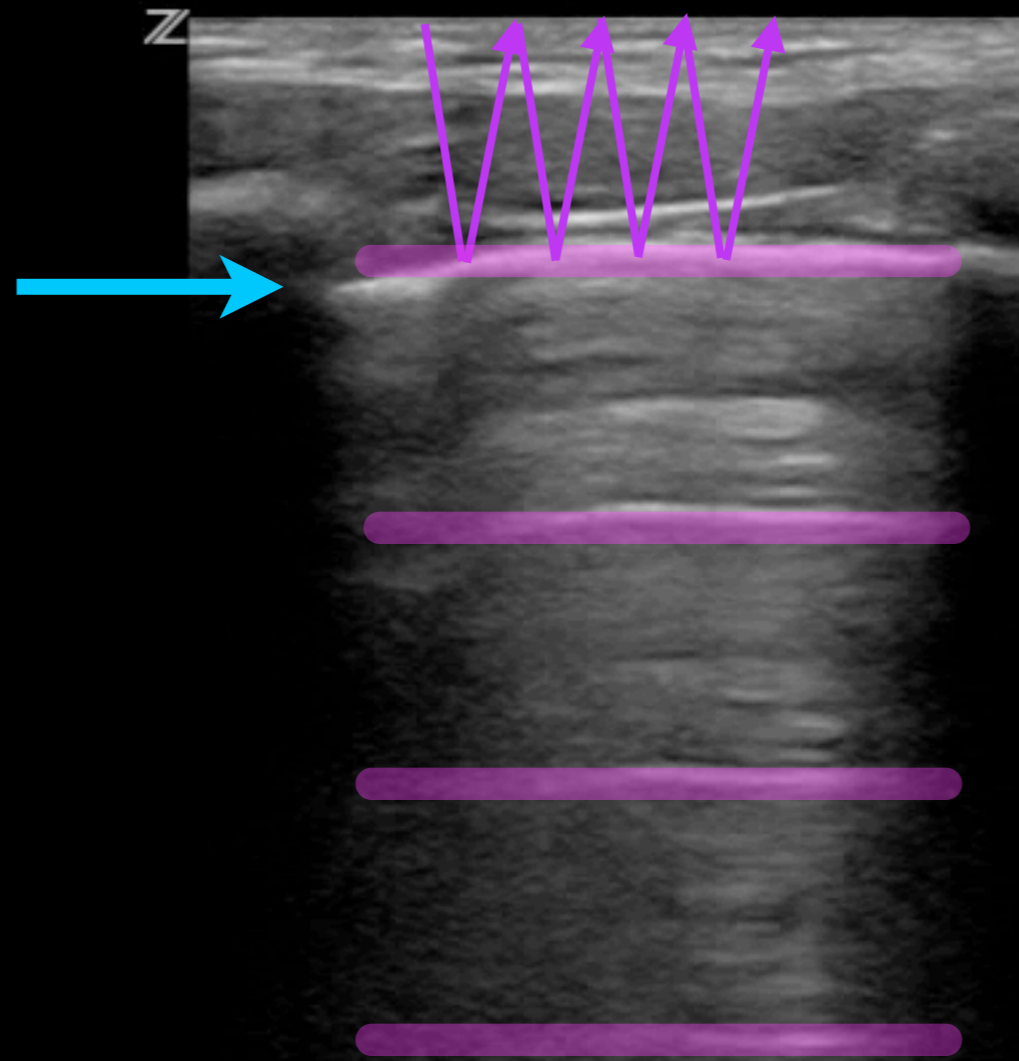


— Abd/PTX
L10-5/CH8MHz
· DR70/M3/P2
G86/E2/100%
- MI1.3 TIs0.1
6.0 cm
· 12 Hz
△ ZSI 0

Reverberation artifacts

Equal distance from skin to pleural line

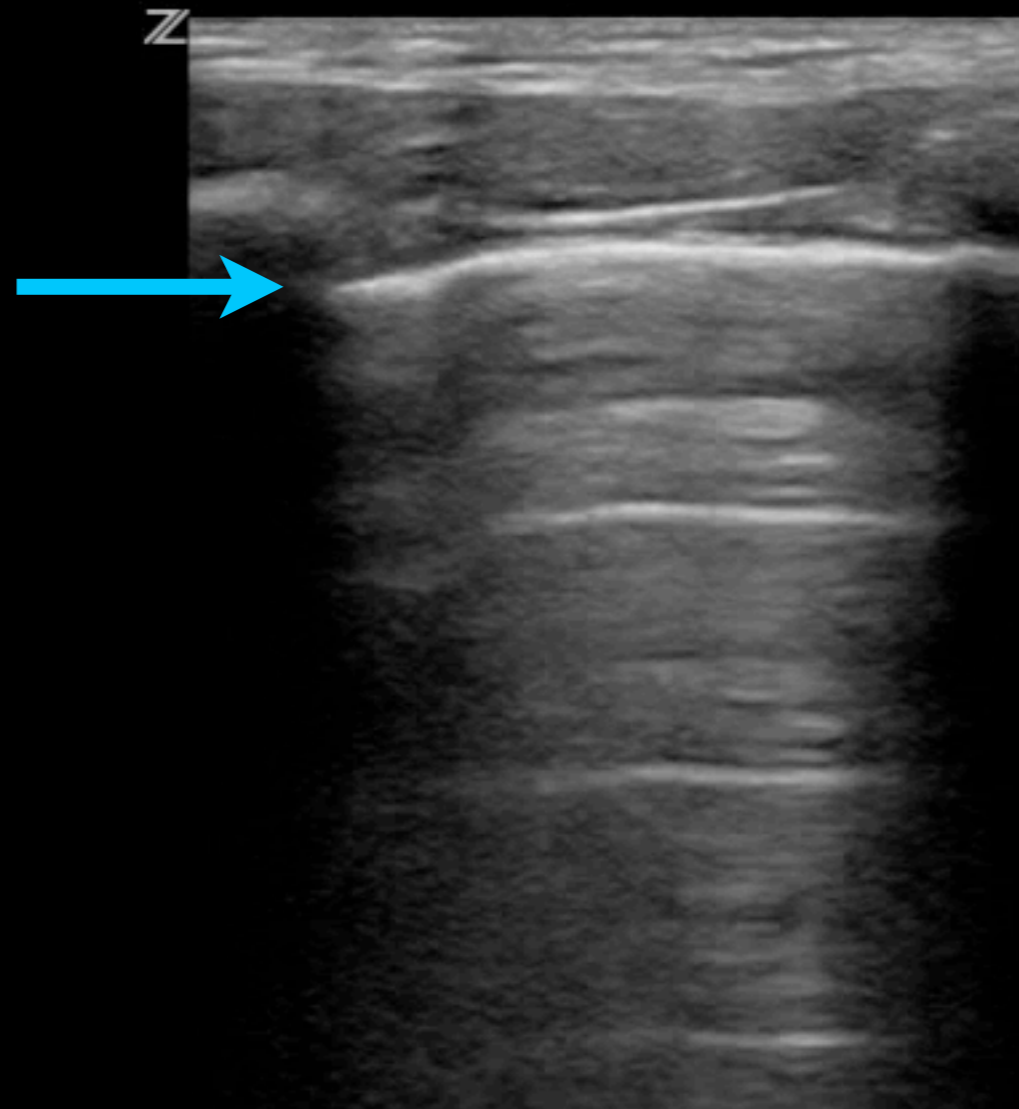
A-lines



— Abd/PTX
L10-5/CH8MHz
· DR70/M3/P2
G86/E2/100%
- MI1.3 TIs0.1
6.0 cm
· 12 Hz
△ ZSI 0

Reverberation artifacts
Equal distance from skin to pleural line

A-lines

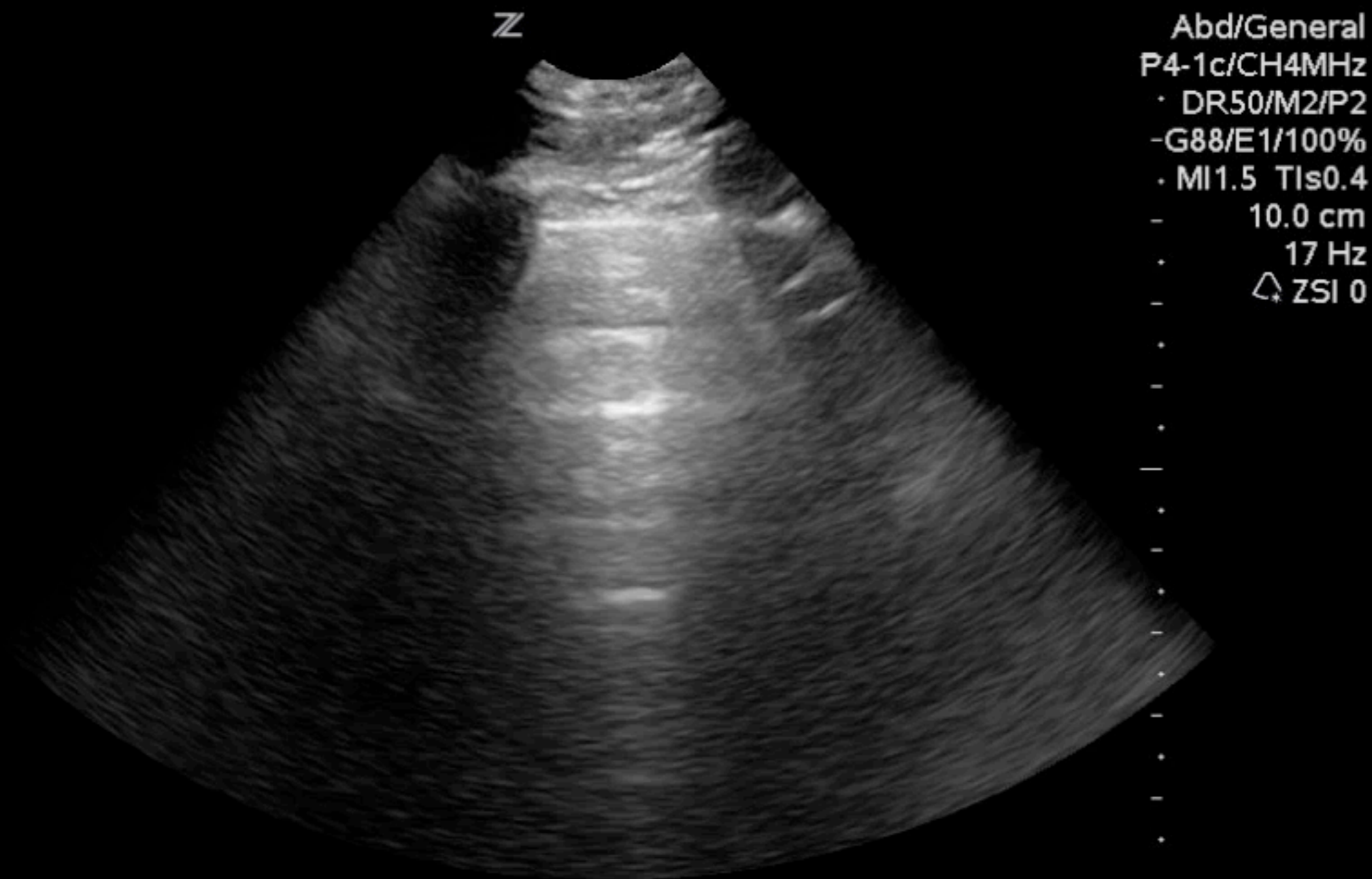


— Abd/PTX
L10-5/CH8MHz
· DR70/M3/P2
G86/E2/100%
- MI1.3 TIs0.1
6.0 cm
· 12 Hz
△ ZSI 0

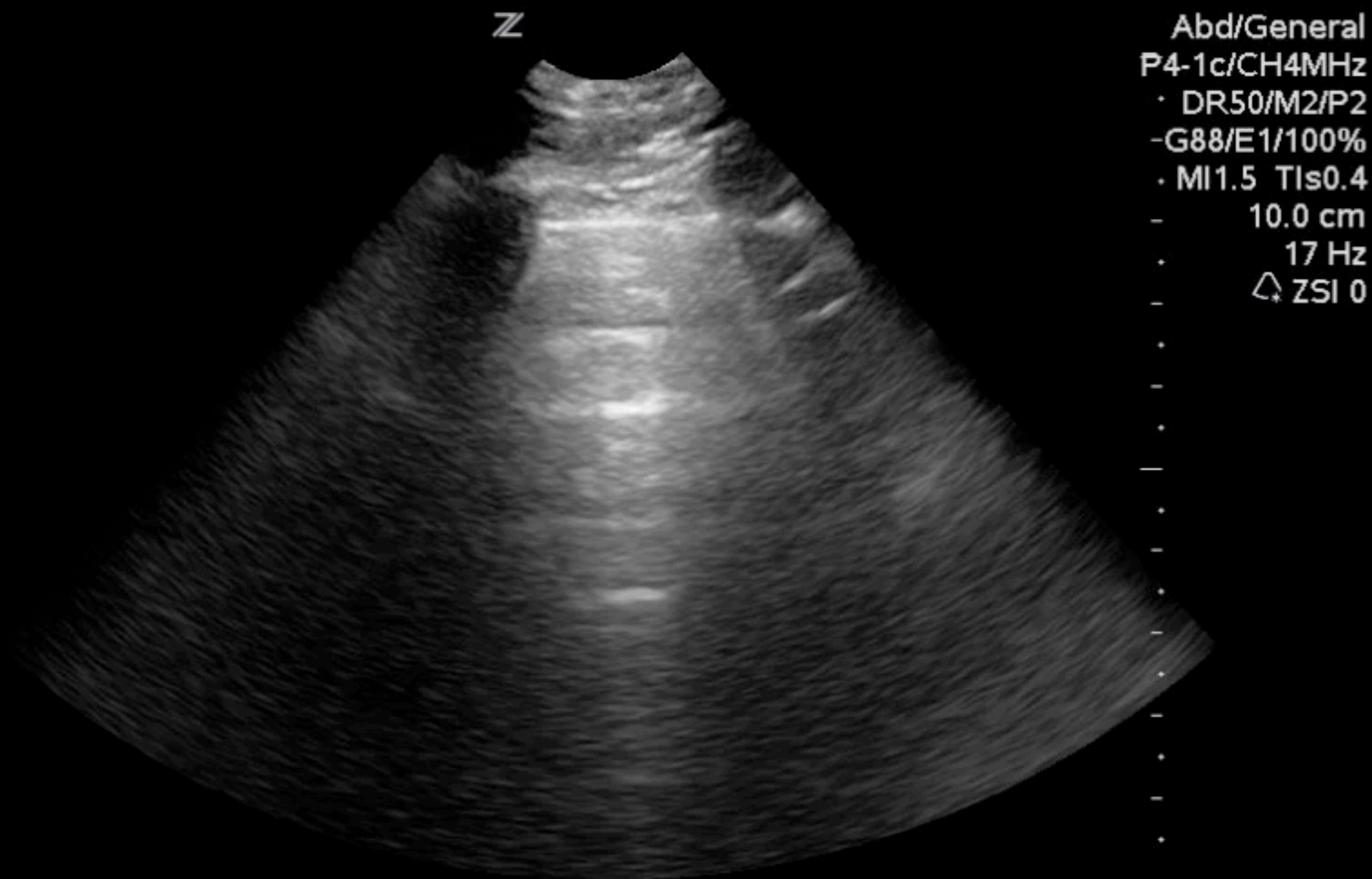
Reverberation artifacts

Equal distance from skin to pleural line

A-lines



A-lines


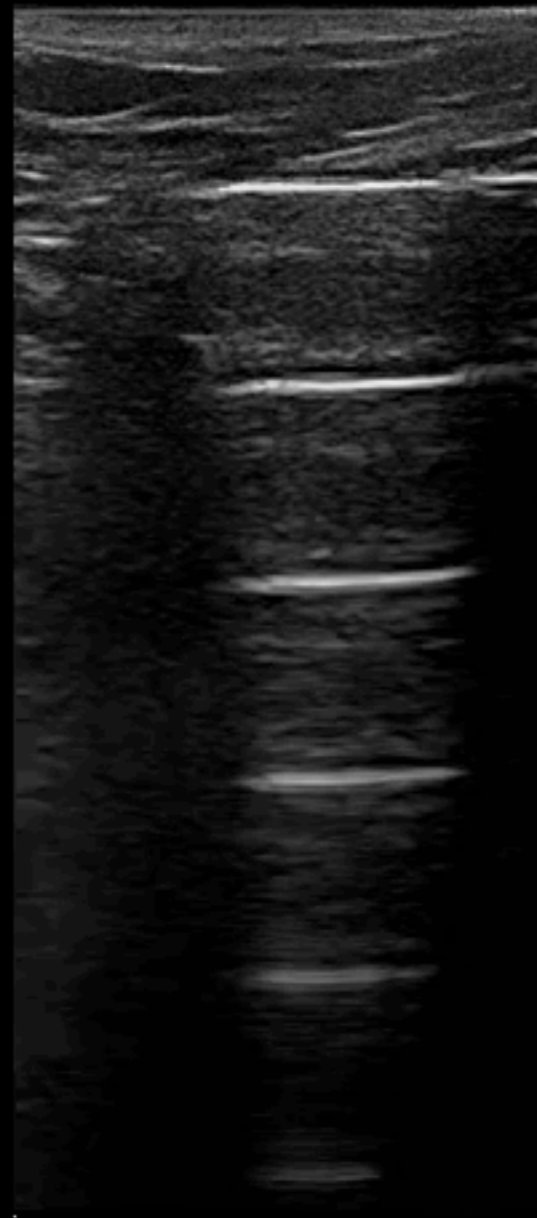


A-lines

Lung
L12-4
25Hz
8.0cm

2D
Gen
Gn 60
60
4/3/4

P



G
P ▲ R
4.0 12.0


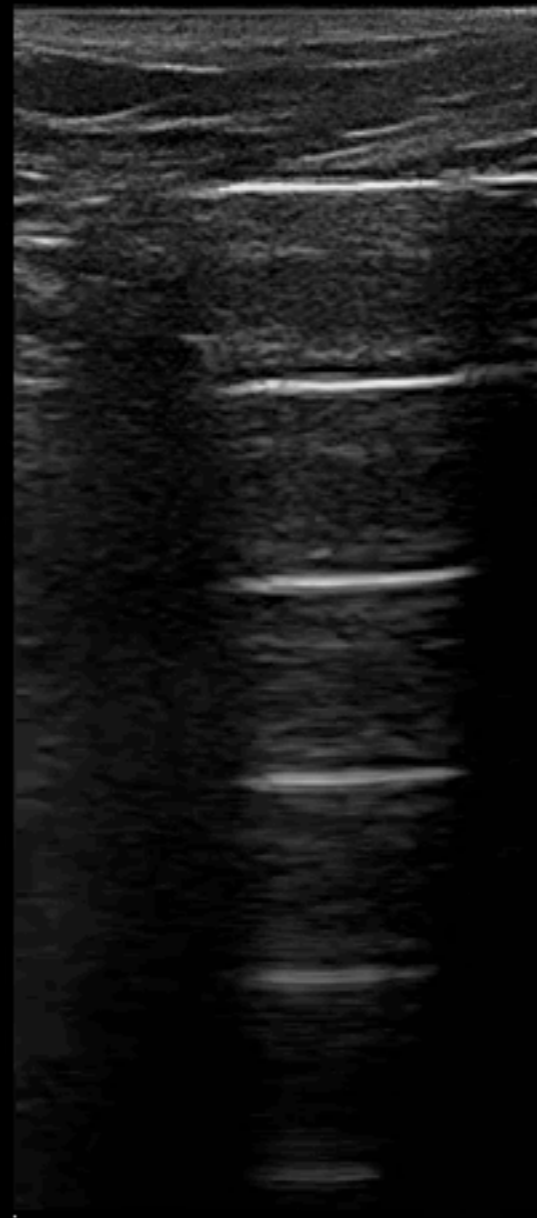
8.0cm

A-lines

Lung
L12-4
25Hz
8.0cm

2D
Gen
Gn 60
60
4/3/4

P



G
P ▲ R
4.0 12.0

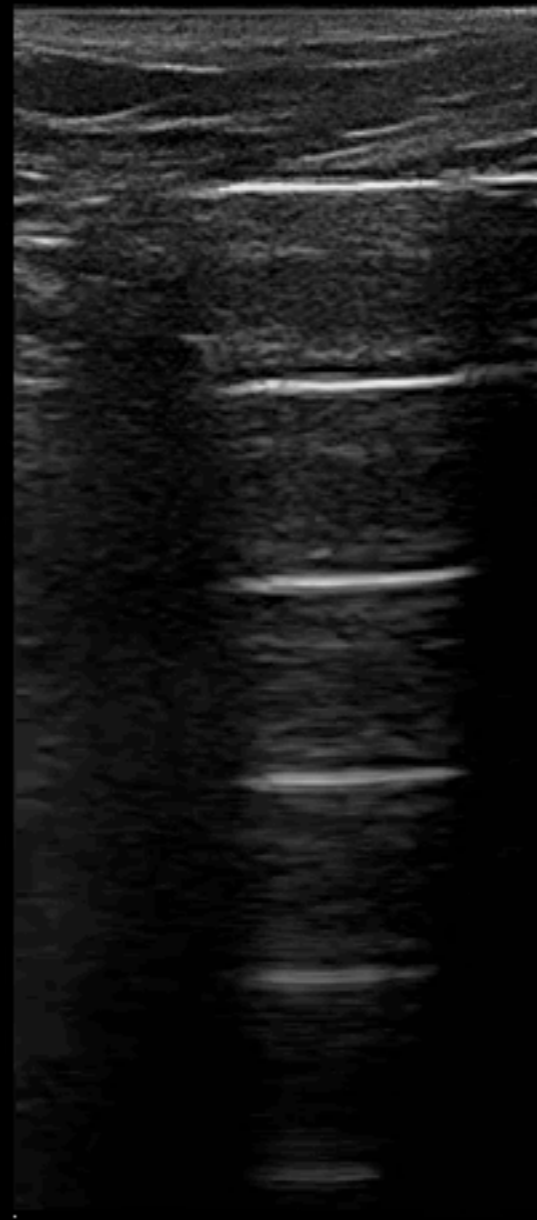
8.0cm

A-lines

Lung
L12-4
25Hz
8.0cm

2D
Gen
Gn 60
60
4/3/4

P



8.0cm

G
P ▲ R
4.0 12.0

Pneumothorax

Remember to look for sliding


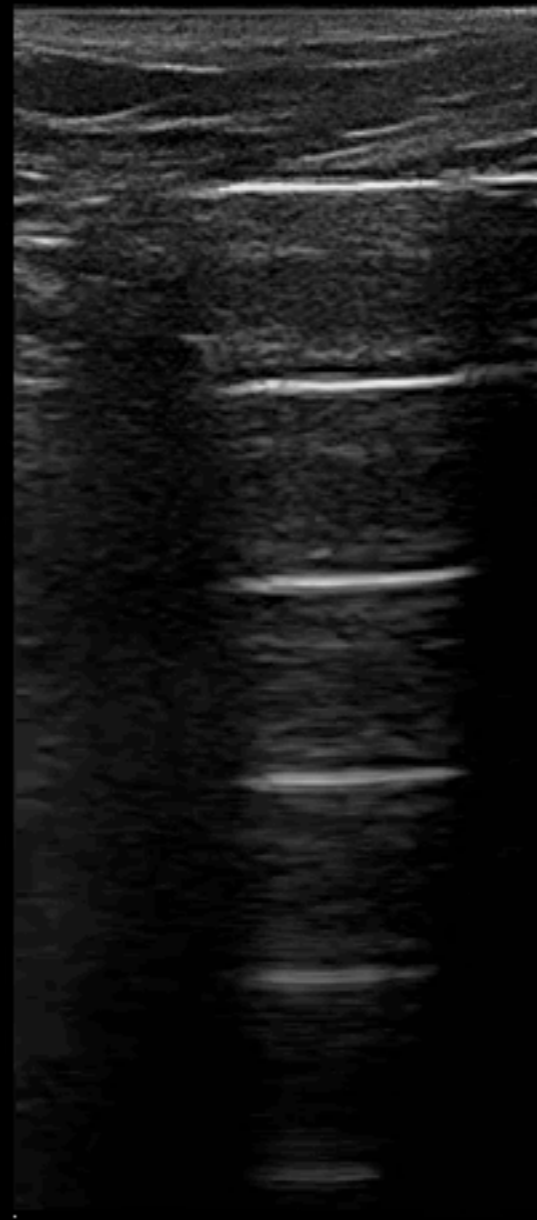
A-lines

Lung
L12-4
25Hz
8.0cm

2D
Gen
Gn 60
60
4/3/4

G
P ▲ R
4.0 12.0

P

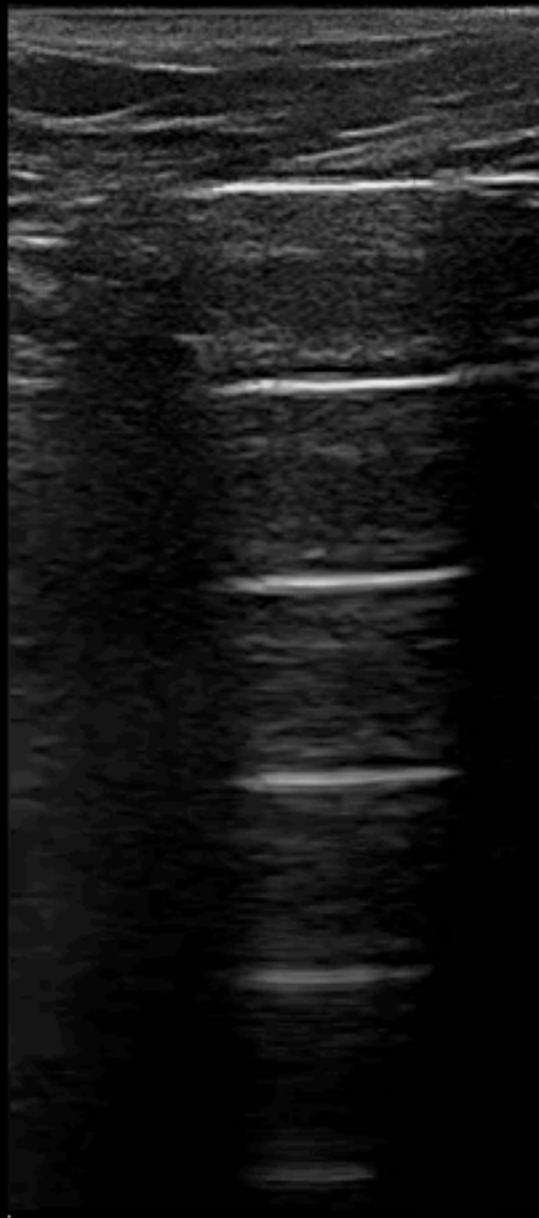


Represents air deep to pleural line

A-lines

Ph

P



Normal lung

Asthma/COPD

Pulmonary embolism

Pneumothorax

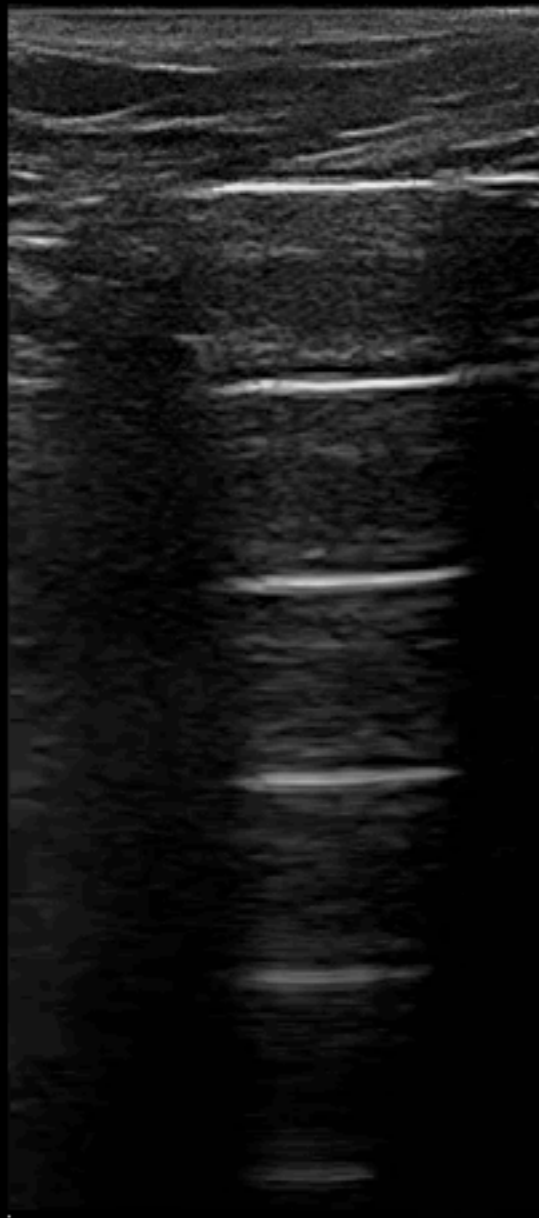
G
P ▲ R
4.0 12.0

Represents air deep to pleural line

A-lines

Ph

P



Normal lung

Asthma/COPD

Pulmonary embolism

Pneumothorax

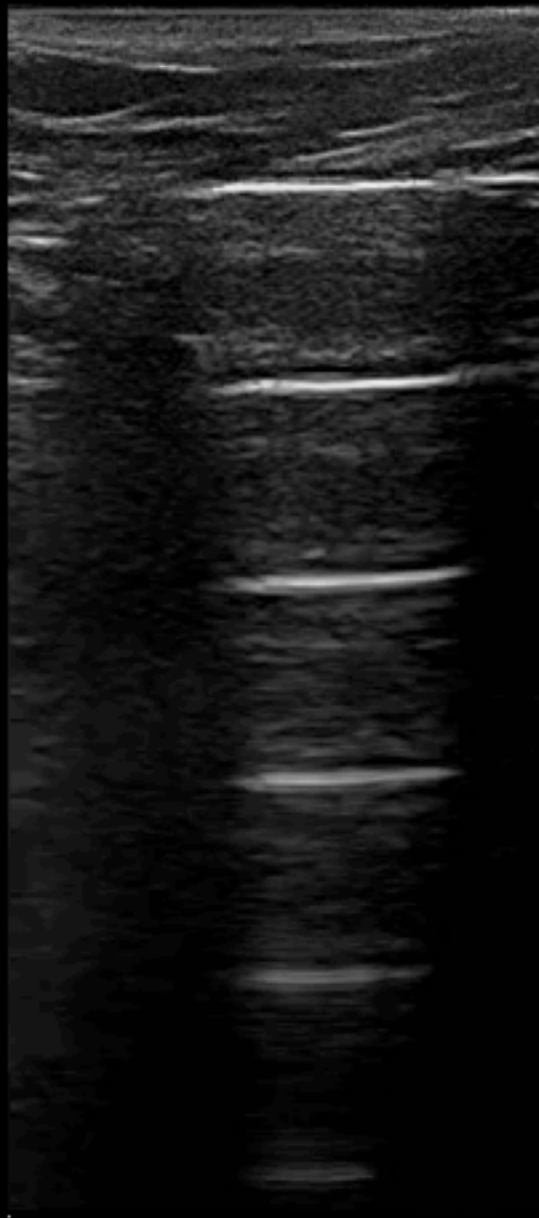
G
P ▲ R
4.0 12.0

Represents air deep to pleural line

A-lines

Ph

P



Normal lung

Asthma/COPD

Pulmonary embolism

Pneumothorax

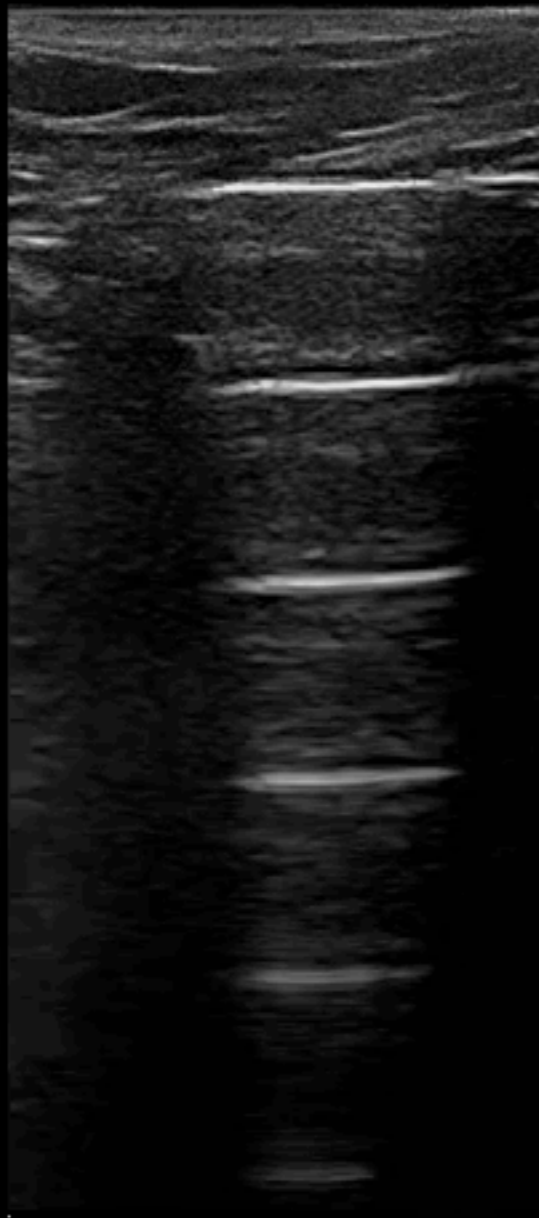
G
P ▲ R
4.0 12.0

Represents air deep to pleural line

A-lines

Ph

P



Normal lung

Asthma/COPD

Pulmonary embolism

Pneumothorax

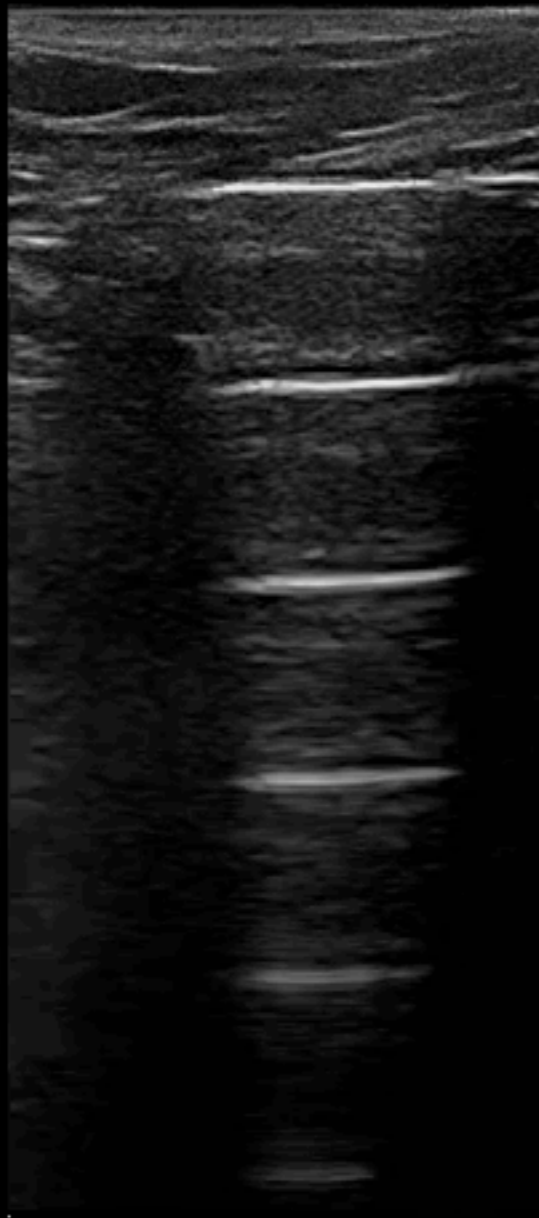
G
P ▲ R
4.0 12.0

Represents air deep to pleural line

A-lines

Ph

P



Normal lung

Asthma/COPD


Pulmonary embolism

Pneumothorax

G
P R
4.0 12.0

Represents air deep to pleural line

Interpretation



Lung sliding?

Lung sliding?

A-lines?

Lung sliding?

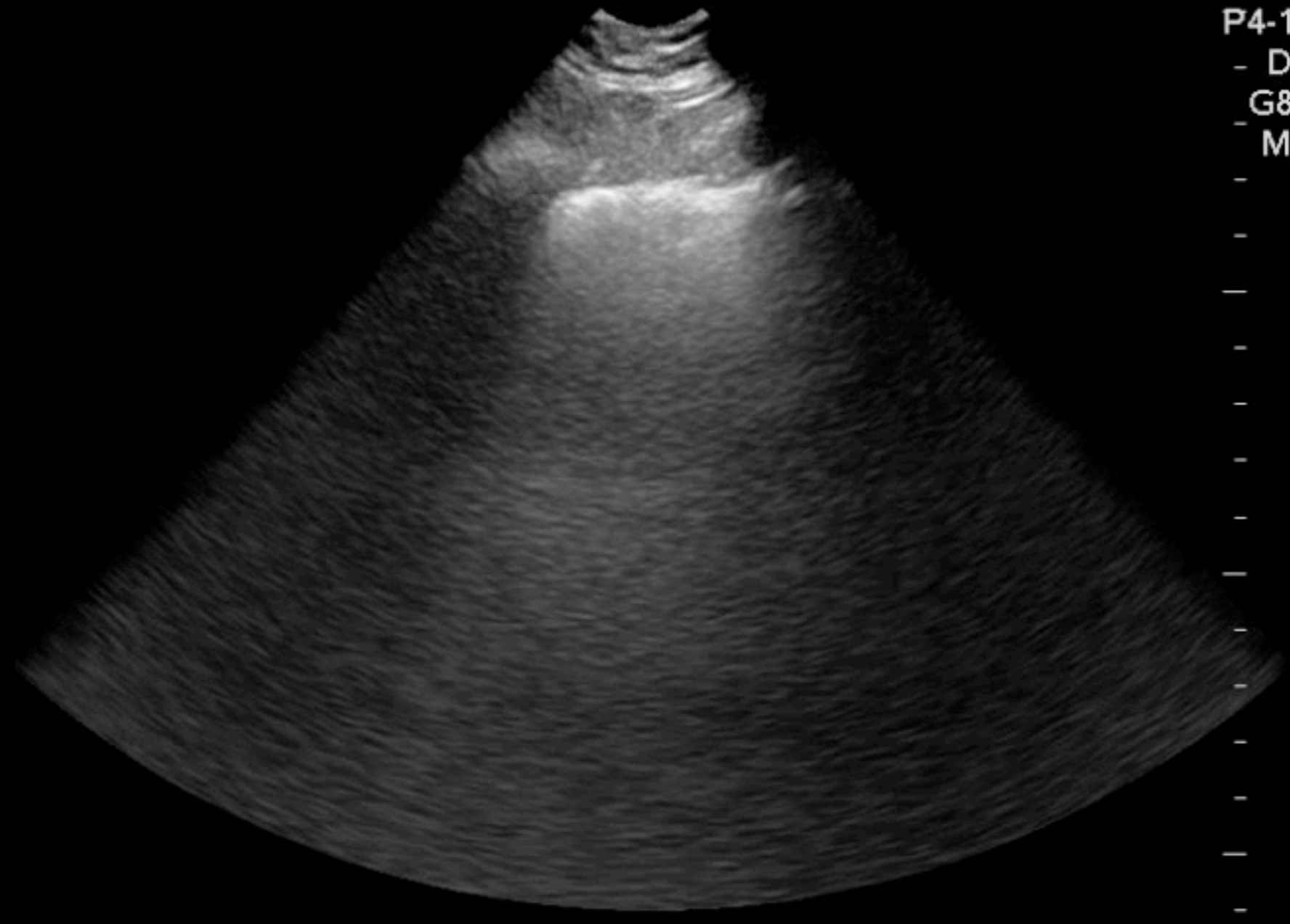
A-lines?

B-lines?

B-lines?

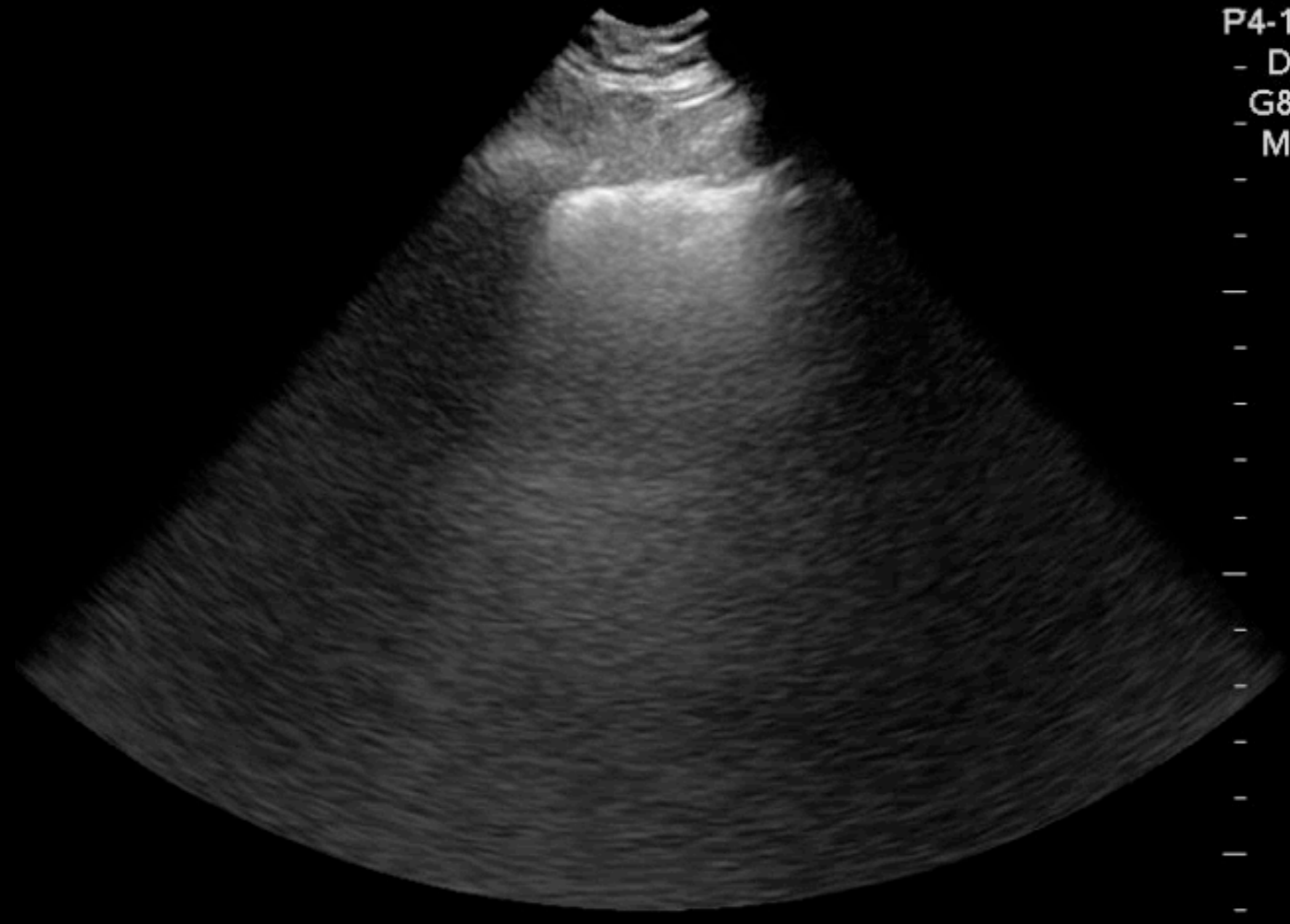
Z

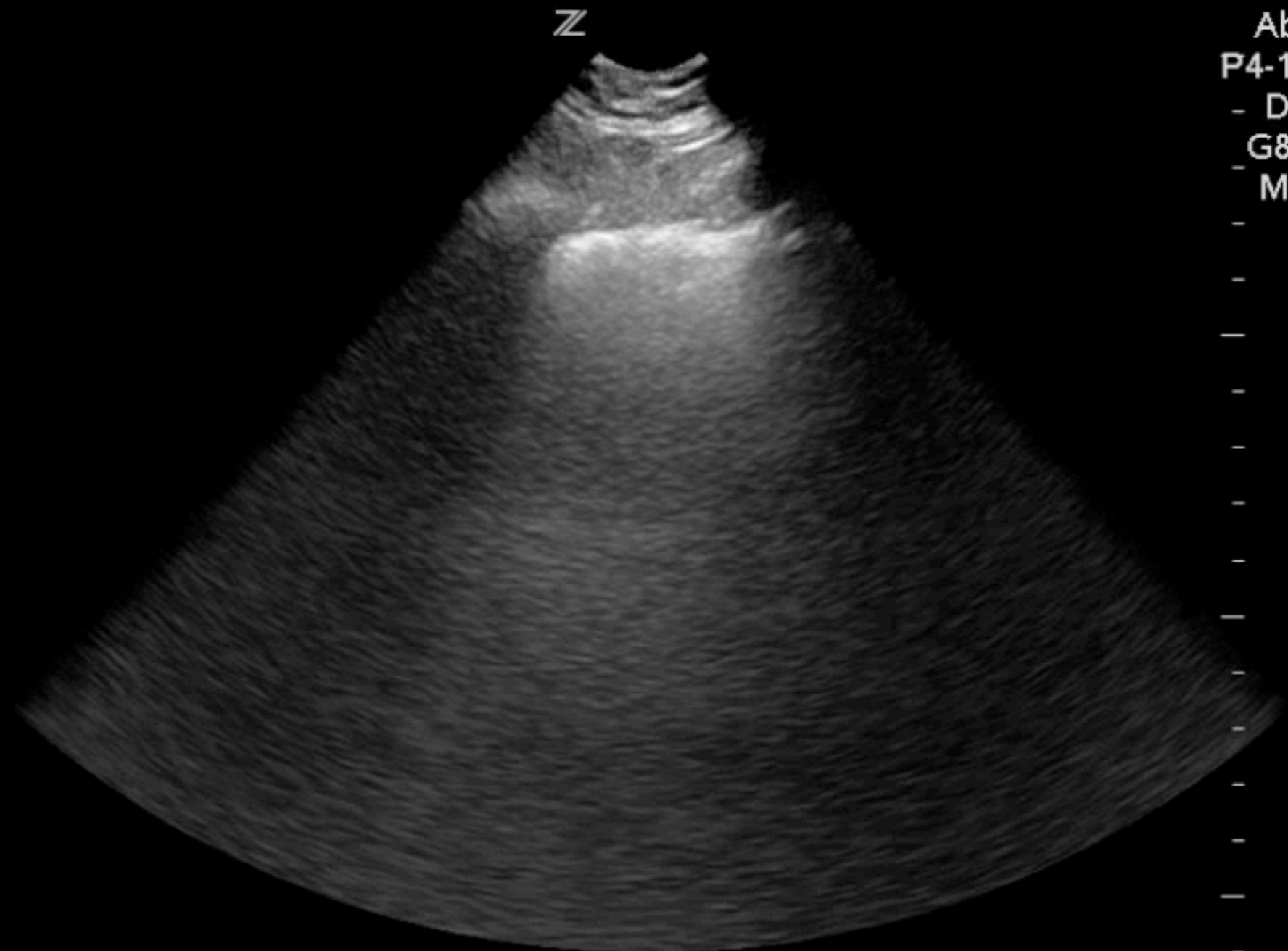
Abd/General
P4-1c/CH4MHz
- DR50/M2/P2
G86/E1/100%
- MI1.5 TIs0.6
- 16.0 cm
- 20/19 Hz
△ ZSI 0



Z

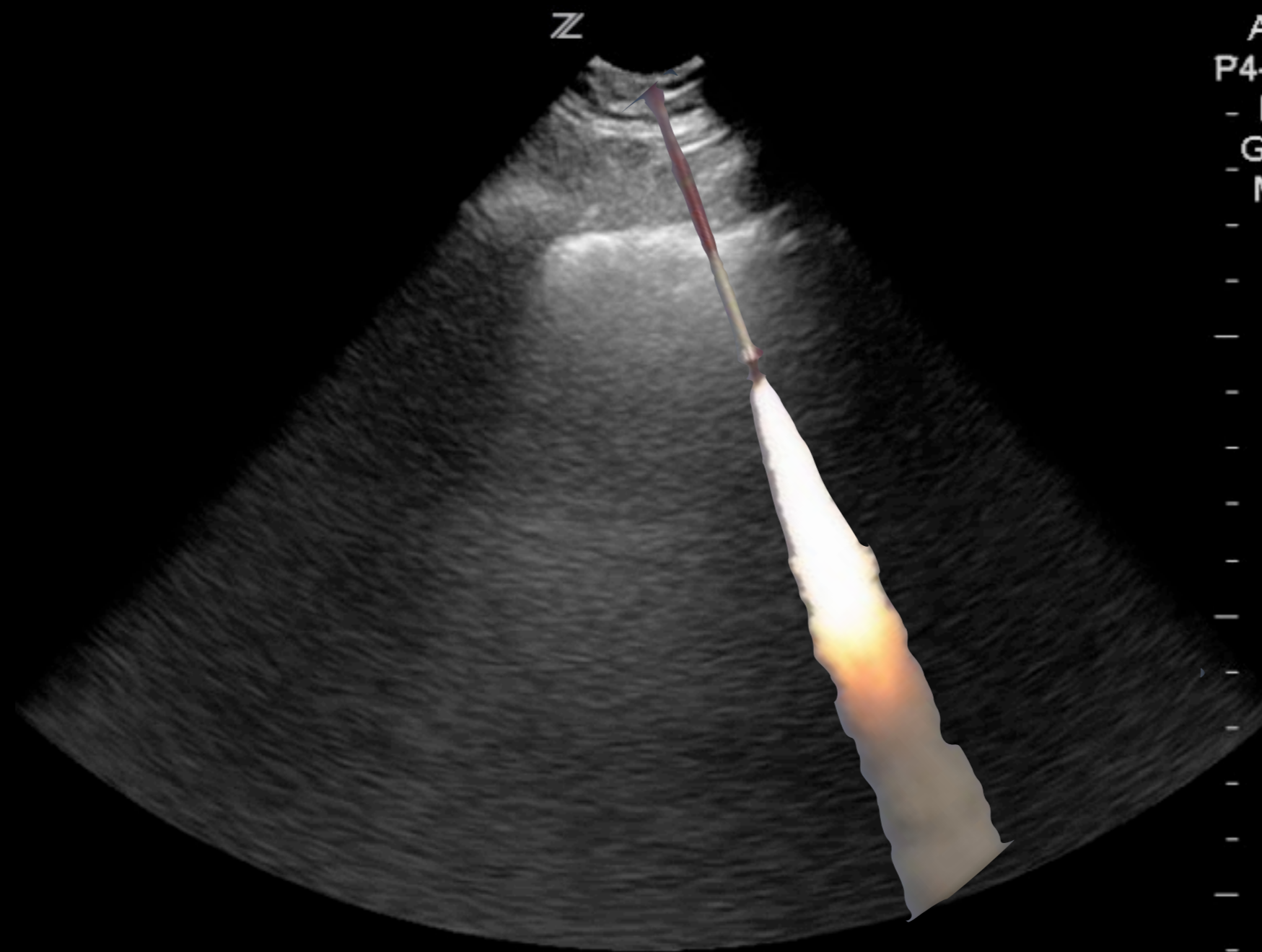
Abd/General
P4-1c/CH4MHz
- DR50/M2/P2
G86/E1/100%
- MI1.5 TIs0.6
- 16.0 cm
- 20/19 Hz
△ ZSI 0





Abd/General
P4-1c/CH4MHz
- DR50/M2/P2
G86/E1/100%
- MI1.5 TIs0.6
- 16.0 cm
- 20/19 Hz
△ ZSI 0

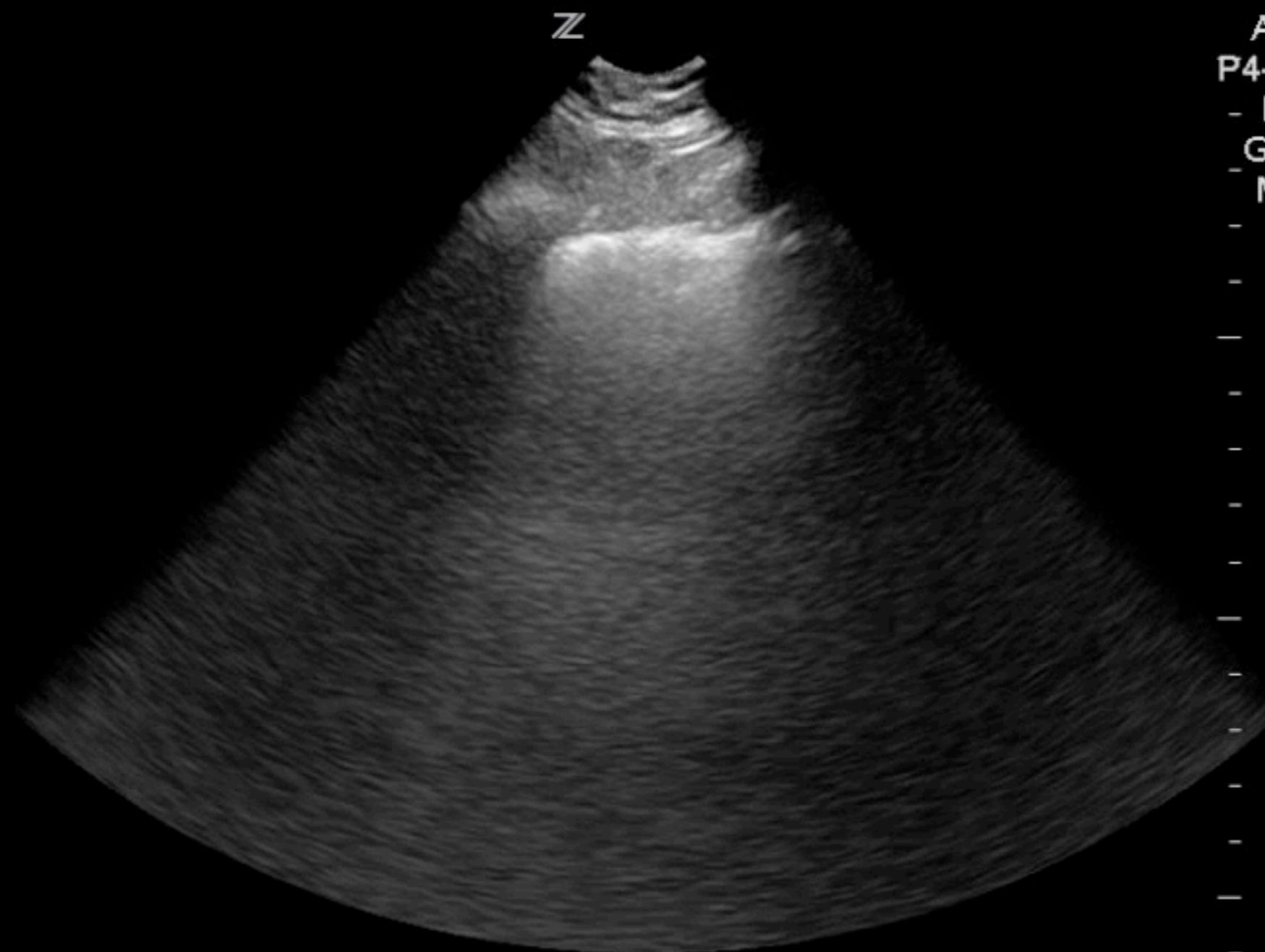
B-lines



Abd/General
P4-1c/CH4MHz
- DR50/M2/P2
G86/E1/100%
- MI1.5 TIs0.6
- 16.0 cm
- 20/19 Hz
△ ZSI 0

B-lines

Lung rockets or searchlights

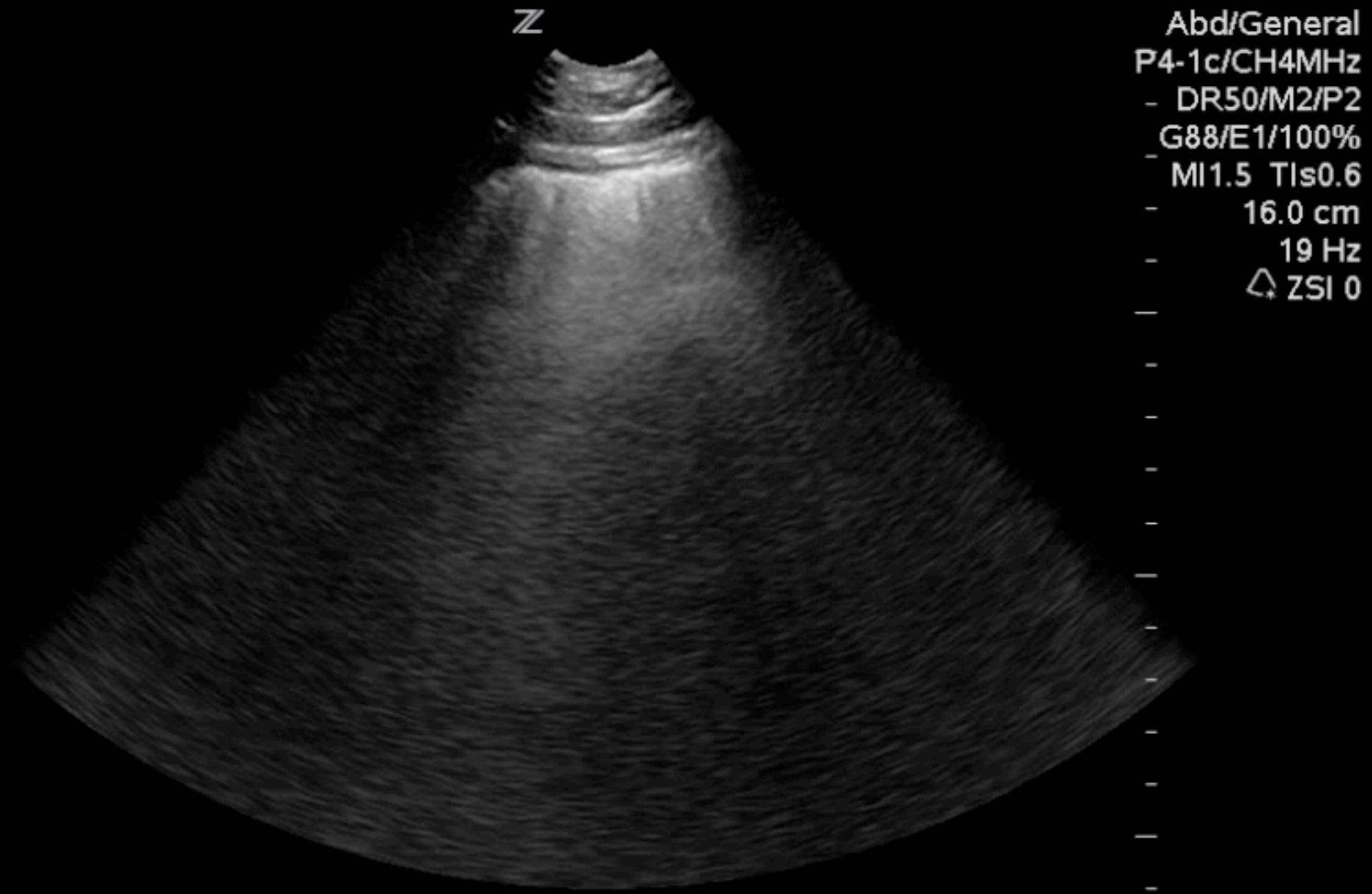


Abd/General
P4-1c/CH4MHz
- DR50/M2/P2
G86/E1/100%
- MI1.5 TIs0.6
- 16.0 cm
- 20/19 Hz
△ ZSI 0

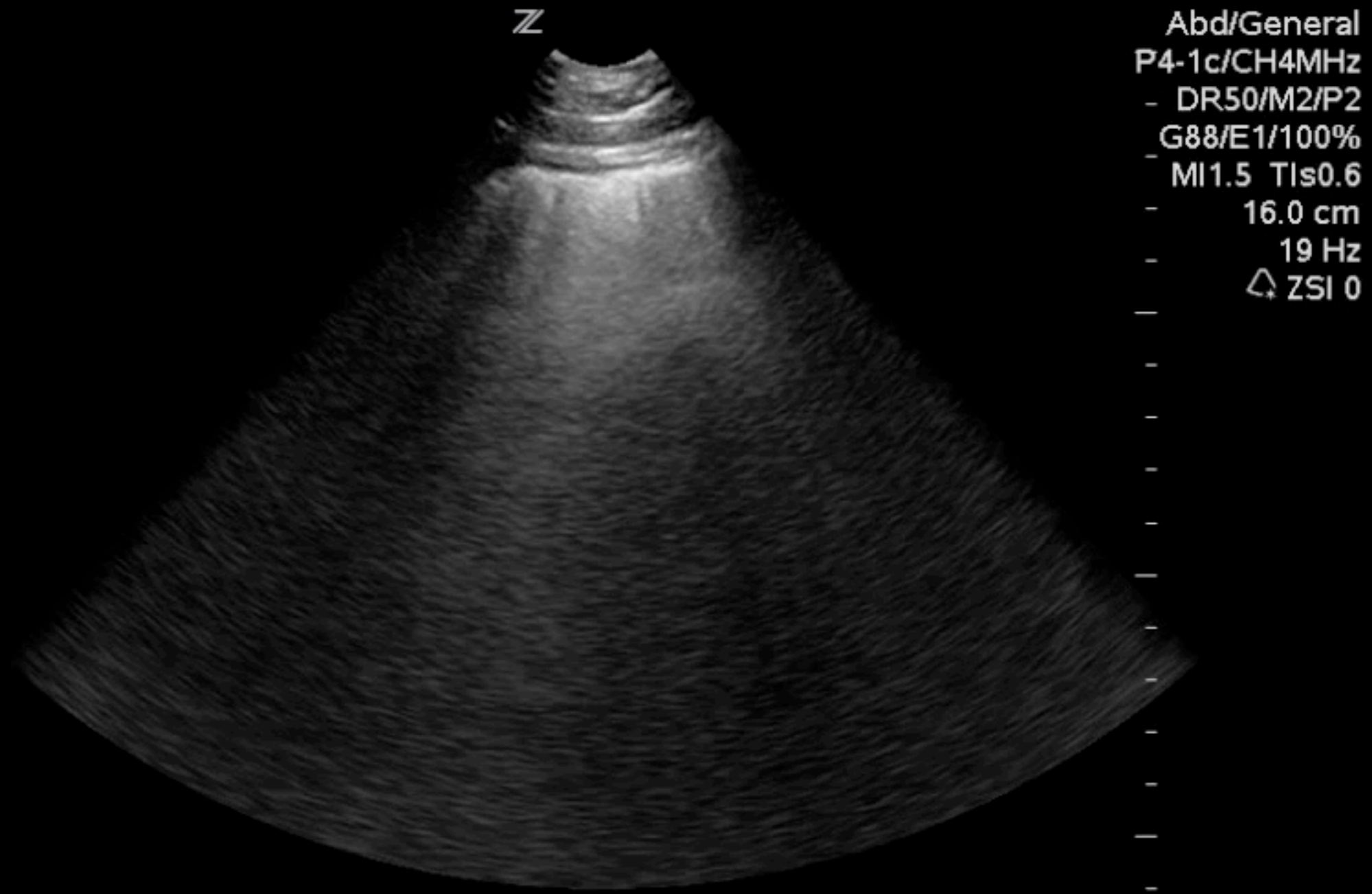
B-lines

Lung rockets or searchlights

B-lines

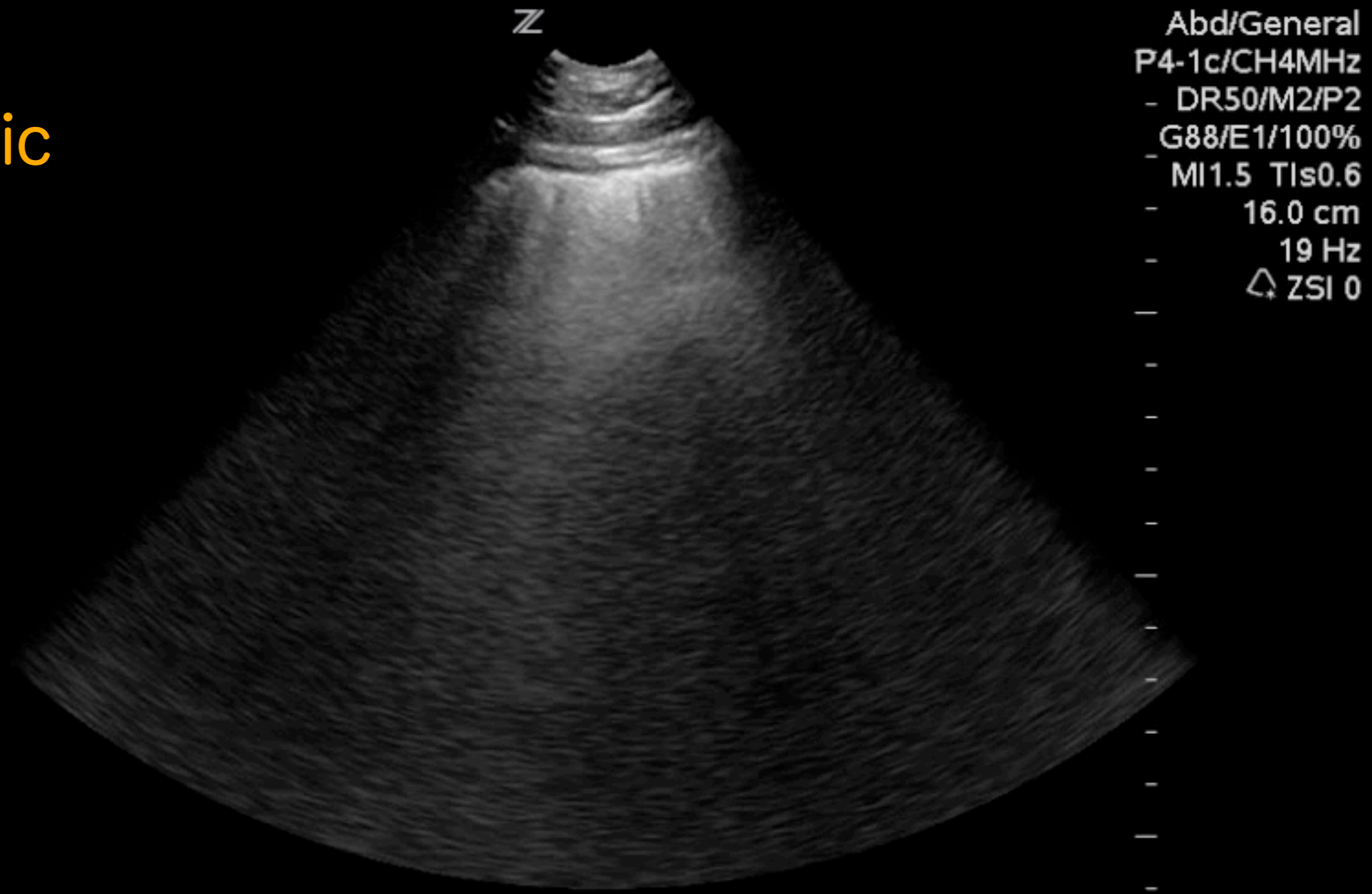


B-lines



B-lines

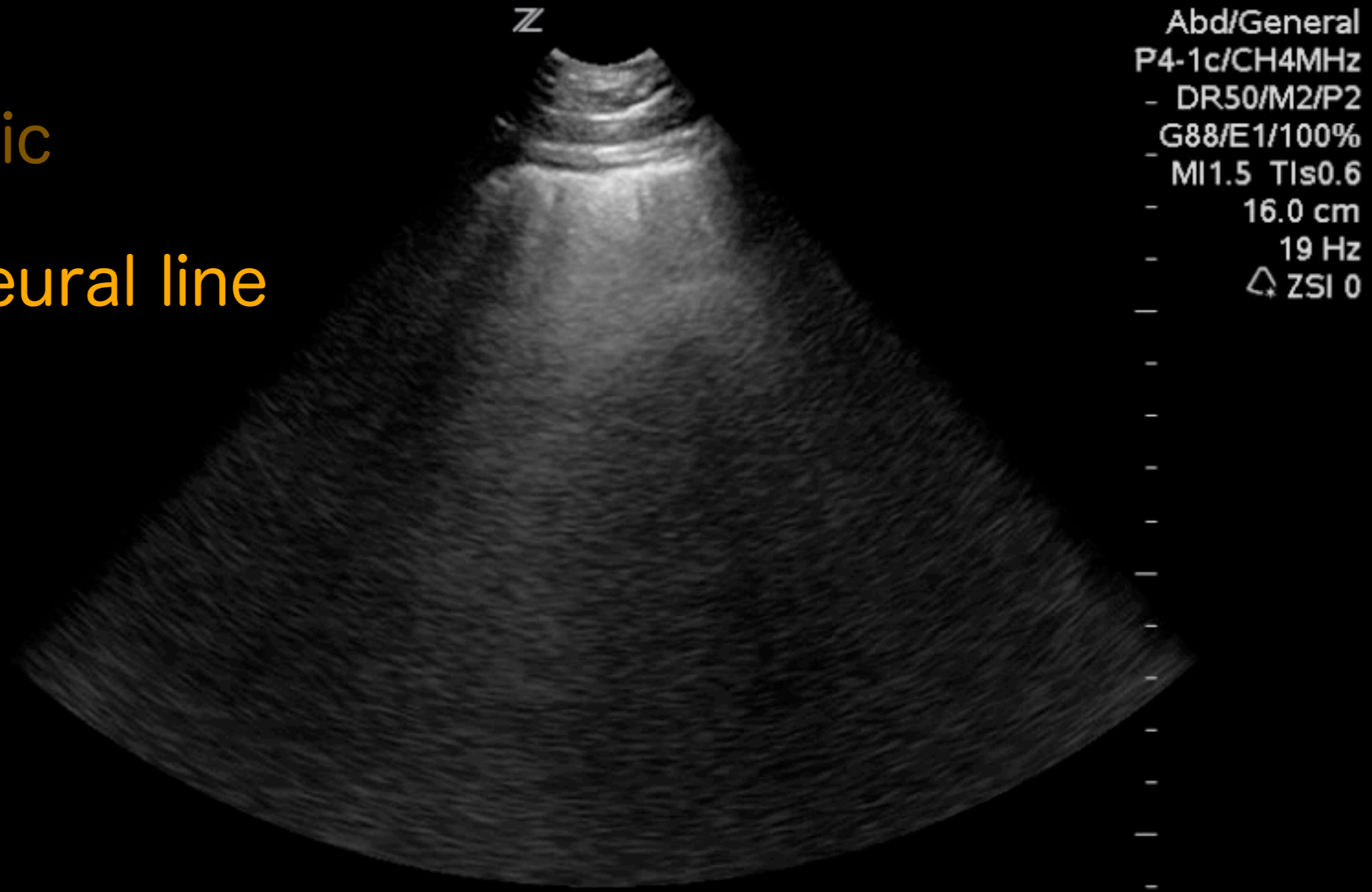
Hyperchoic



B-lines

Hyperechoic

Start at pleural line

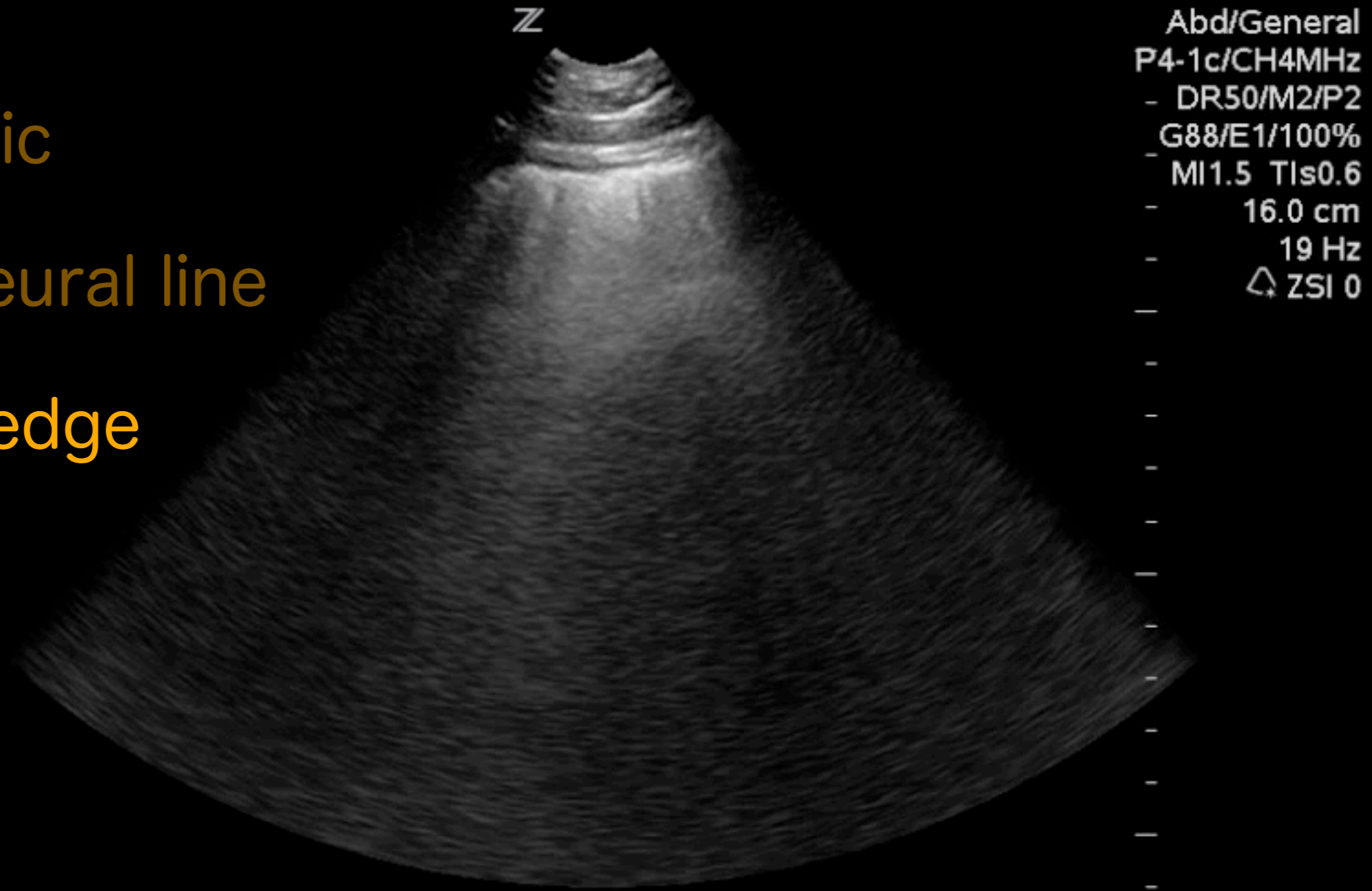


B-lines

Hyperechoic

Start at pleural line

Extend to edge



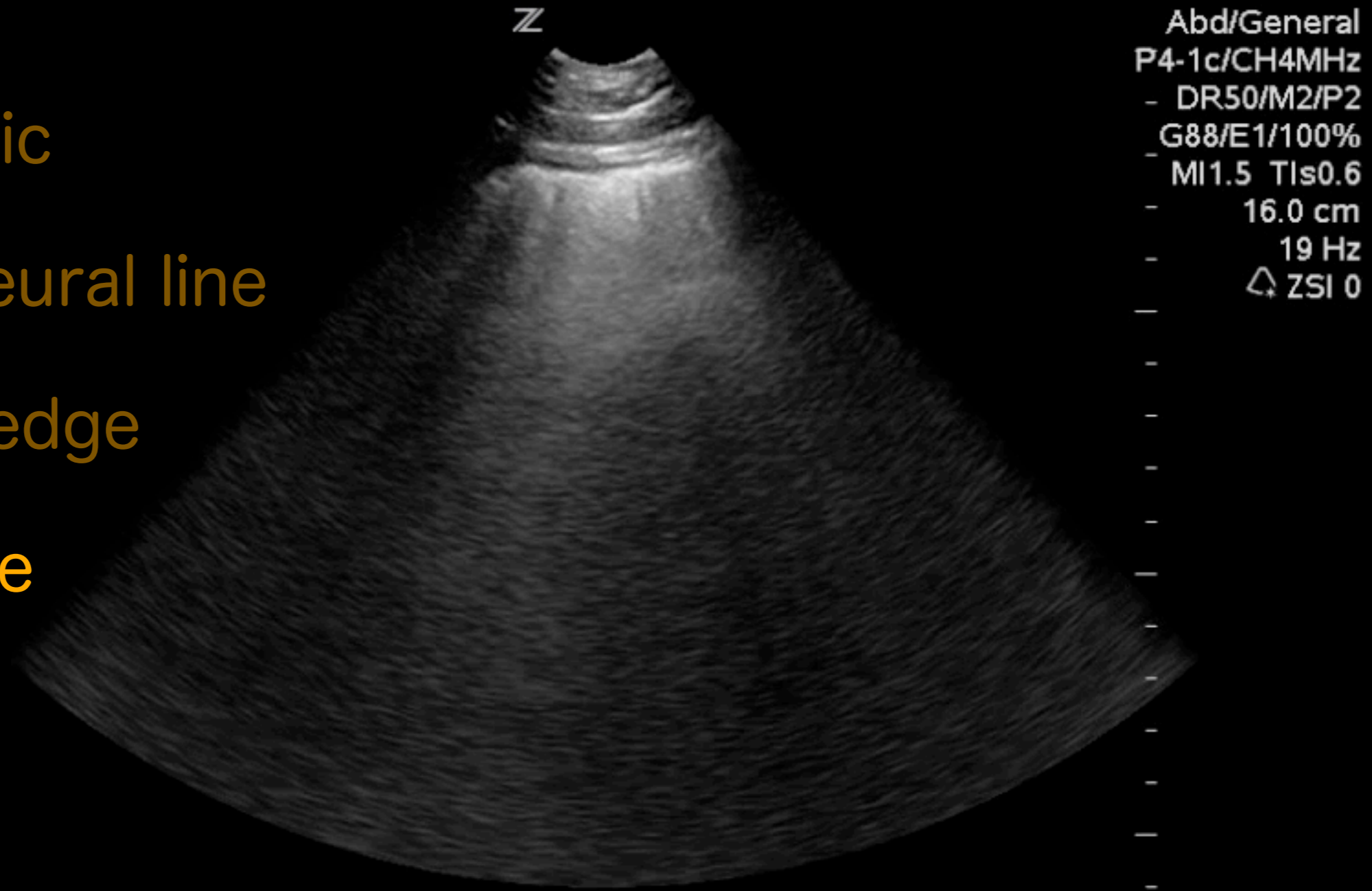
B-lines

Hyperechoic

Start at pleural line

Extend to edge

Do not fade



B-lines

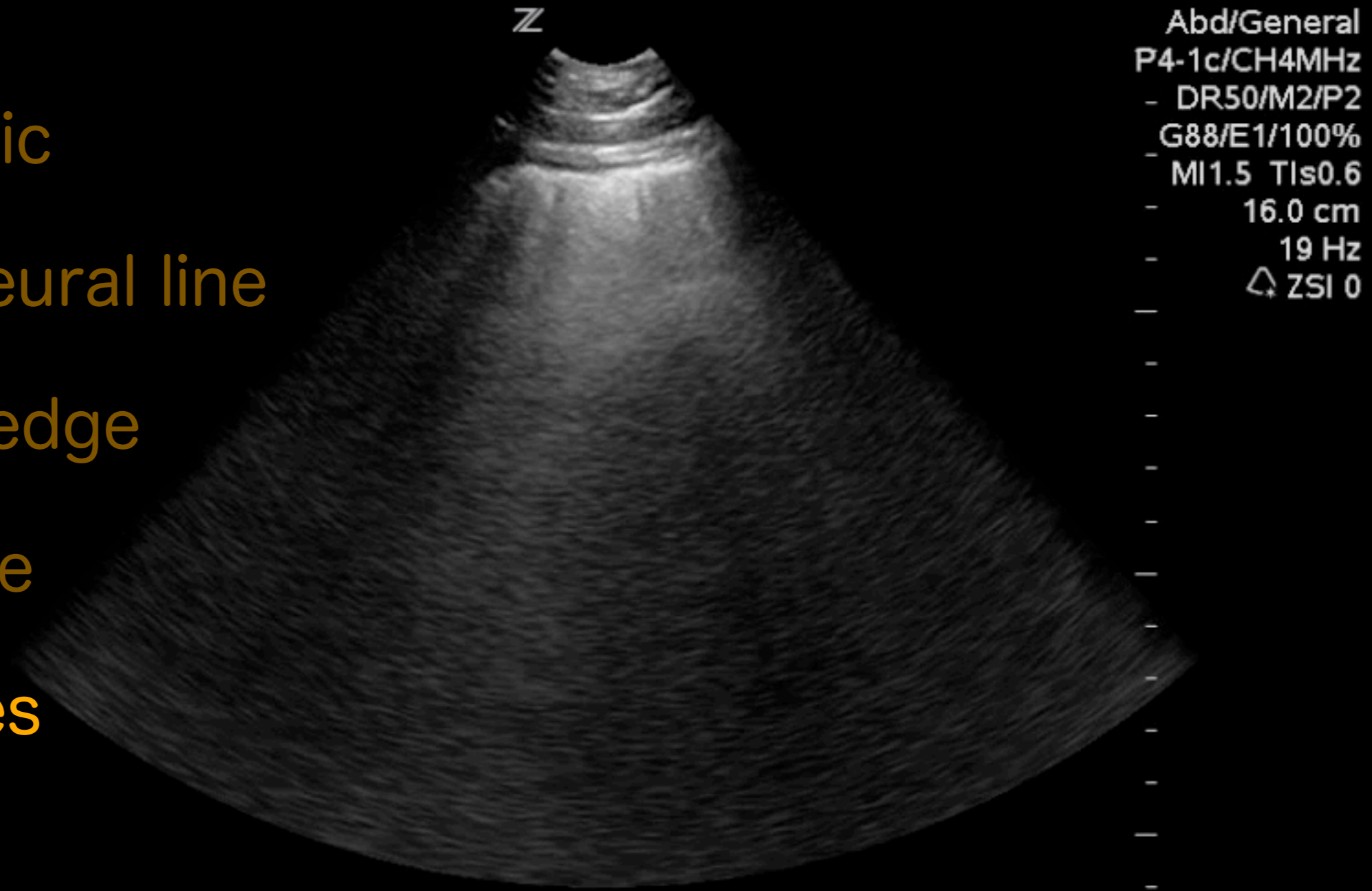
Hyperechoic

Start at pleural line

Extend to edge

Do not fade

Hide A-lines



B-lines

Hyperechoic

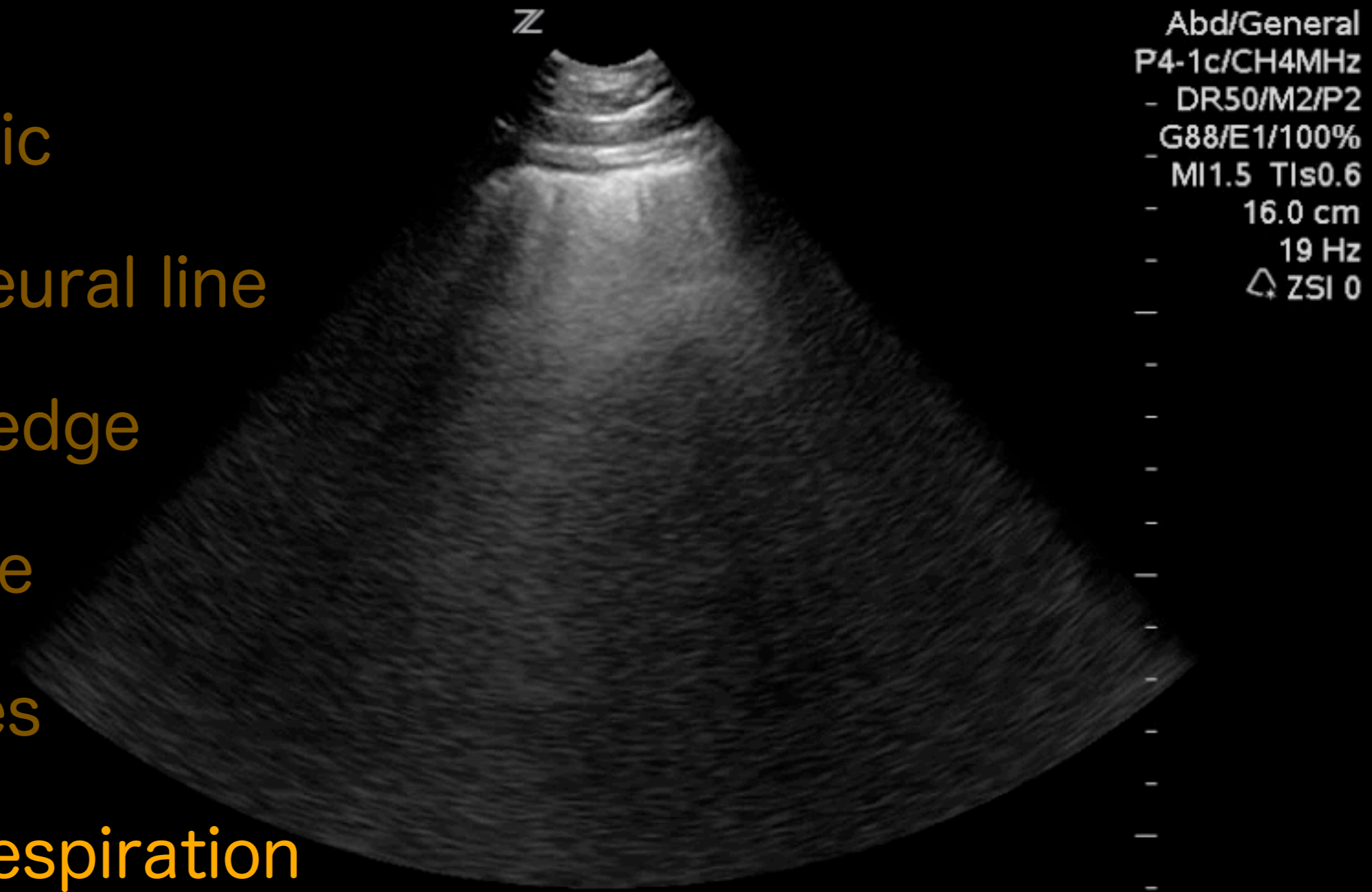
Start at pleural line

Extend to edge

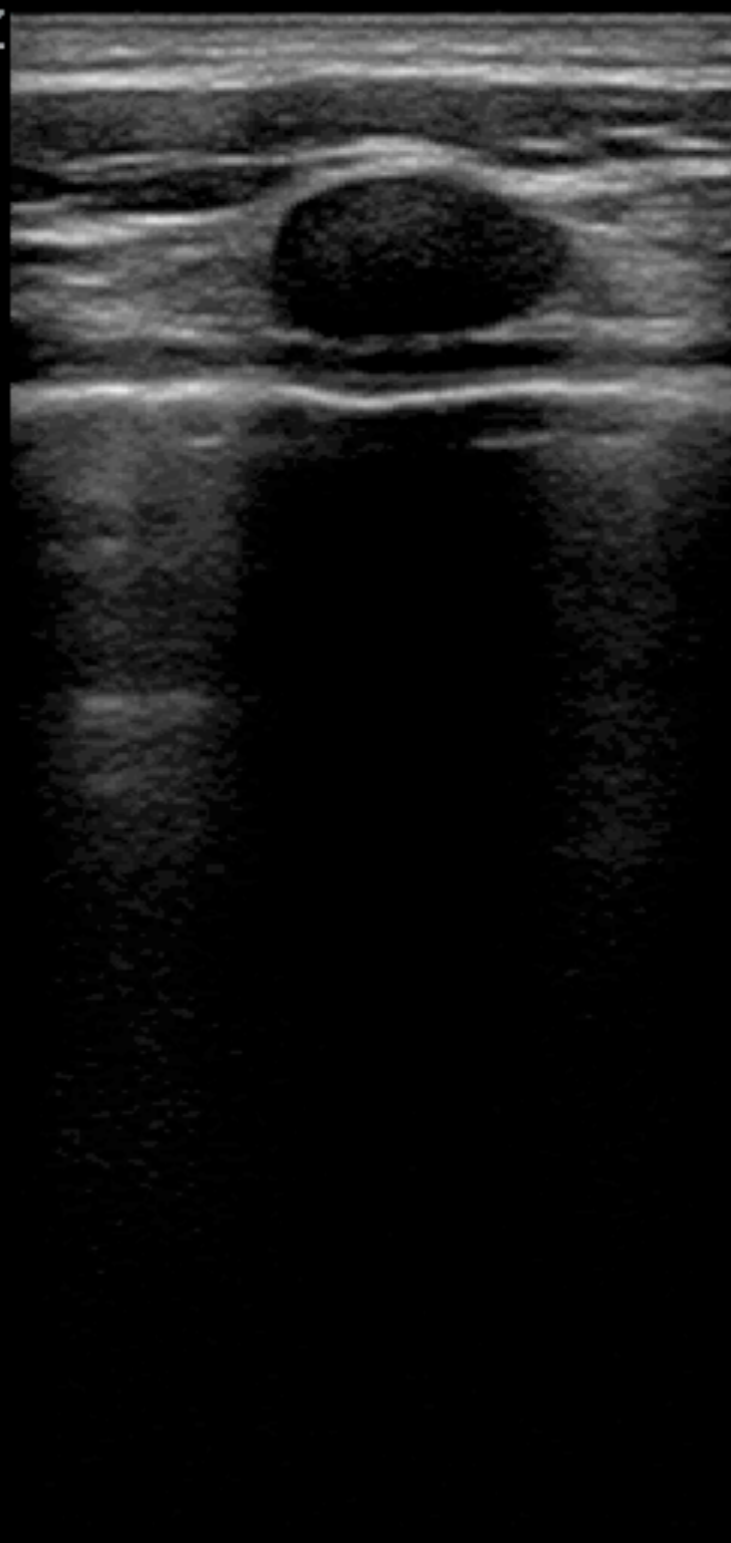
Do not fade

Hide A-lines

Move w/ respiration

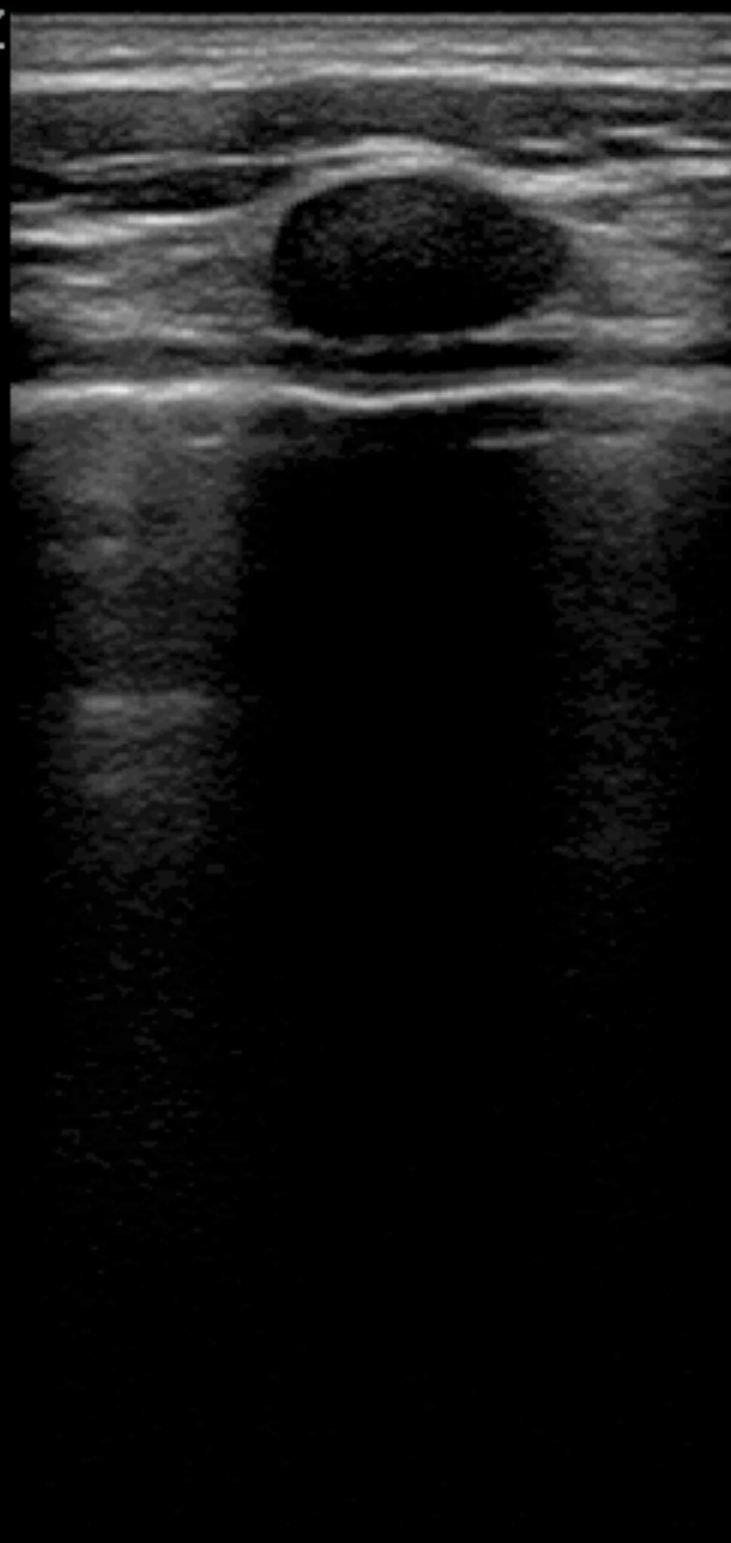


Z

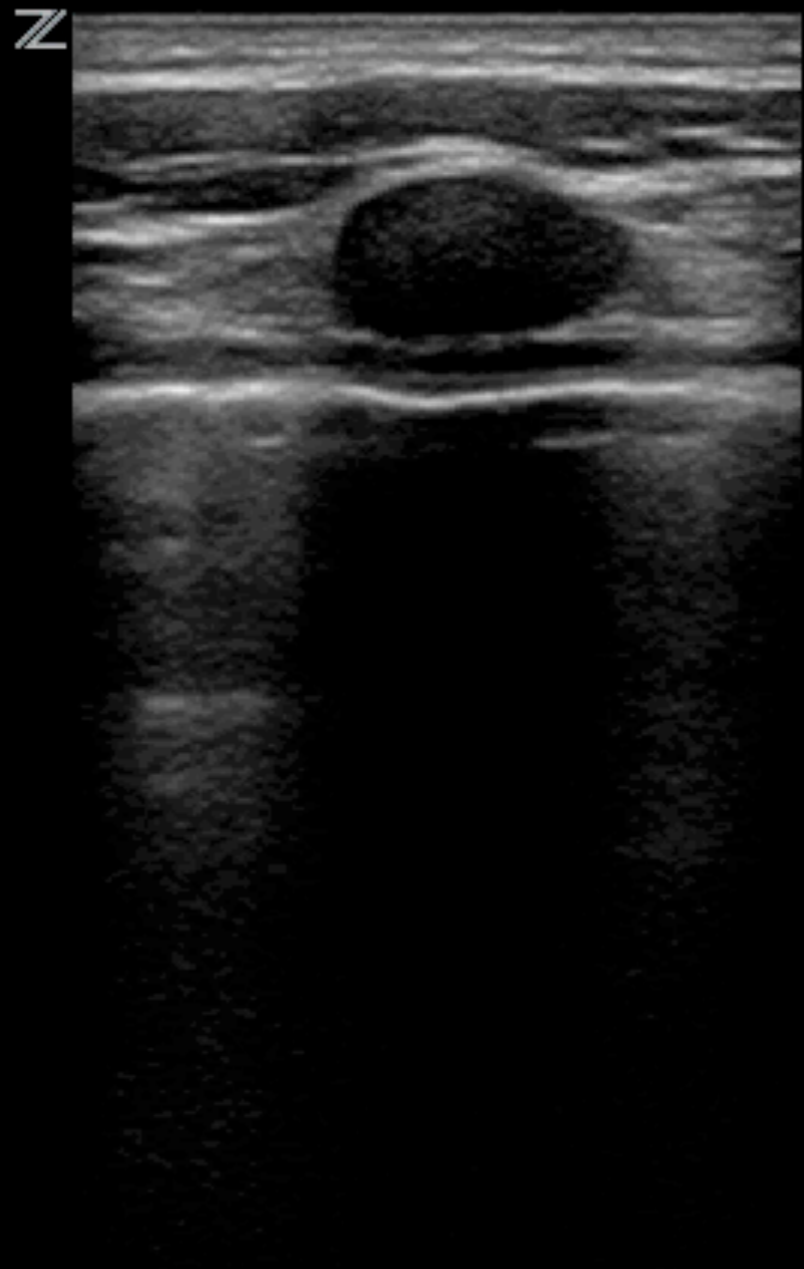


Vasc/Carotid
L8-3/CH7MHz
DR70/M3/P2
G94/E2/100%
MI1.5 TIs0.2
8.0 cm
13 Hz
ZSI 0

Z

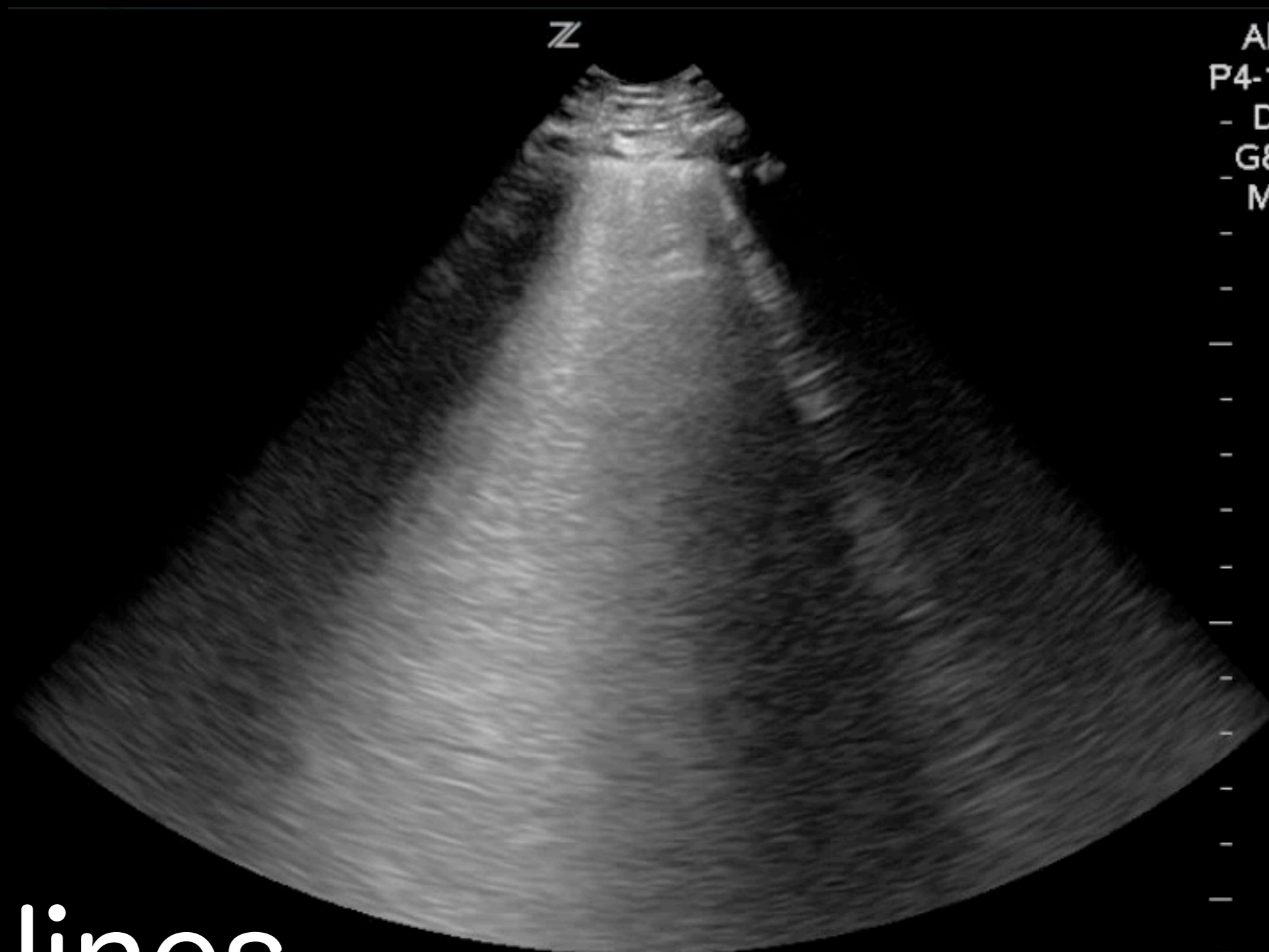


Vasc/Carotid
L8-3/CH7MHz
DR70/M3/P2
G94/E2/100%
MI1.5 TIs0.2
8.0 cm
13 Hz
ZSI 0



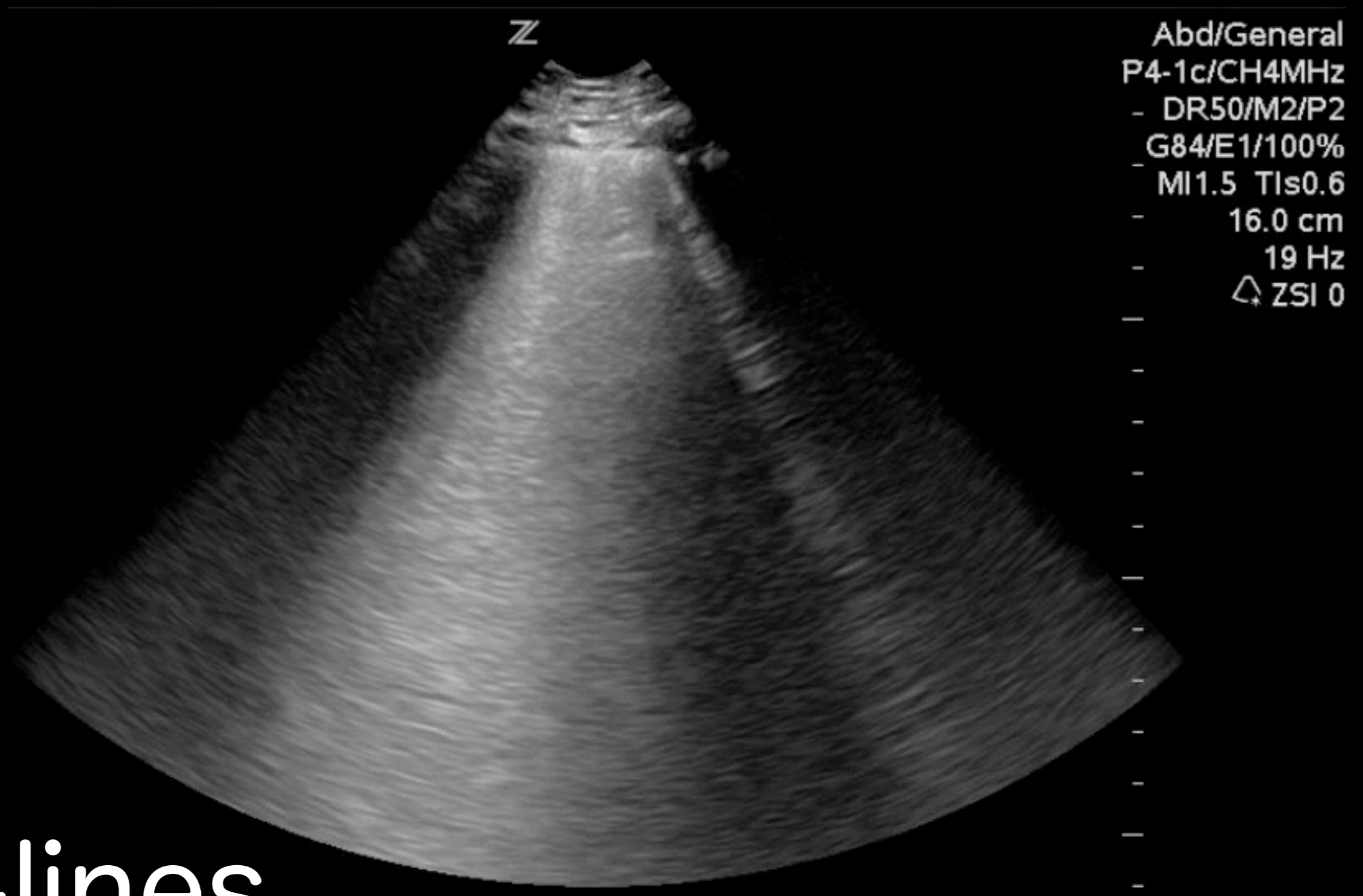V asc/Carotid
L8-3/CH7MHz
DR70/M3/P2
G94/E2/100%
MI1.5 TIs0.2
8.0 cm
13 Hz
ZSI 0

Pitfall: Comet tails
Normal finding



Abd/General
P4-1c/CH4MHz
- DR50/M2/P2
- G84/E1/100%
- MI1.5 TIs0.6
- 16.0 cm
- 19 Hz
△ ZSI 0

B-lines




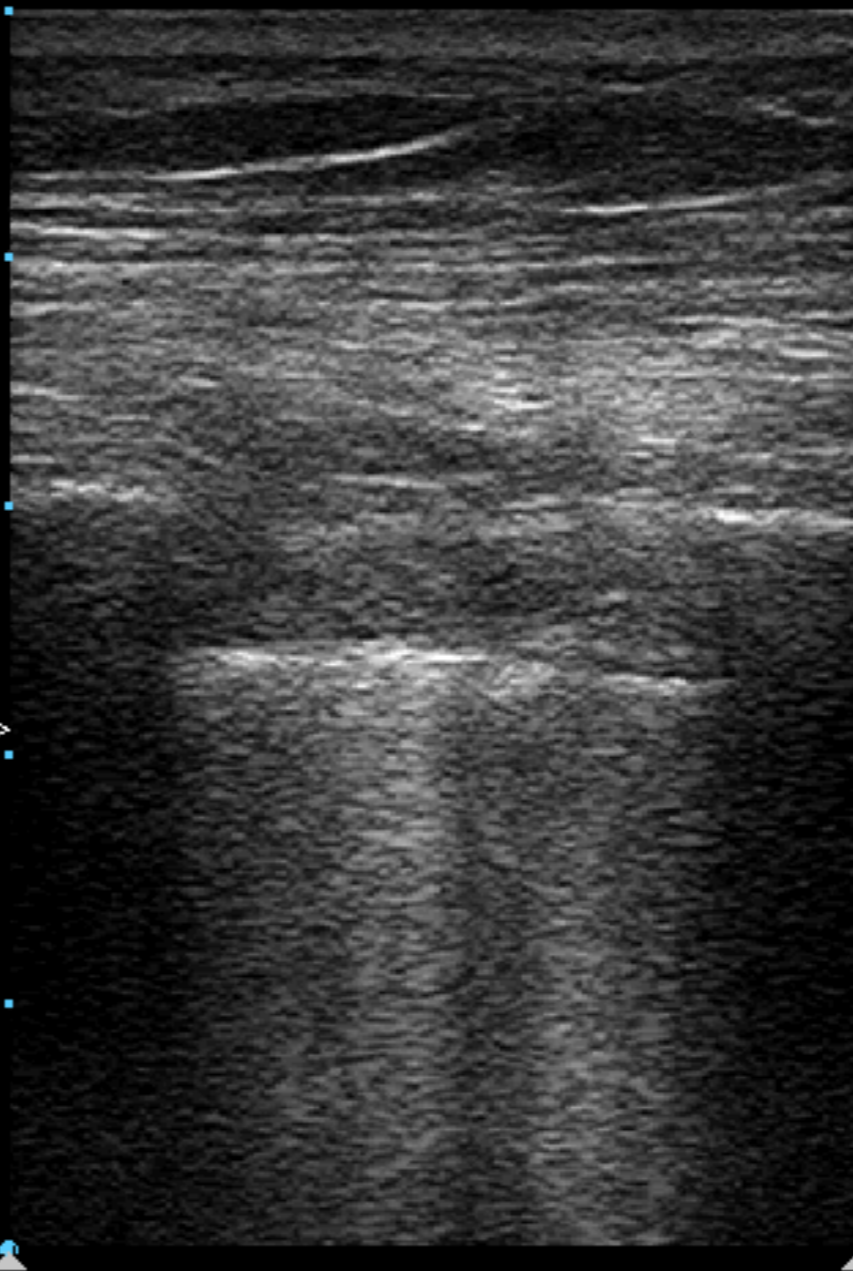
B-lines

Can sometimes see concomitant A-lines

ED ECHO
L12-3
43Hz
5cm

2D
H1
Gn 52
232dB/C5
D/2/0

P



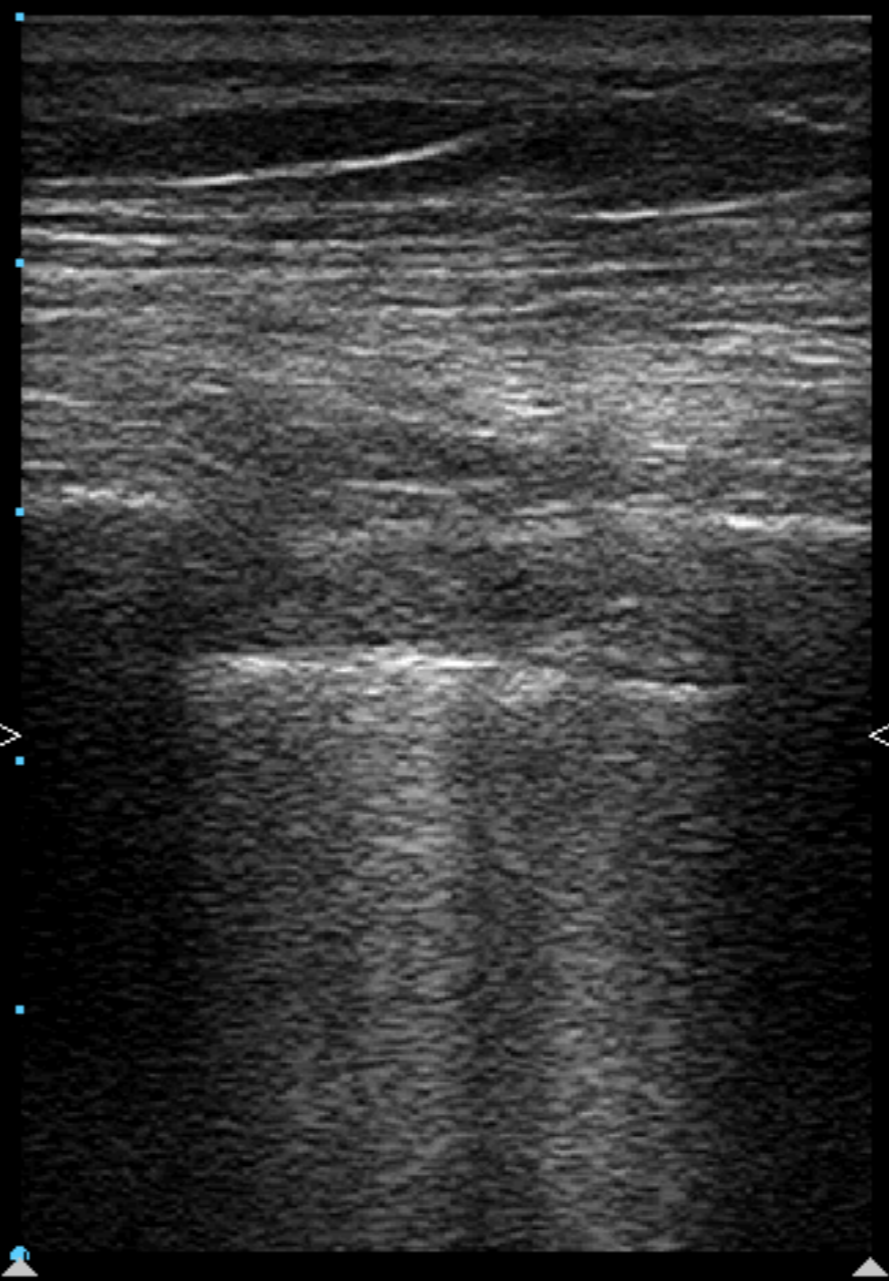
G
5.0 10.0

B-lines

ED ECHO
L12-3
43Hz
5cm

2D
H1
Gn 52
232dB/C5
D/2/0

P

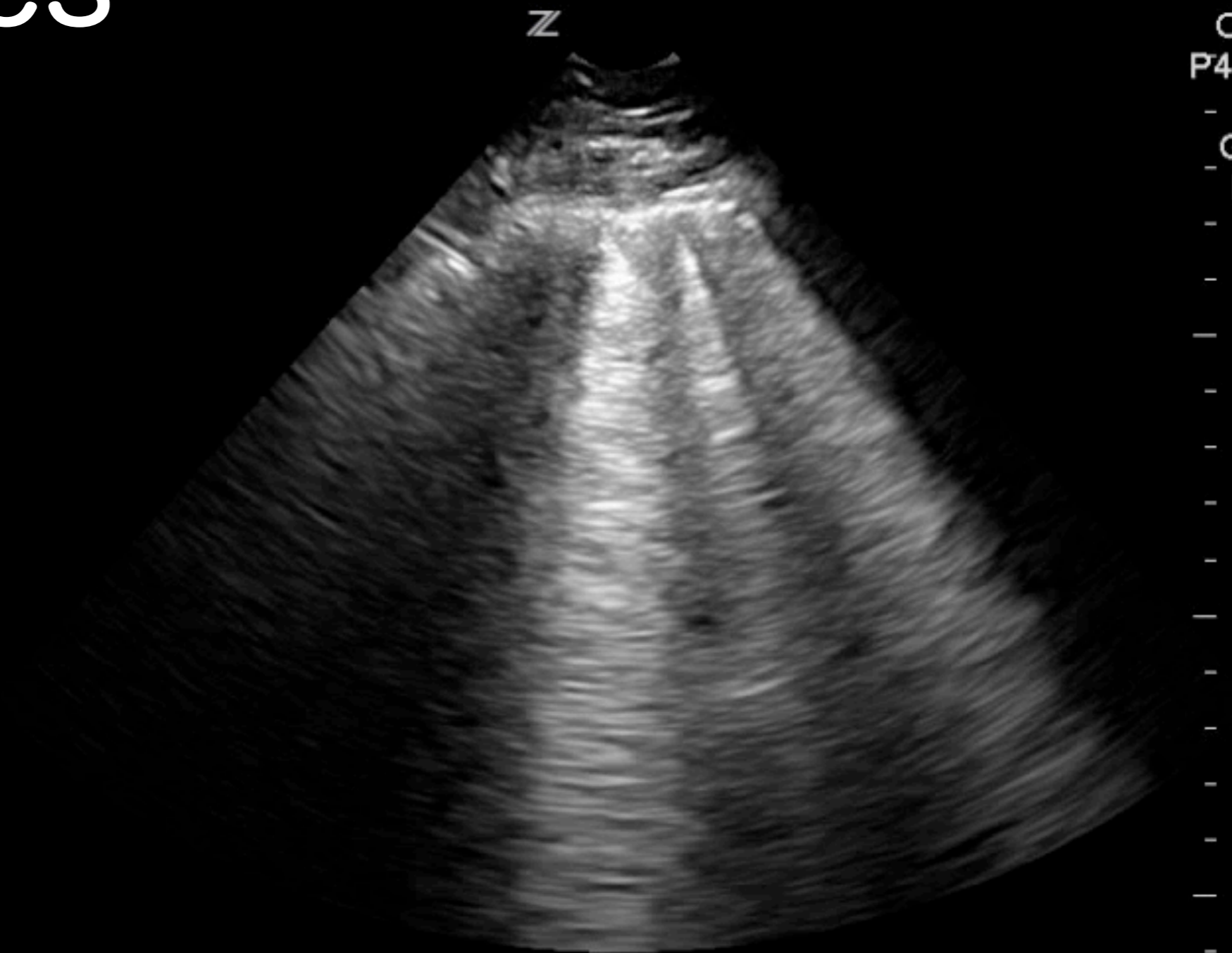


G
5.0 10.0

B-lines

Low frequency probe preferable

B-lines



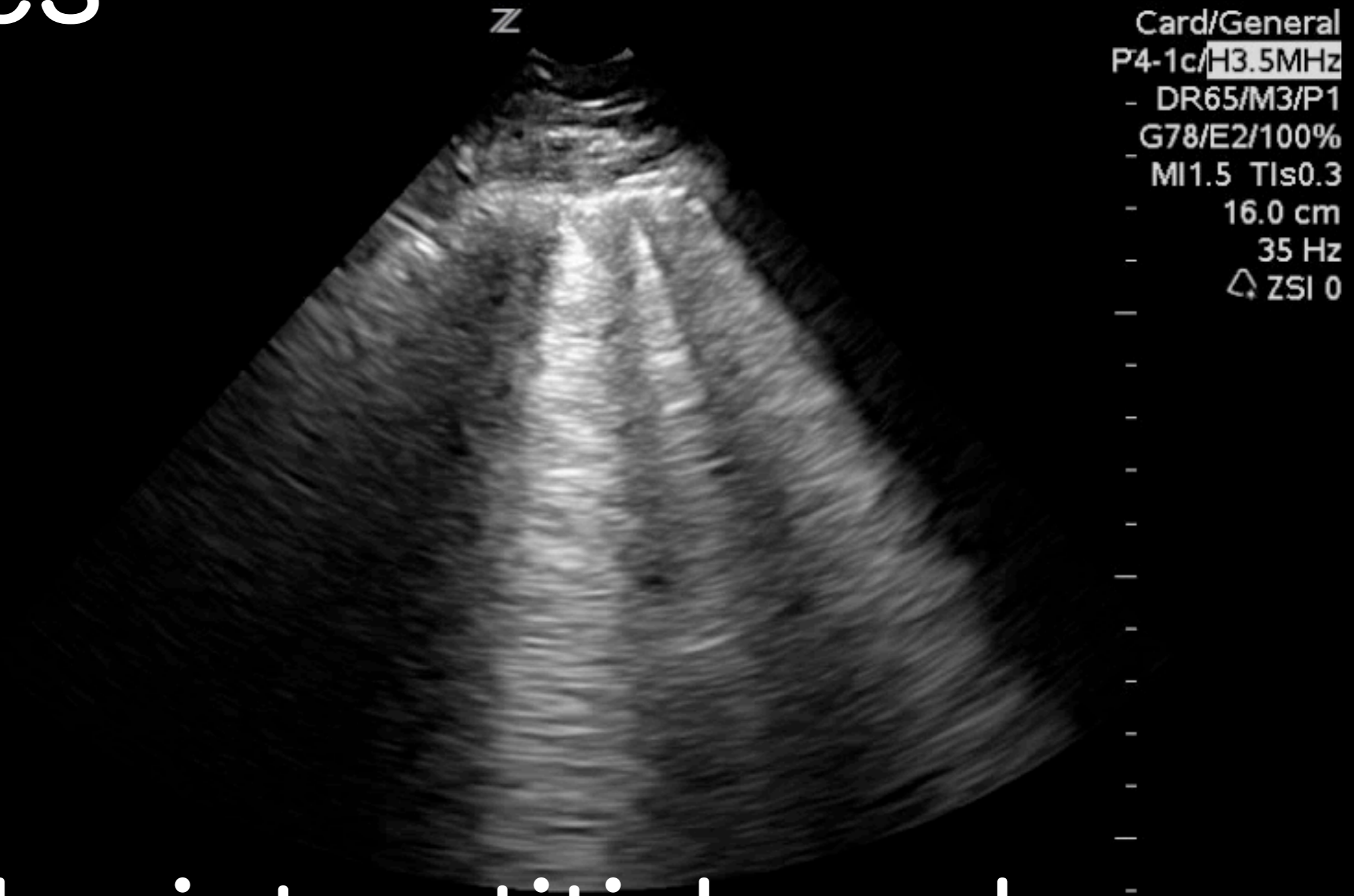
Card/General
P4-1c/H3.5MHz
- DR65/M3/P1
G78/E2/100%
- MI1.5 TIs0.3
- 16.0 cm
- 35 Hz
△ ZSI 0

B-lines



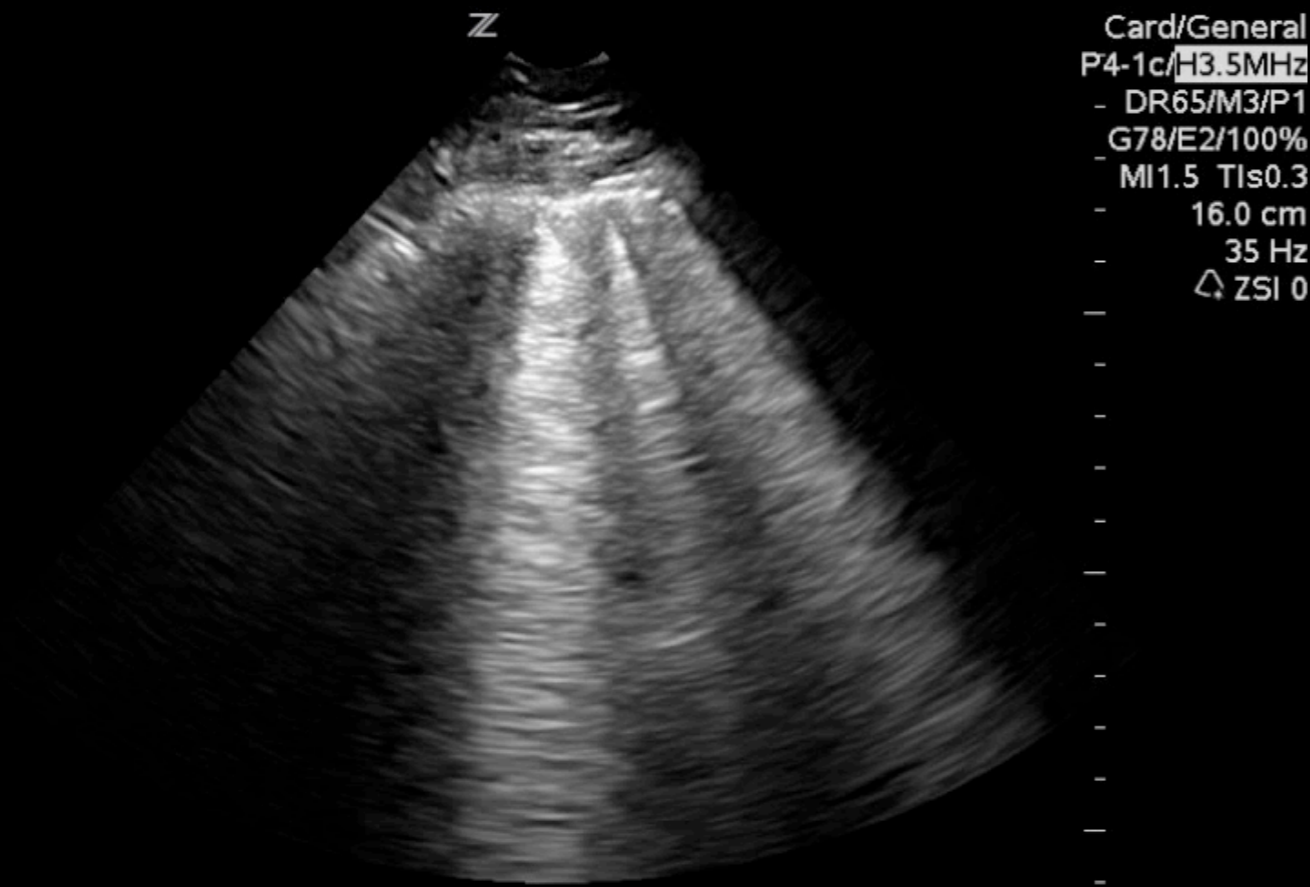
Card/General
P4-1c/H3.5MHz
- DR65/M3/P1
G78/E2/100%
- MI1.5 TIs0.3
- 16.0 cm
- 35 Hz
△ ZSI 0

B-lines



Alveolar-interstitial syndrome
I.e., fluid or thickening present

B-lines



Pulmonary edema

Pneumonia/ARDS

SCD Acute Chest

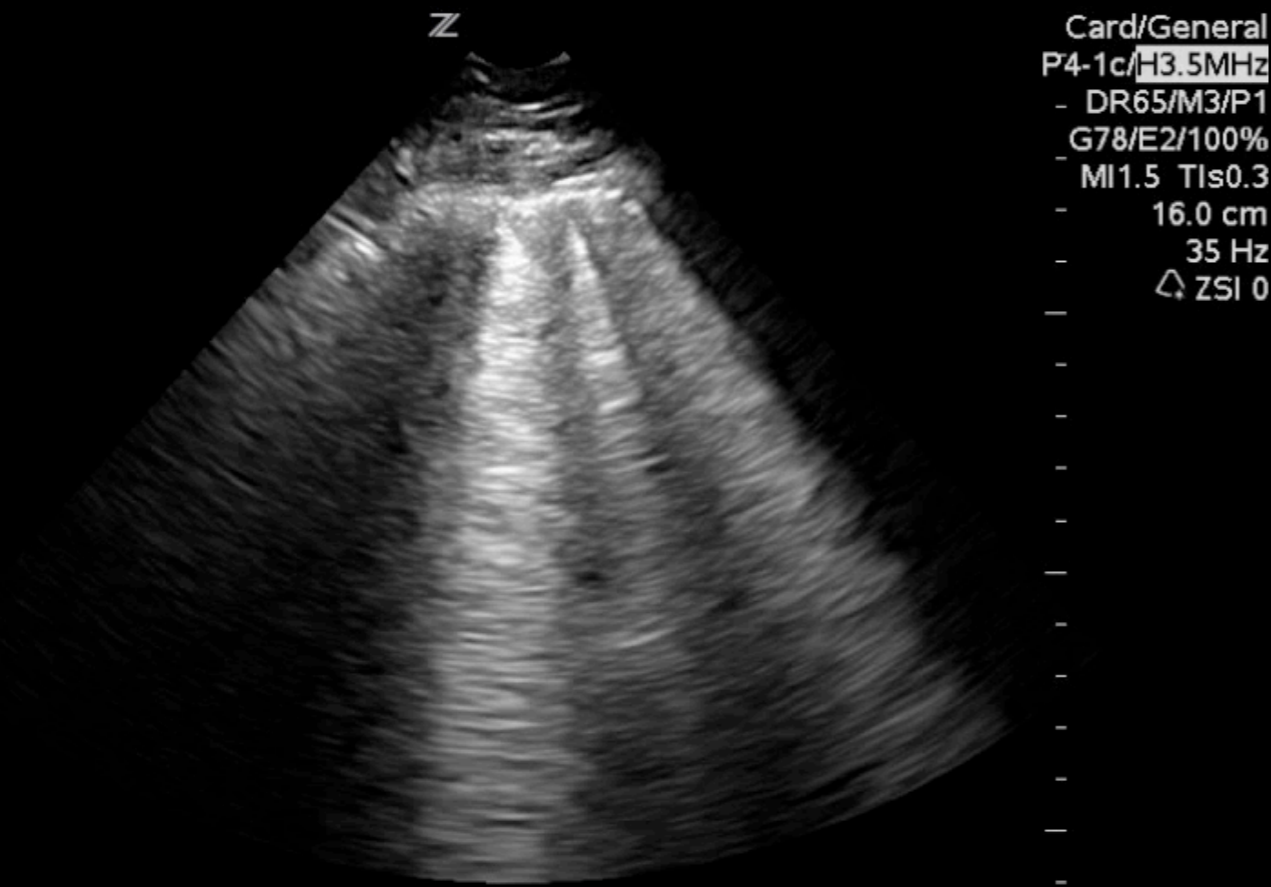
Lung contusion

Pulmonary fibrosis

Alveolar-interstitial syndrome

I.e., fluid or thickening present

B-lines



Pulmonary edema

Pneumonia/ARDS

SCD Acute Chest

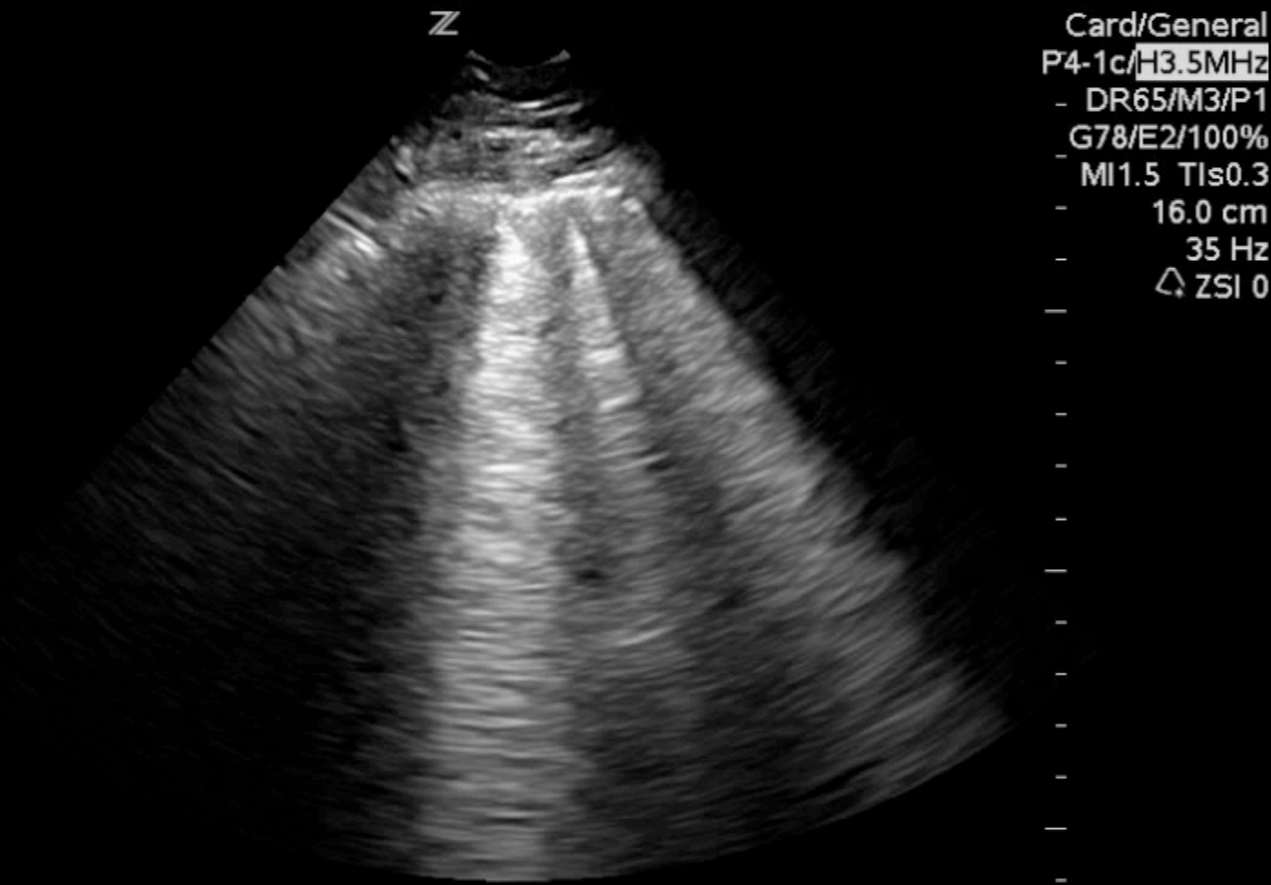
Lung contusion

Pulmonary fibrosis

Alveolar-interstitial syndrome

I.e., fluid or thickening present

B-lines



Pulmonary edema

Pneumonia/ARDS

SCD Acute Chest

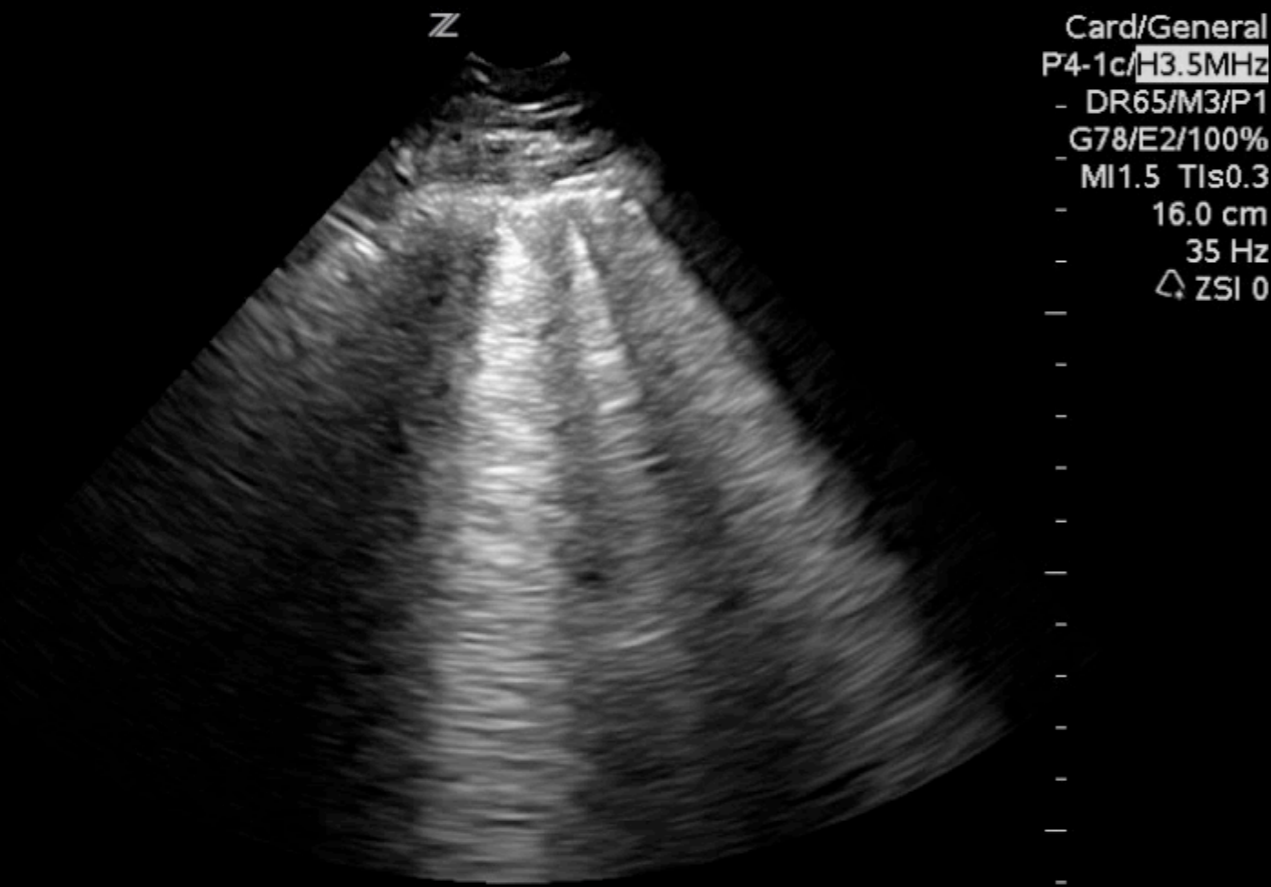
Lung contusion

Pulmonary fibrosis

Alveolar-interstitial syndrome

I.e., fluid or thickening present

B-lines



Pulmonary edema

Pneumonia/ARDS

SCD Acute Chest

Lung contusion

Pulmonary fibrosis

Alveolar-interstitial syndrome

I.e., fluid or thickening present

B-lines



Pulmonary edema

Pneumonia/ARDS

SCD Acute Chest

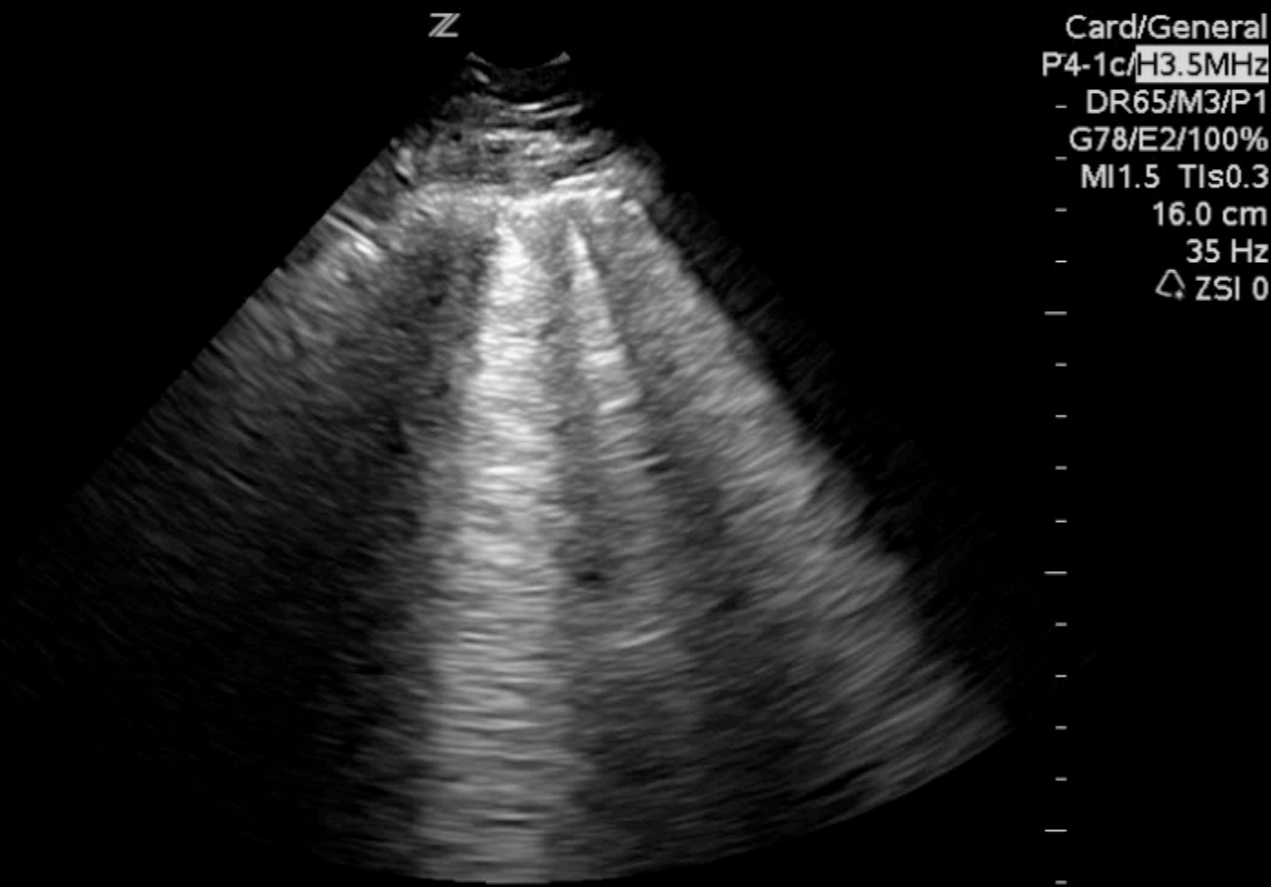
Lung contusion

Pulmonary fibrosis

Alveolar-interstitial syndrome

I.e., fluid or thickening present

B-lines



Pulmonary edema

Pneumonia/ARDS

SCD Acute Chest

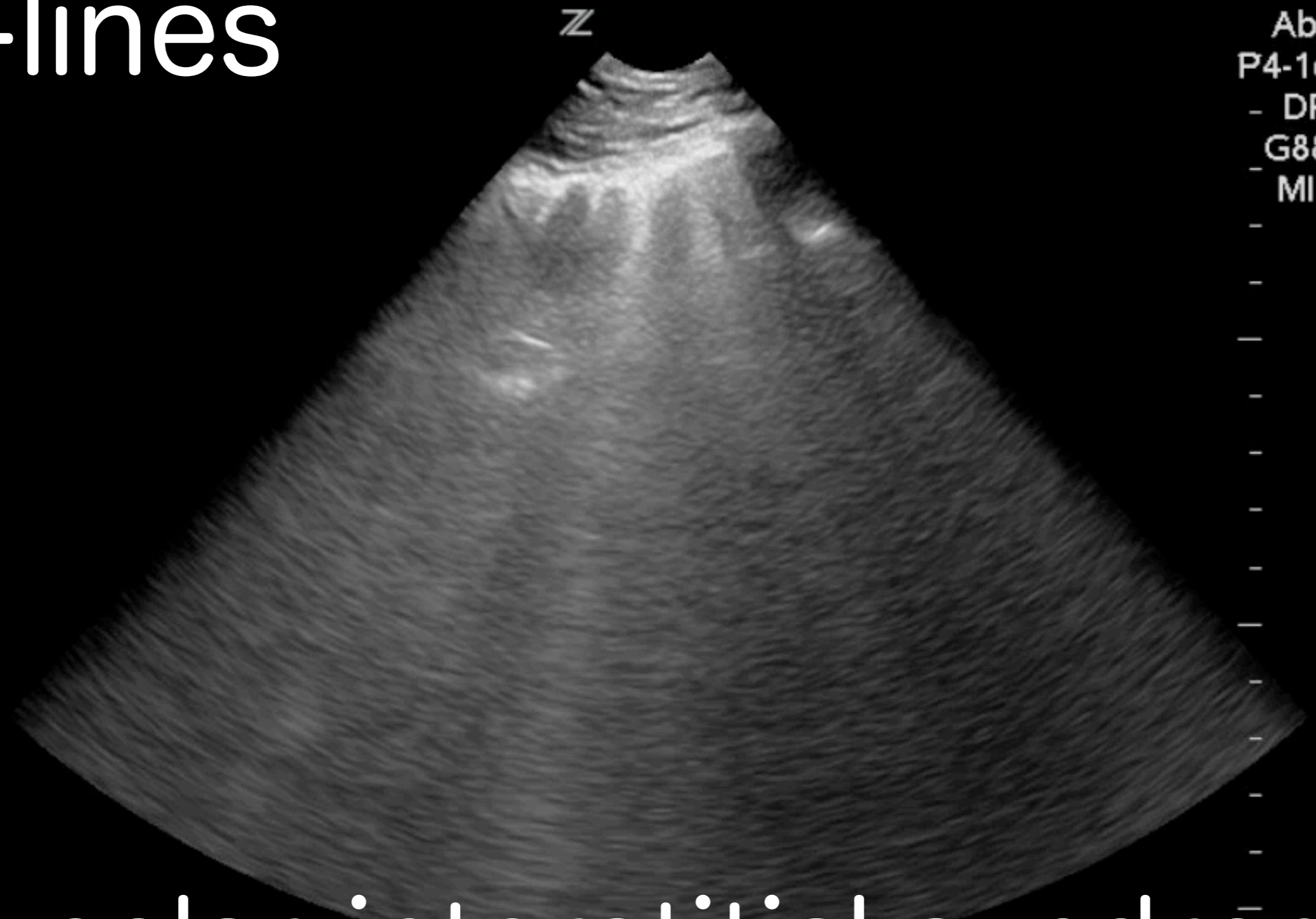Lung contusion

Pulmonary fibrosis

Alveolar-interstitial syndrome

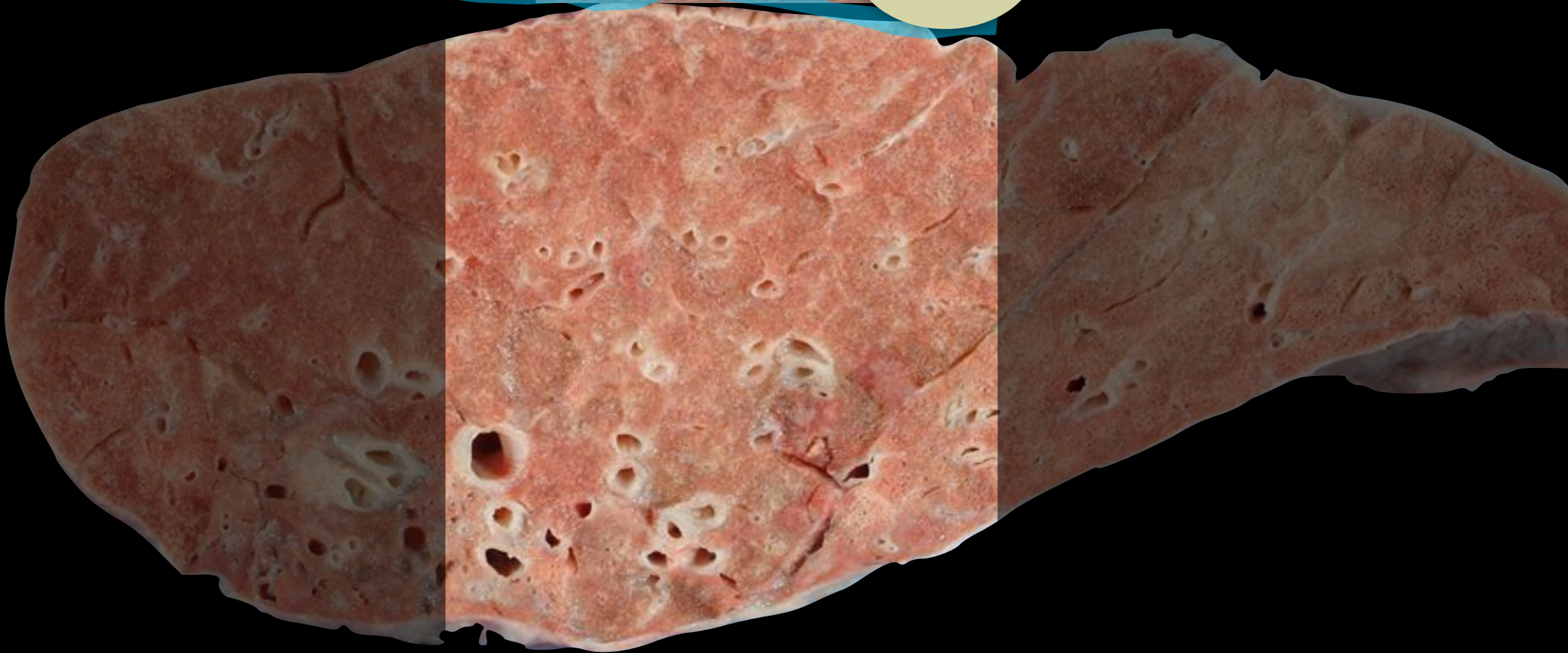
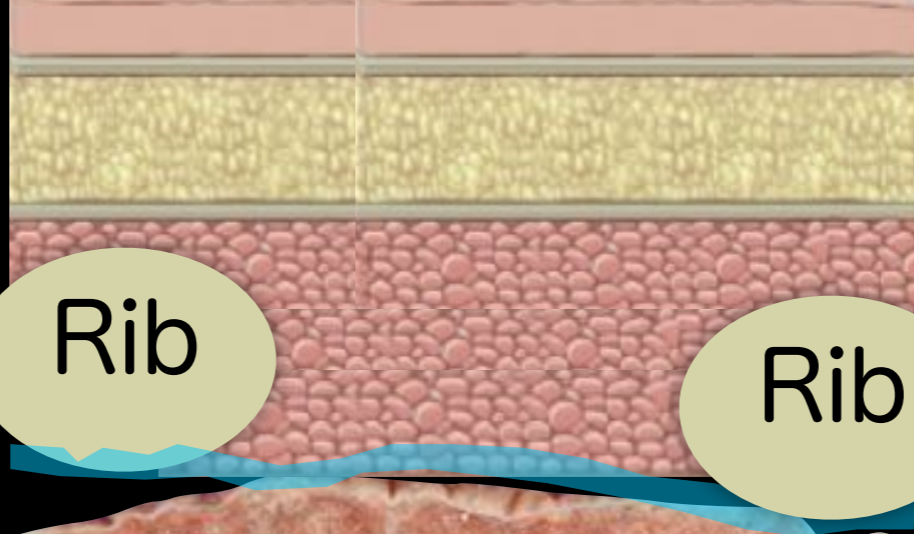
I.e., fluid or thickening present

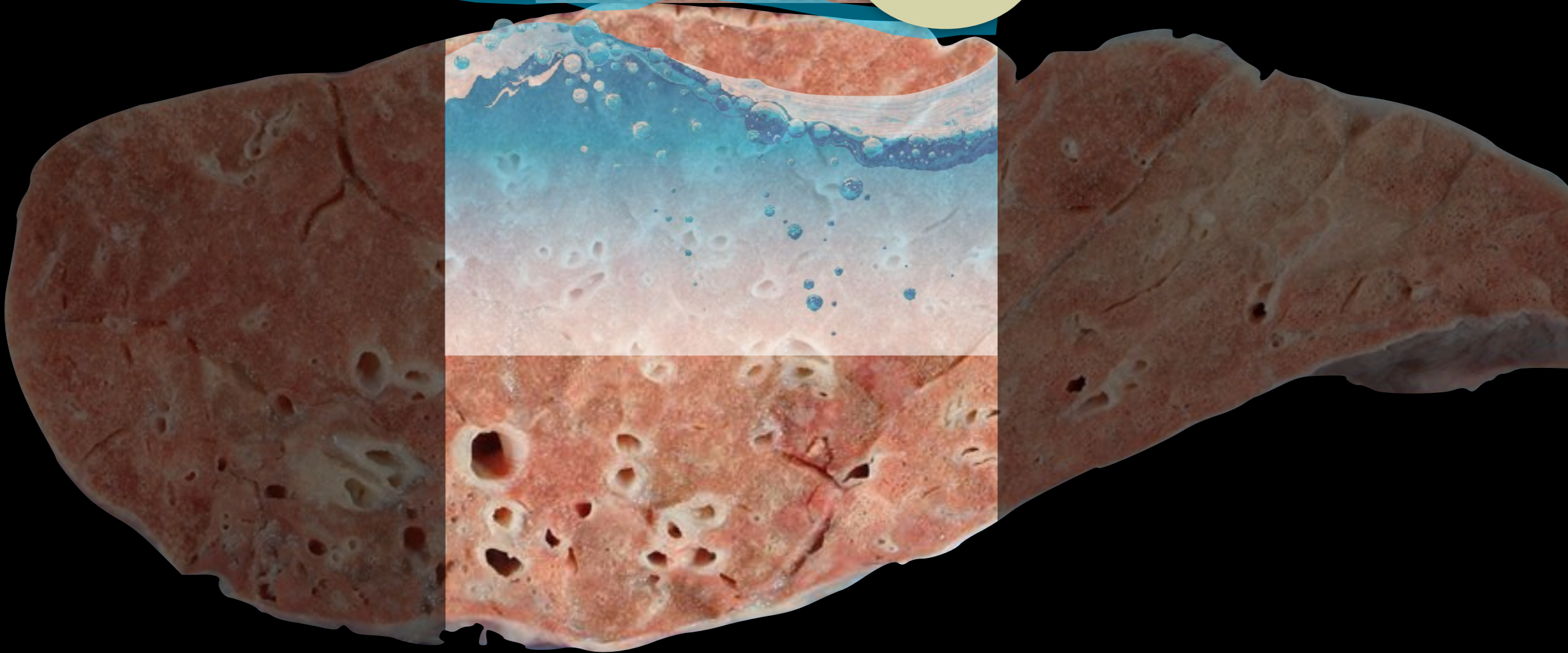
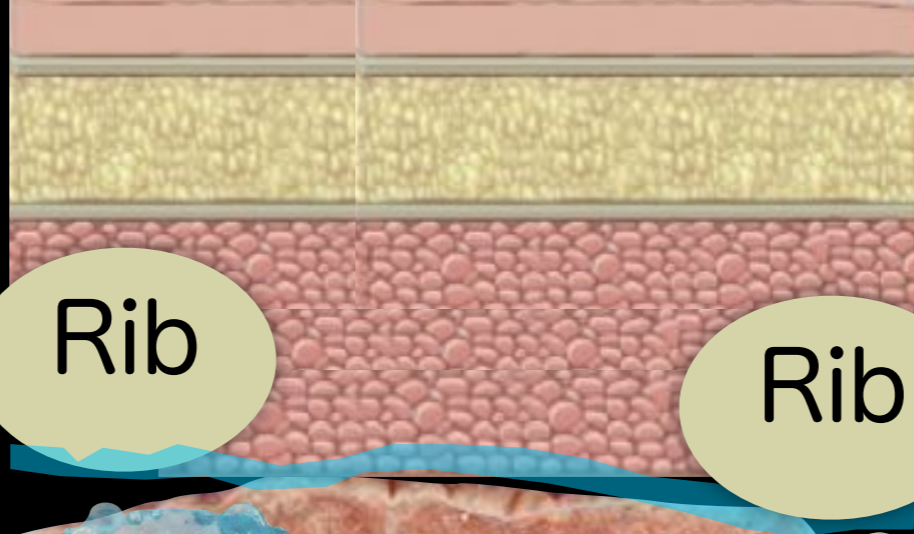
B-lines

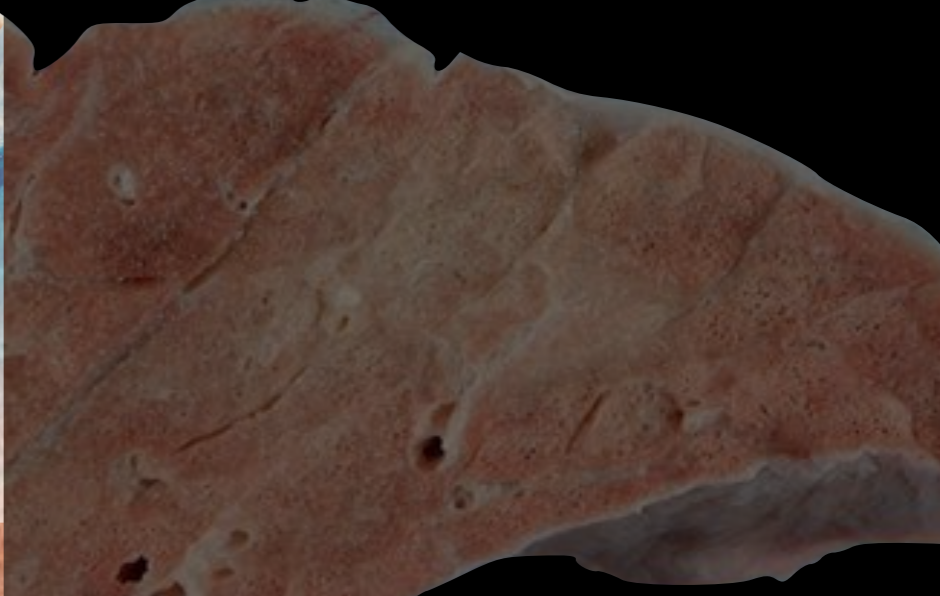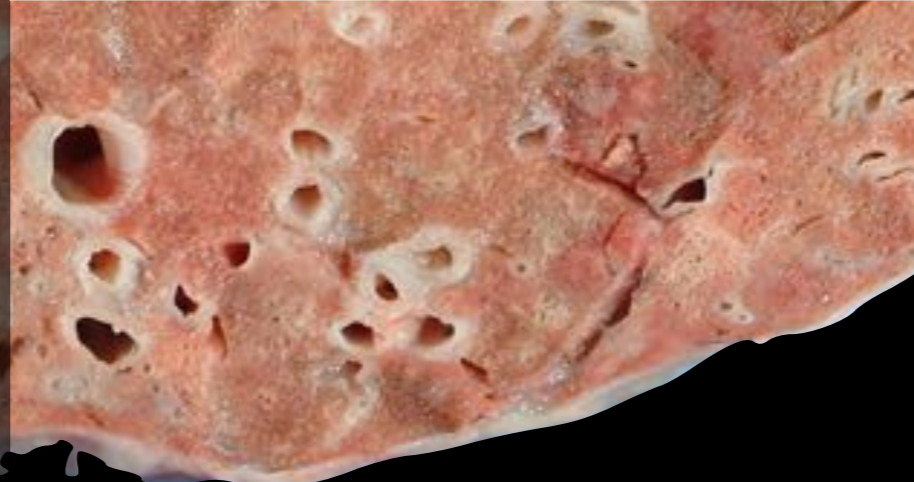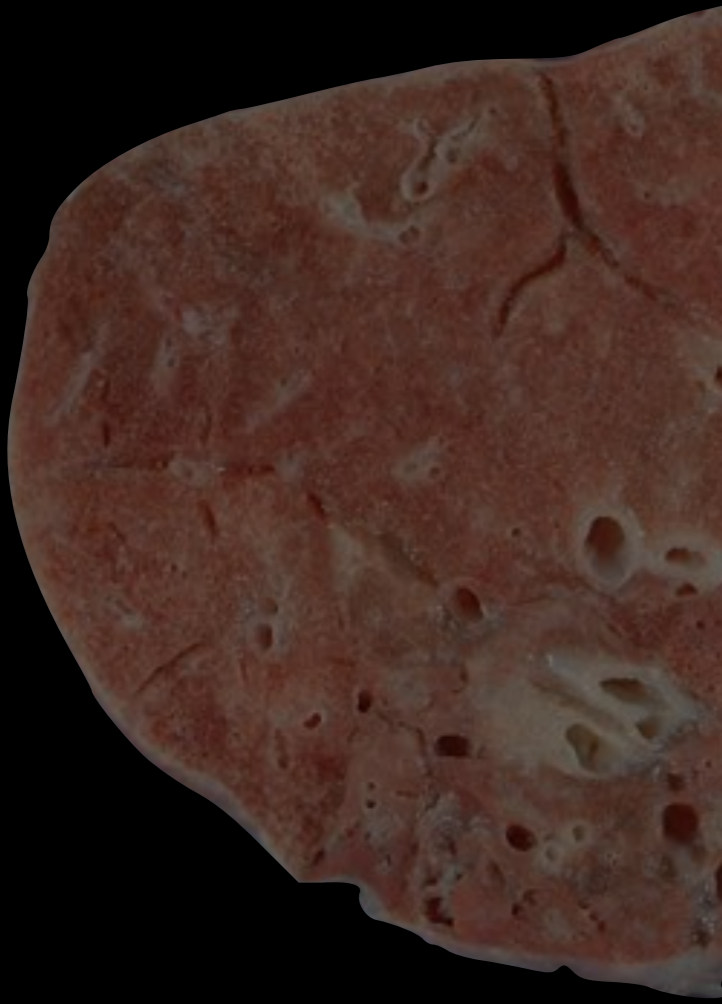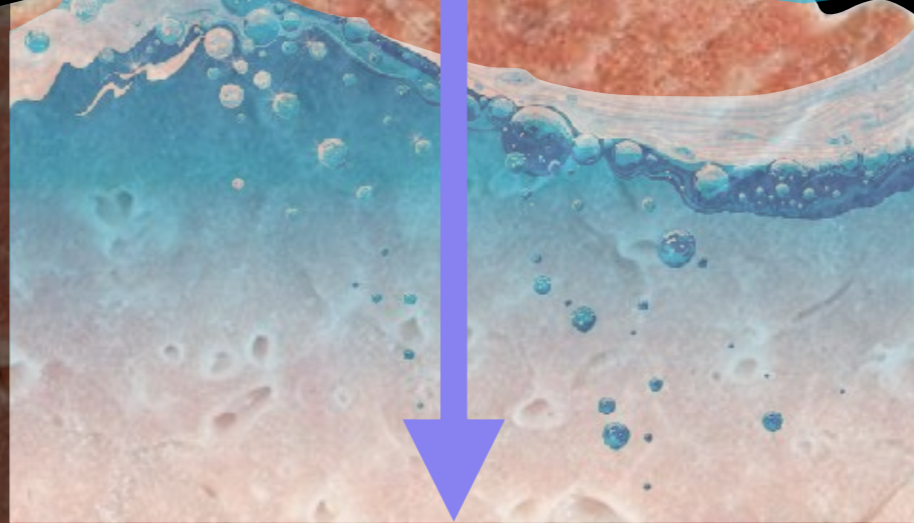
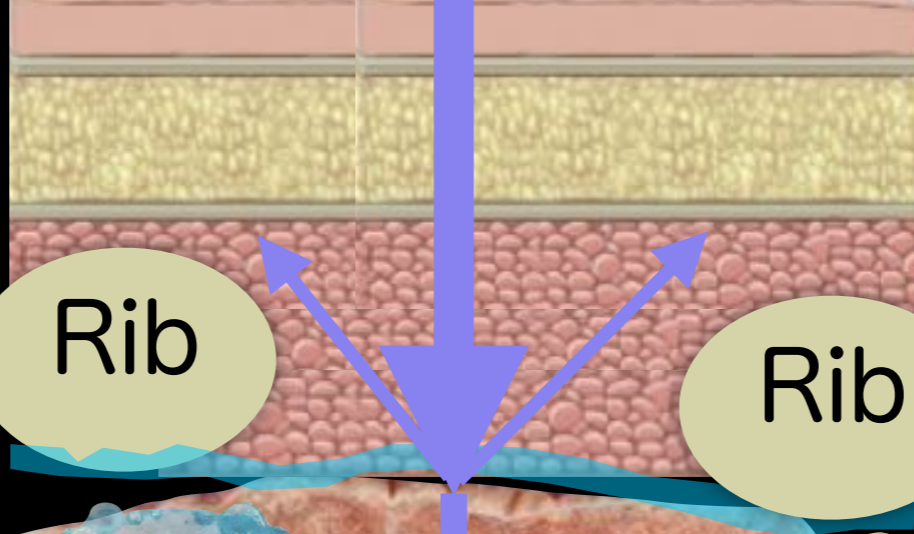


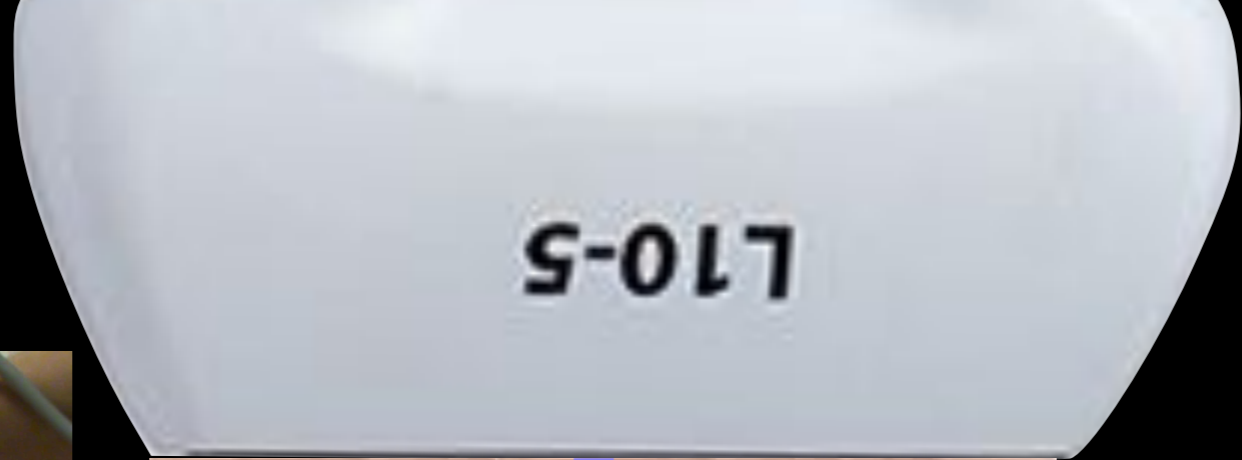Abd/General
P4-1c/CH4MHz
- DR50/M2/P2
G88/E1/100%
- MI1.5 TIs0.6
- 16.0 cm
- 19 Hz
△ ZSI 0
Image

Alveolar-interstitial syndrome
Additionally r/o pneumothorax







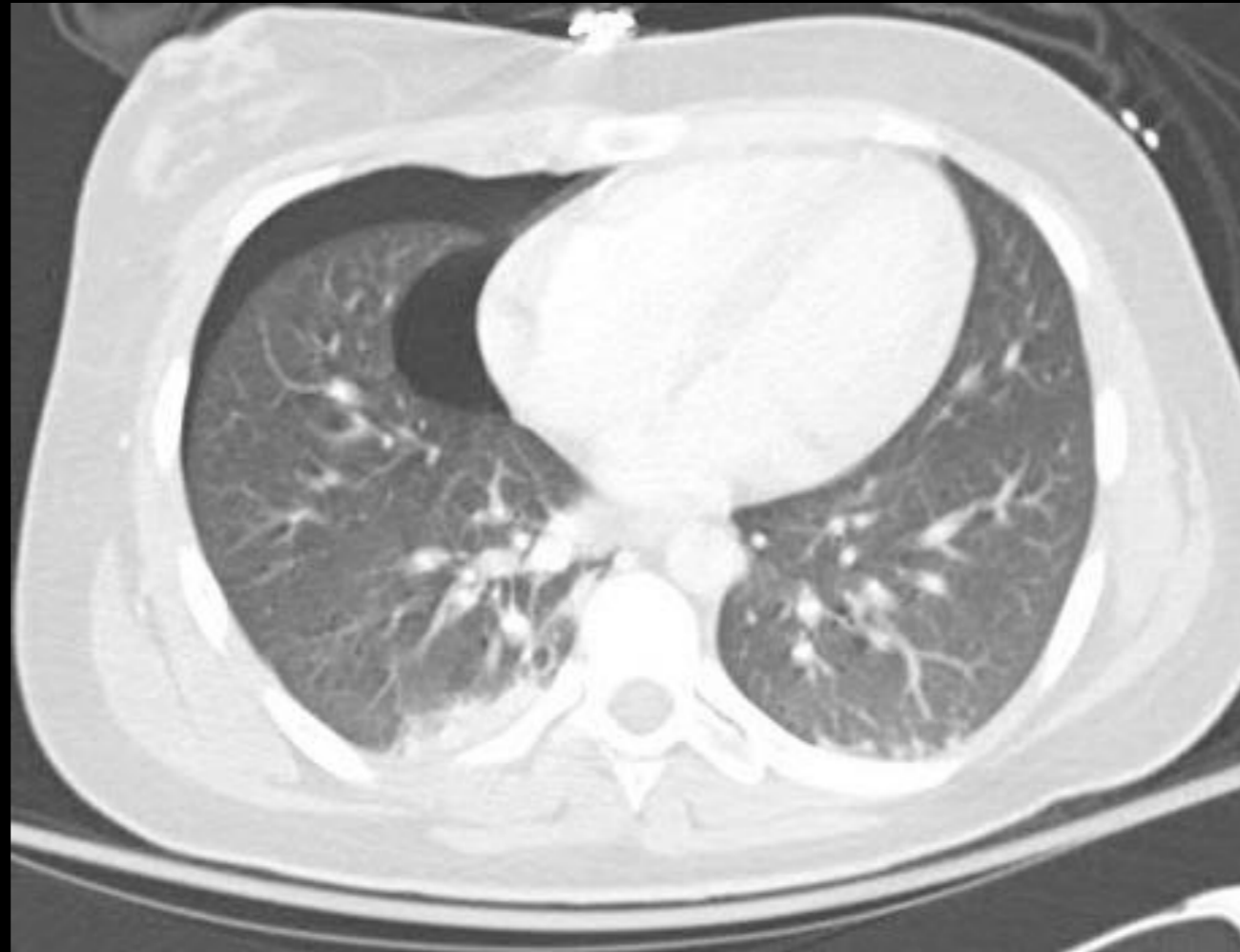Pneumothorax Evaluation

Pneumothorax Evaluation

Acute dyspnea

Pneumothorax Evaluation


Acute dyspnea



Supine position

Pneumothorax Evaluation

Acute dyspnea



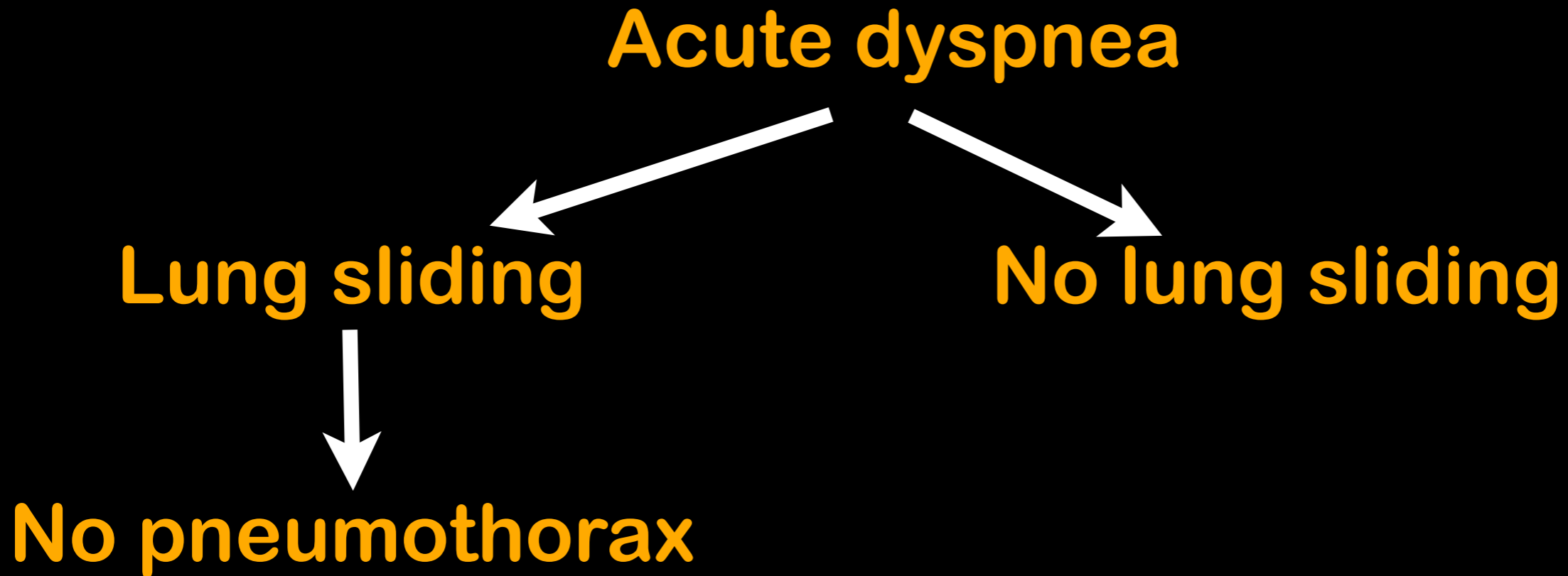
Pneumothorax Evaluation

Acute dyspnea

Lung sliding

No lung sliding

No pneumothorax



Pneumothorax Evaluation

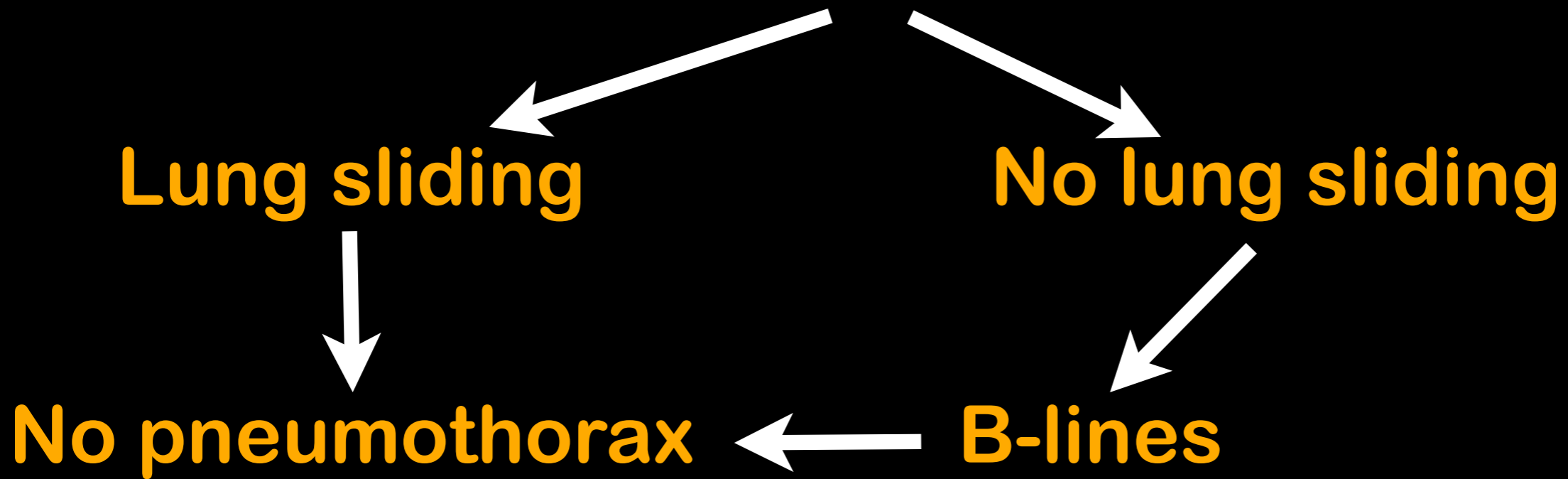
Acute dyspnea

Lung sliding

No lung sliding

No pneumothorax

B-lines



Pneumothorax Evaluation

Acute dyspnea

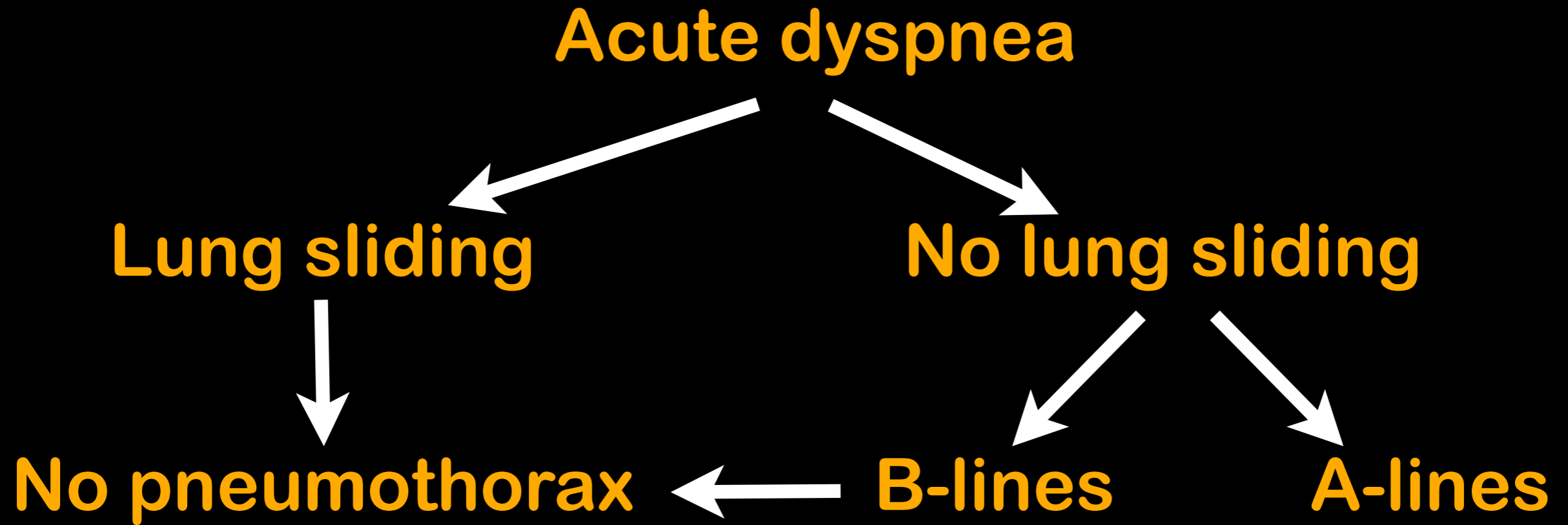
Lung sliding

No lung sliding

No pneumothorax

B-lines

A-lines



Pneumothorax Evaluation

Acute dyspnea

Lung sliding

No lung sliding

No pneumothorax

B-lines

A-lines

Lung point

Pneumothorax Evaluation

Acute dyspnea

Lung sliding

No lung sliding

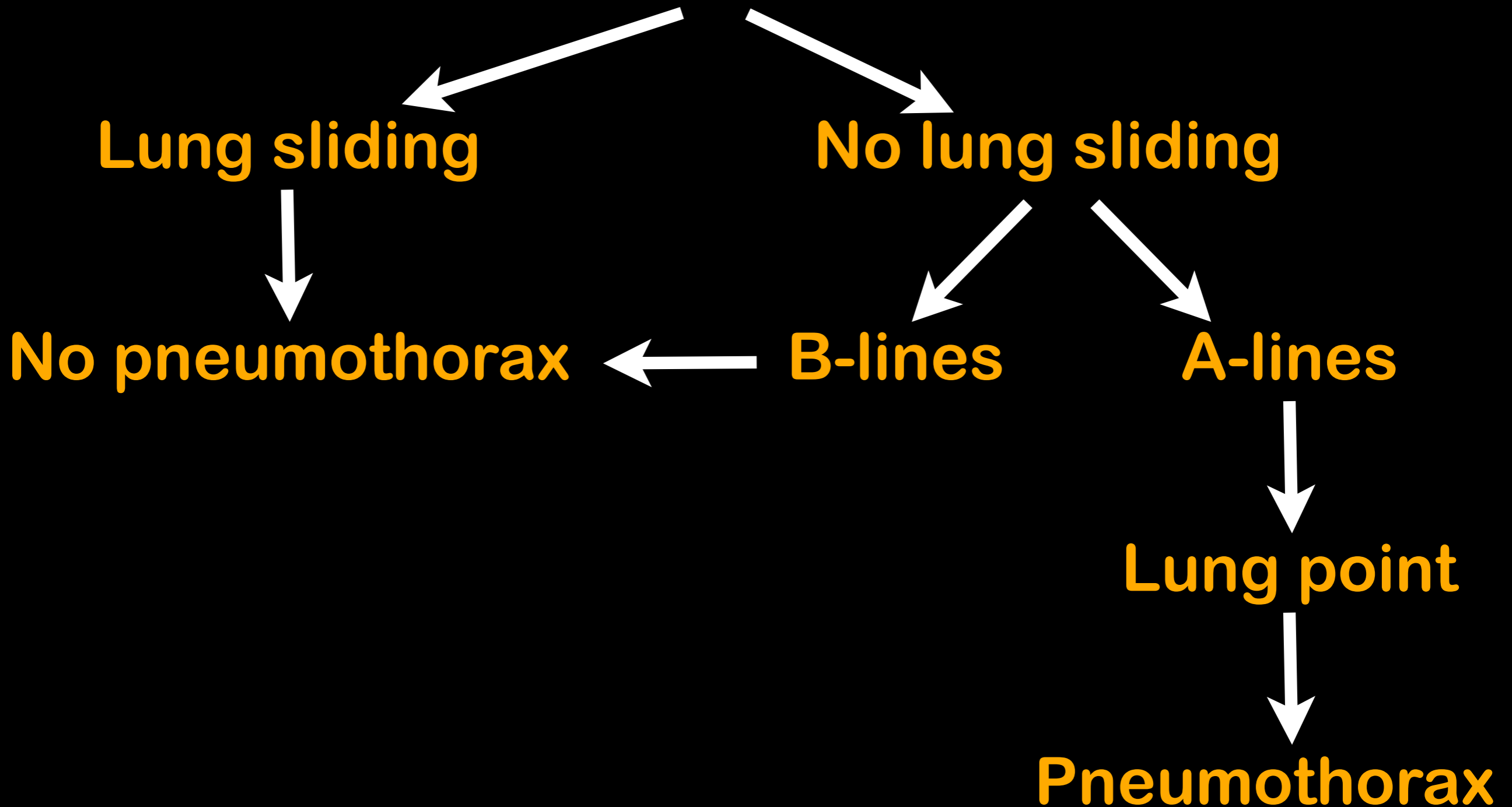
No pneumothorax

B-lines

A-lines

Lung point

Pneumothorax



Pneumothorax Evaluation

Acute dyspnea

Lung sliding

No lung sliding

No pneumothorax

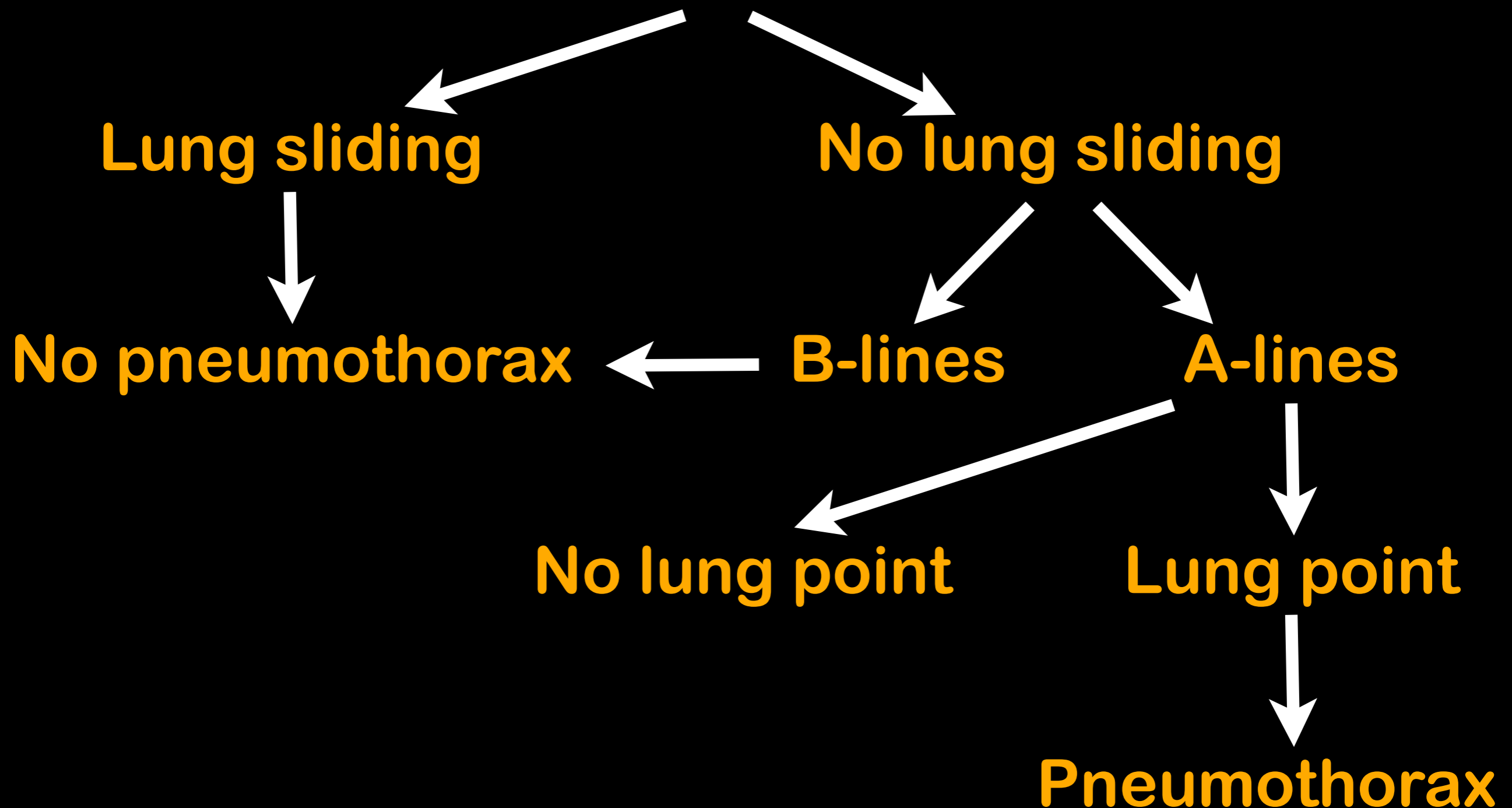
B-lines

A-lines

No lung point

Lung point

Pneumothorax



Pneumothorax Evaluation

Acute dyspnea

Lung sliding

No lung sliding

No pneumothorax

B-lines

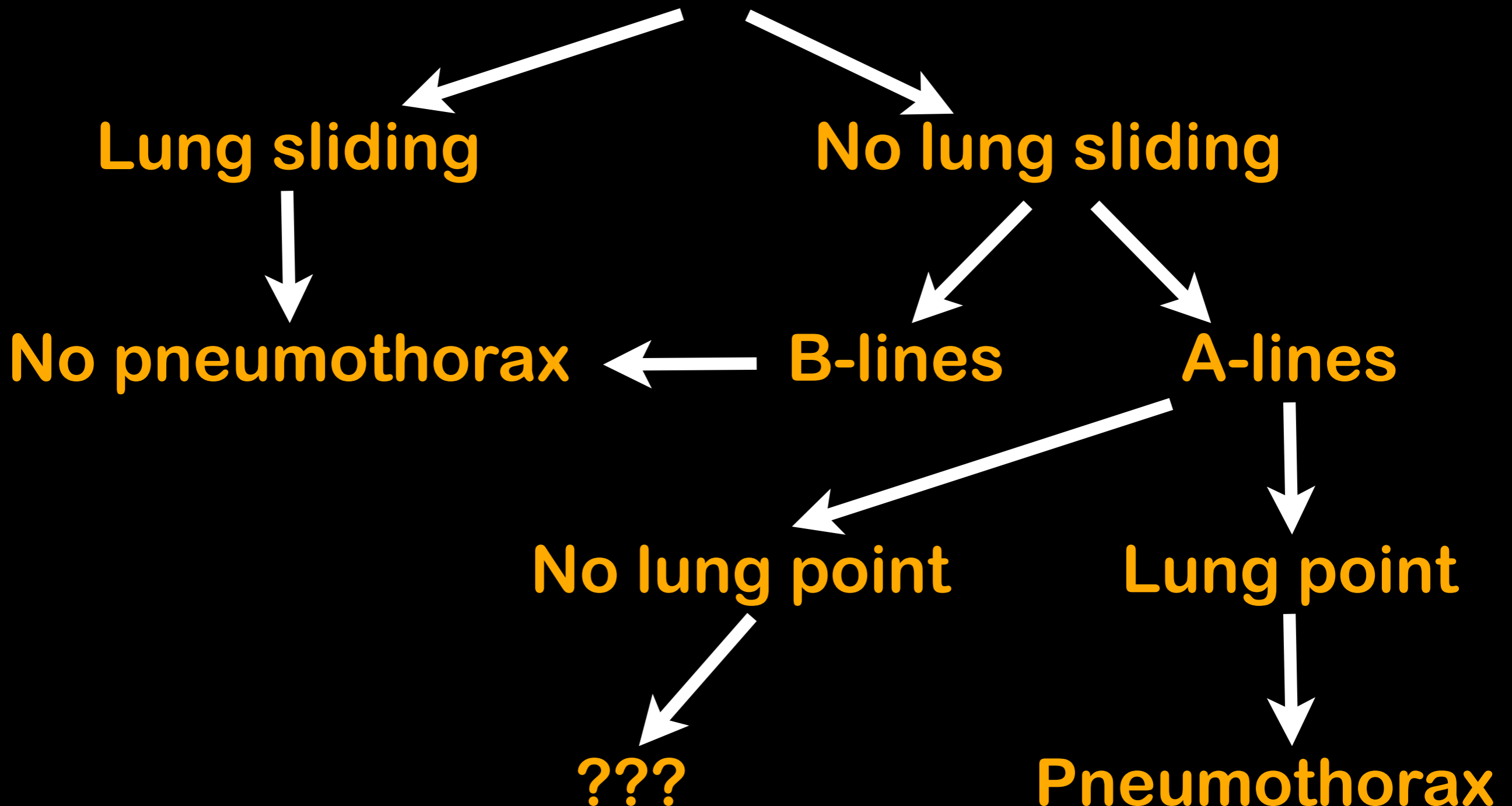
A-lines

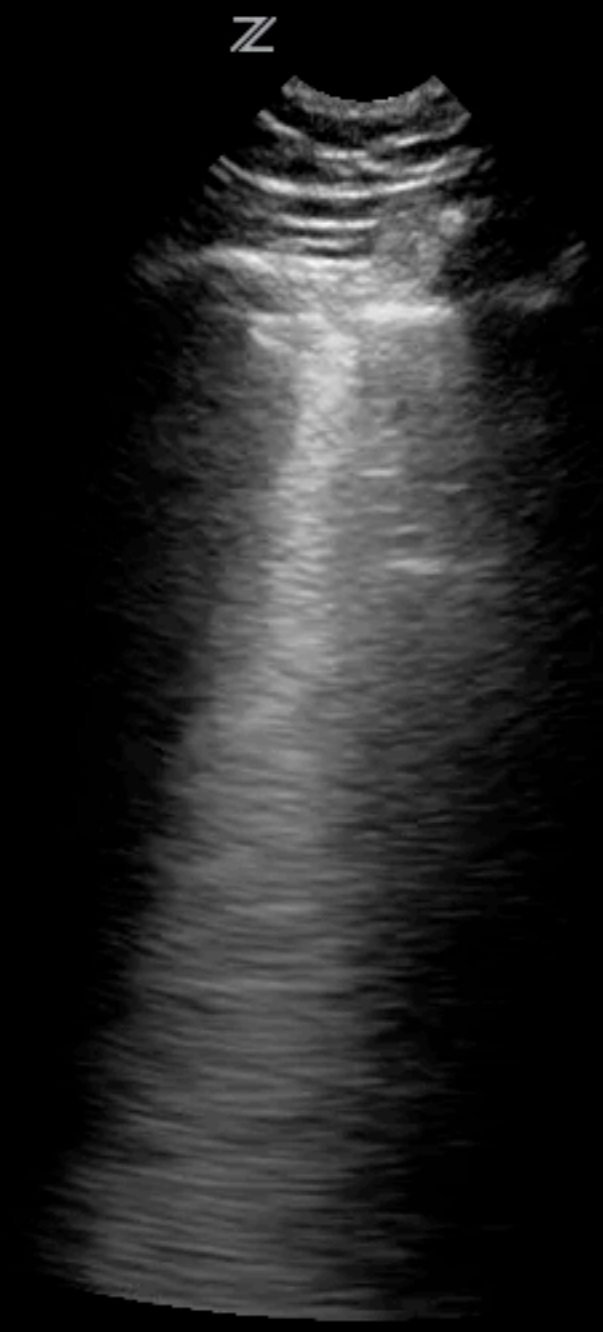
No lung point

Lung point

???

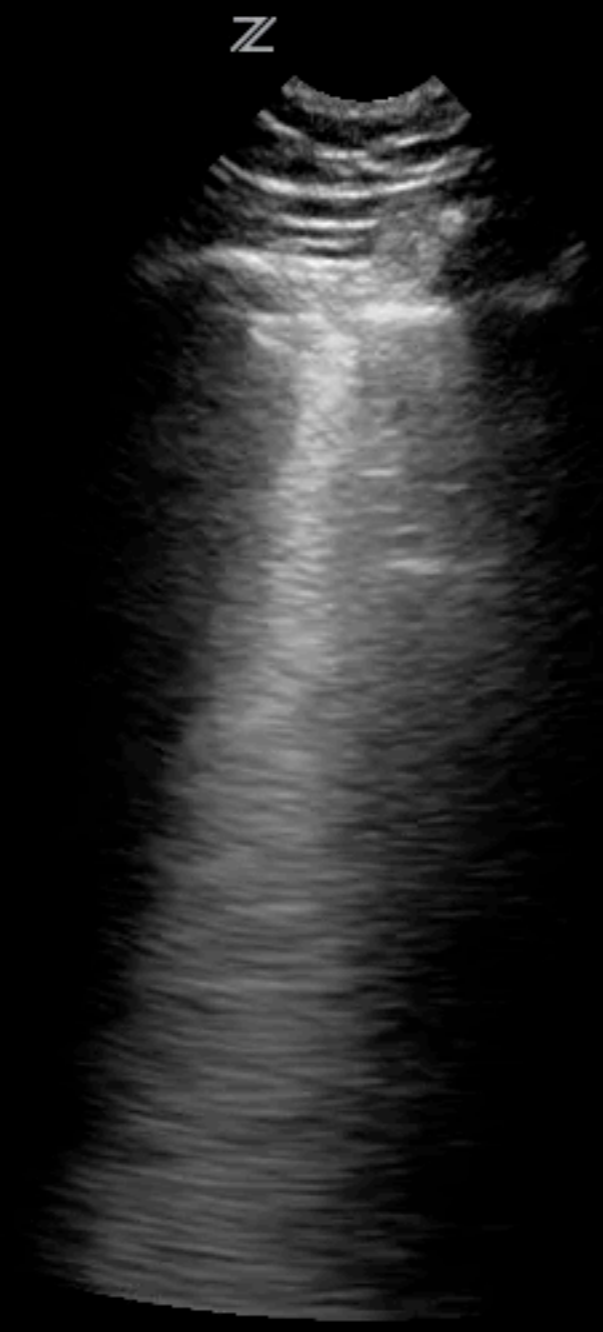
Pneumothorax





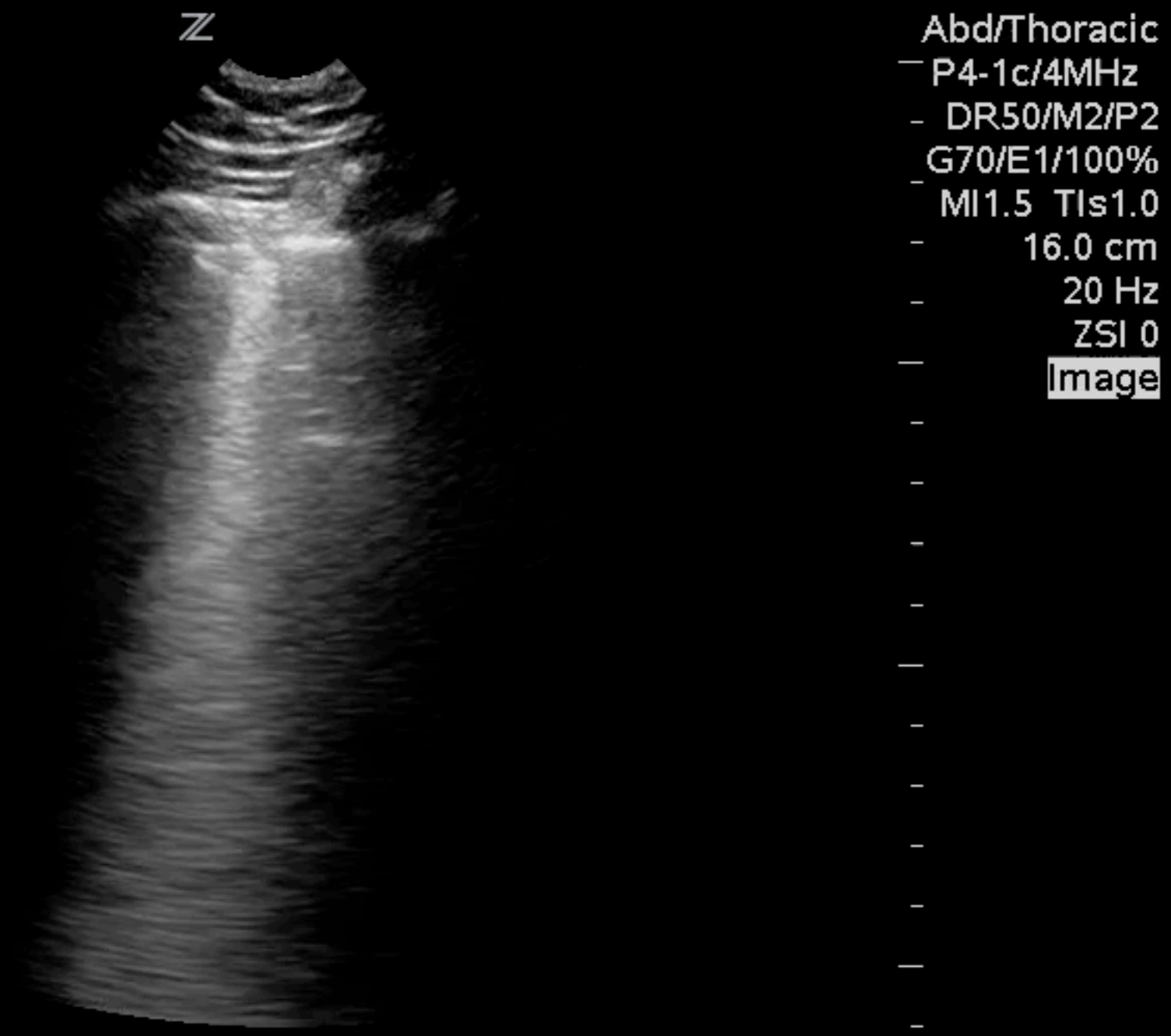Abd/Thoracic
- P4-1c/4MHz
- DR50/M2/P2
- G70/E1/100%
- MI1.5 TIs1.0
- 16.0 cm
- 20 Hz
- ZSI 0
- **Image**

B-lines



Abd/Thoracic
- P4-1c/4MHz
- DR50/M2/P2
- G70/E1/100%
- MI1.5 TIs1.0
- 16.0 cm
- 20 Hz
- ZSI 0
- **Image**

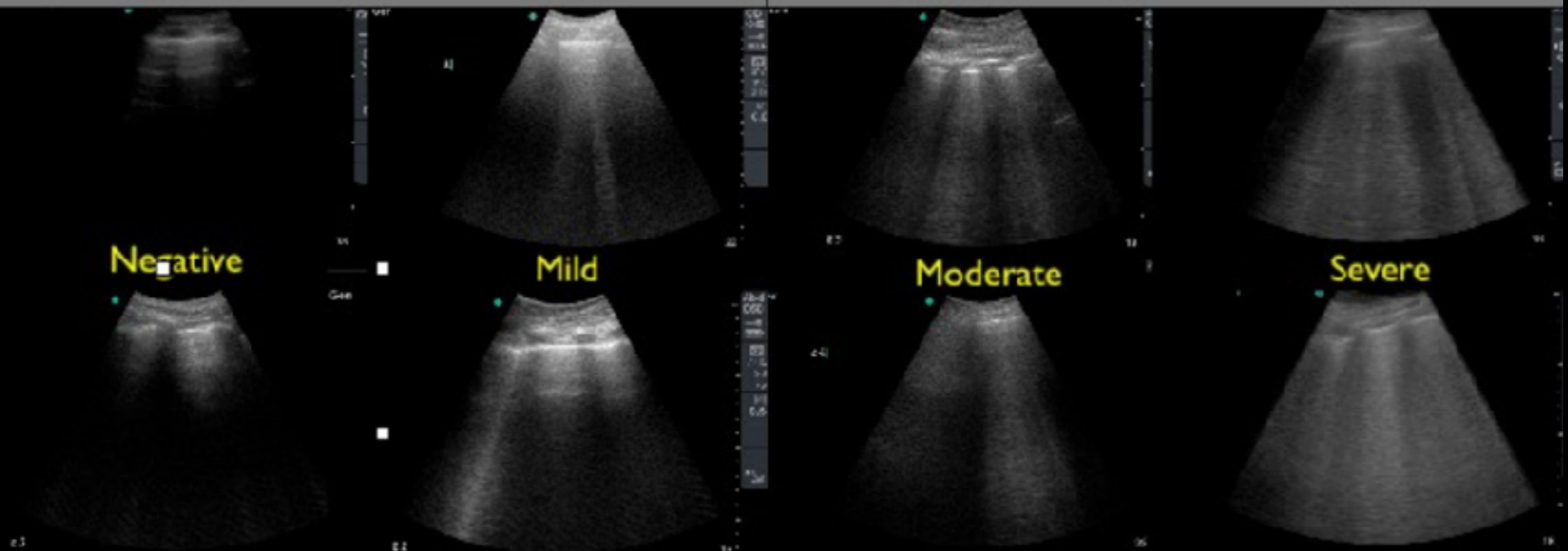
B-lines



B-lines

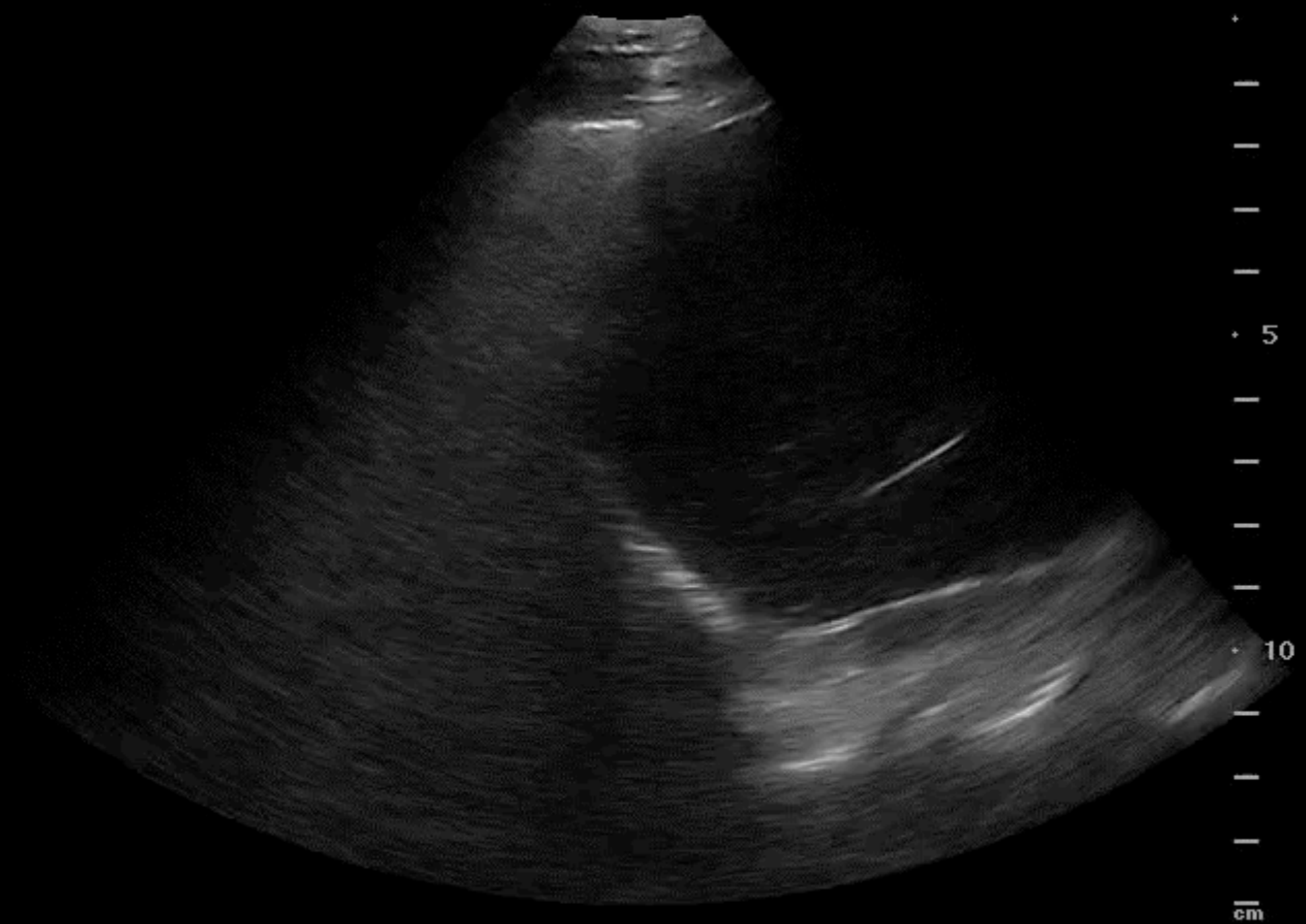Number present correlate with severity

Severity Rating	Description
Negative	No B-lines or fewer than 3 discrete B lines seen at any time
Mild	At least 3 discrete B lines per rib space, few in number, intermittently present
Moderate	Many or partially discrete or partially-coalesced B lines, persistently present
Severe	Complete coalescence of B-lines, many in number, persistently present



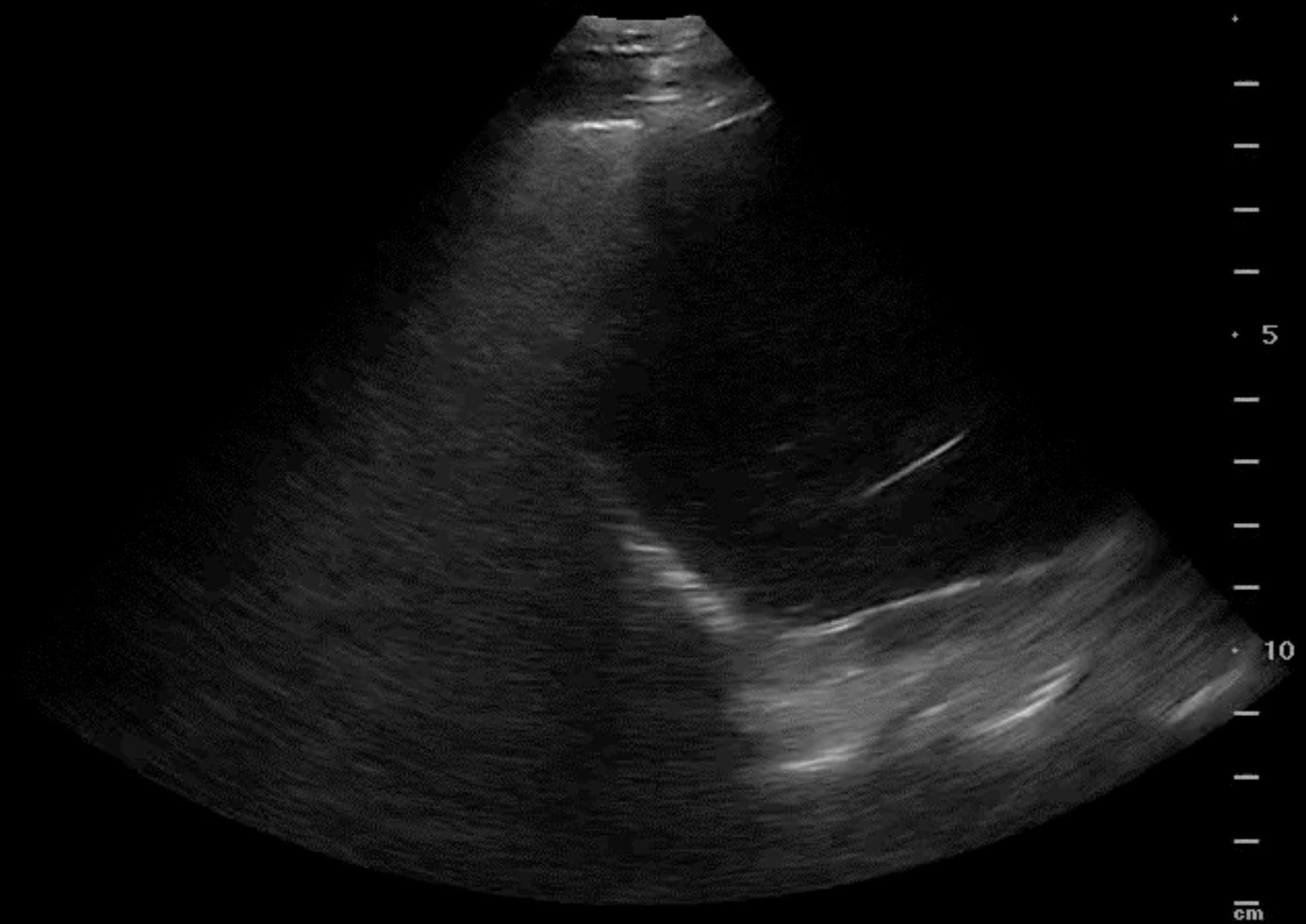
Z

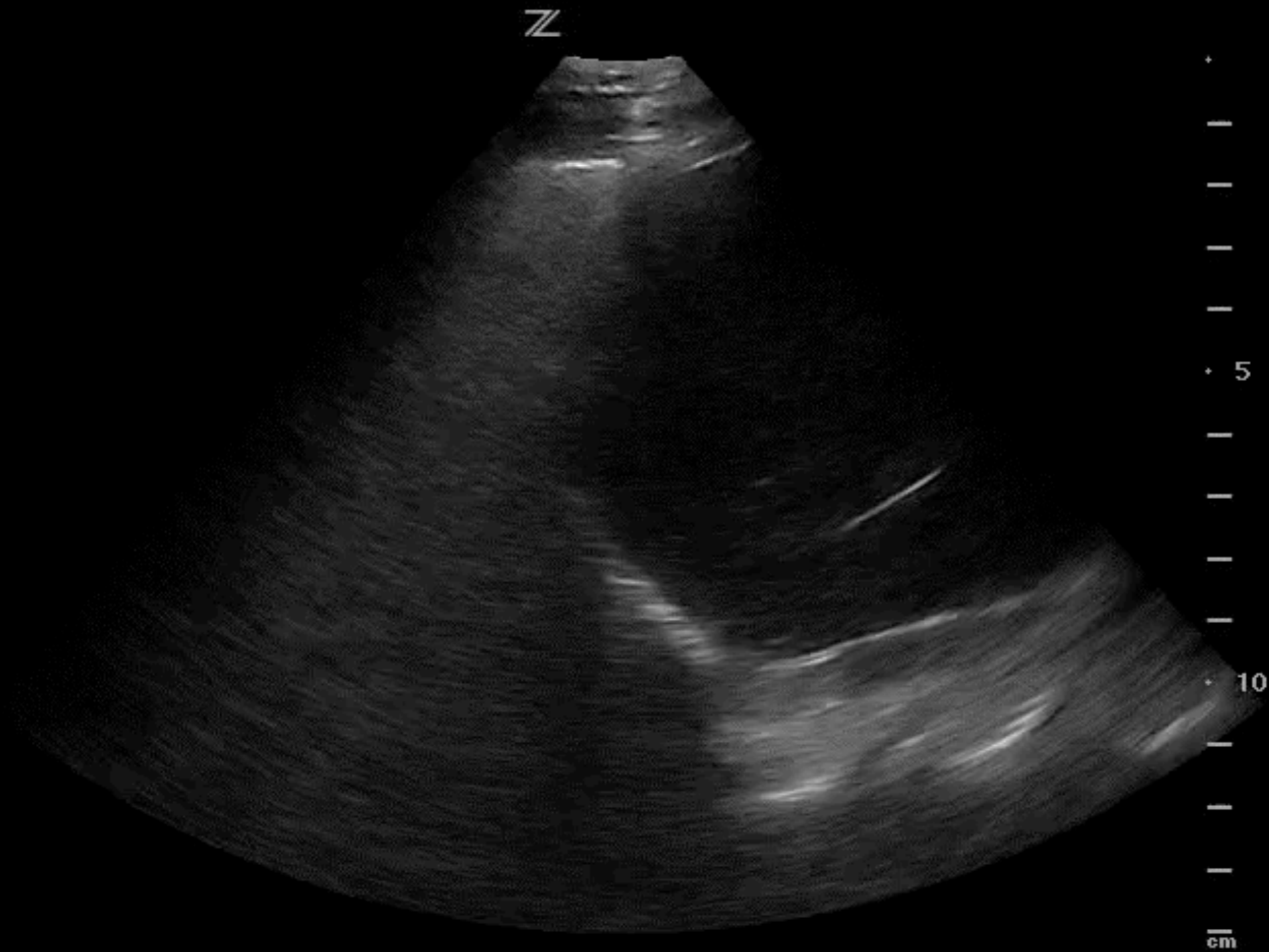P4-1c/4.0
DR75/M2/P2
G56/E1/100%
MI0.6 TIs0.3
14.0 cm
15/15 Hz
△ ZSI 0
Image



Z

P4-1c/4.0
DR75/M2/P2
G56/E1/100%
MI0.6 TIs0.3
14.0 cm
15/15 Hz
△ ZSI 0
Image





P4-1c/4.0
DR75/M2/P2
G56/E1/100%
MI0.6 TIs0.3
14.0 cm
15/15 Hz
△ ZSI 0
Image

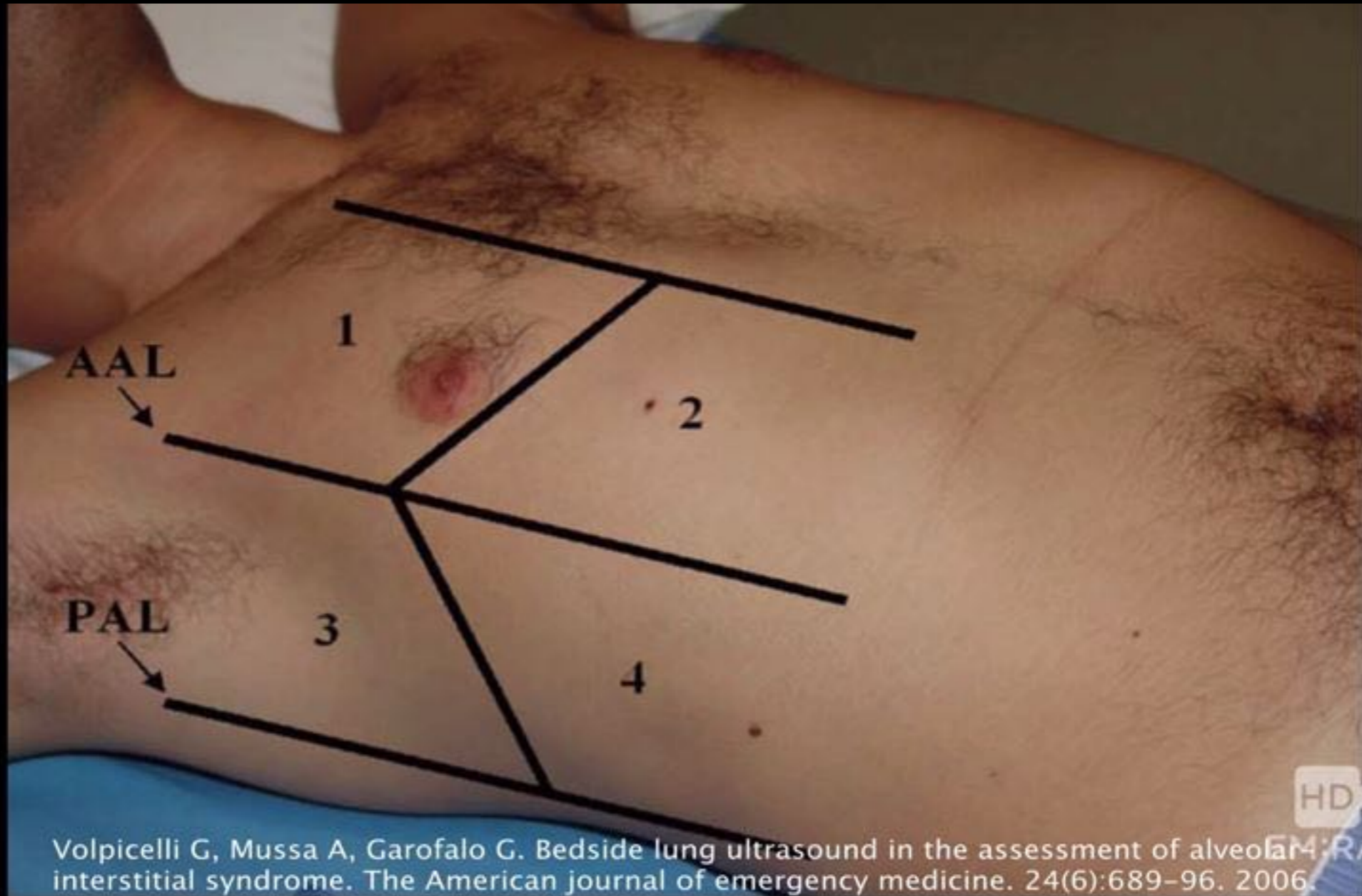
B-lines



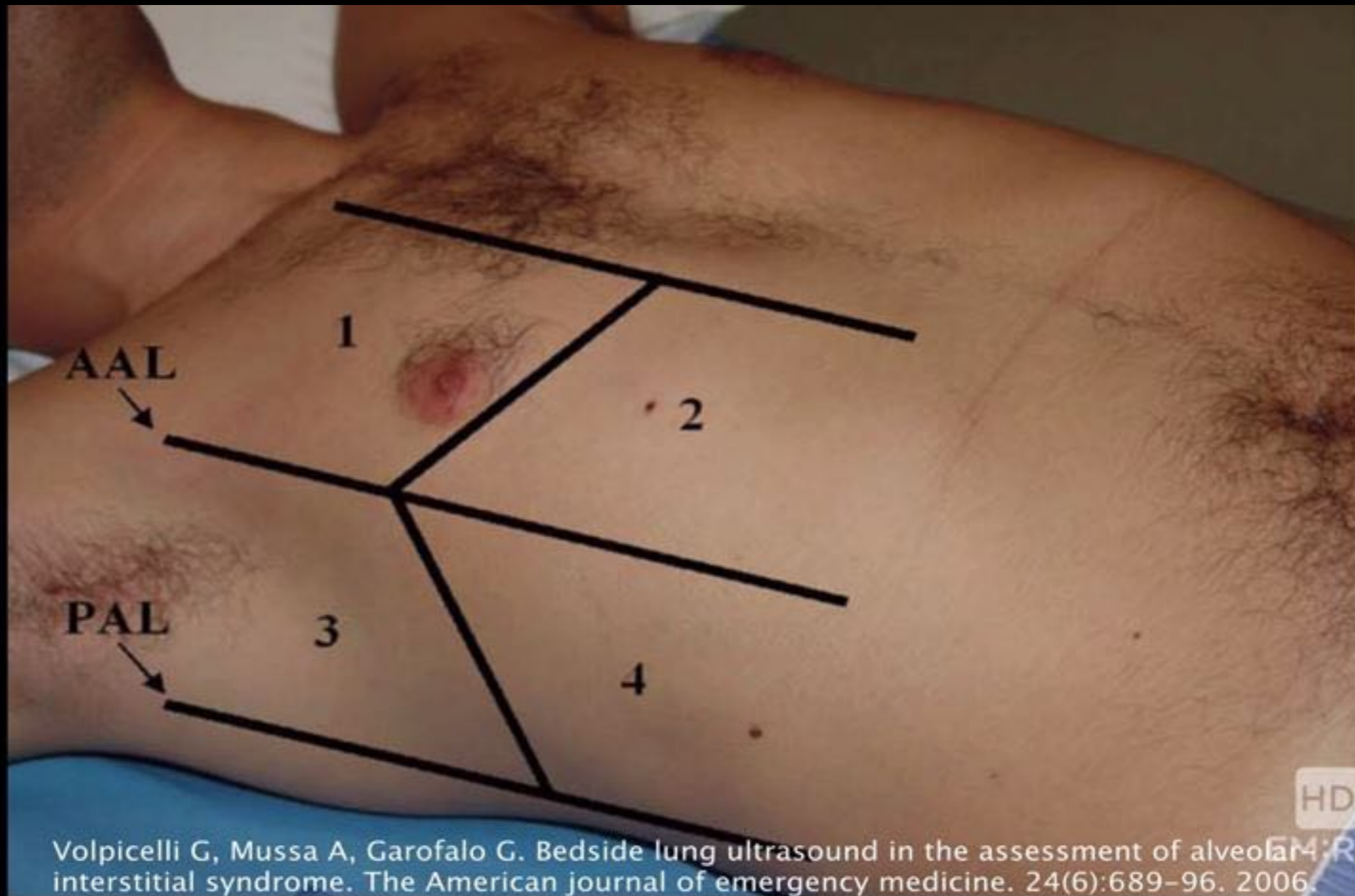
P4-1c/4.0
DR75/M2/P2
G56/E1/100%
MI0.6 TIs0.3
14.0 cm
15/15 Hz
△ ZSI 0
Image

B-lines

May be present in asymptomatic patients




Alveolar-interstitial syndrome



Volpicelli G, Mussa A, Garofalo G. Bedside lung ultrasound in the assessment of alveolar interstitial syndrome. The American journal of emergency medicine. 24(6):689-96. 2006.

Alveolar-interstitial syndrome
> 3/zone, >1 zone/side, (+) bilaterally

Interpretation



Lung sliding?

Lung sliding?

A-lines?

Lung sliding?

A-lines?

B-lines?

Lung sliding?

A-lines?

B-lines?

Consolidations or Effusions?

Consolidations or Effusions?

Scanning technique




Scanning technique



Probe

Approach

Scanning technique




Probe

Curvilinear or phased array probe

Approach

Scanning technique




Probe

Approach

Think FAST

Scanning technique



Probe

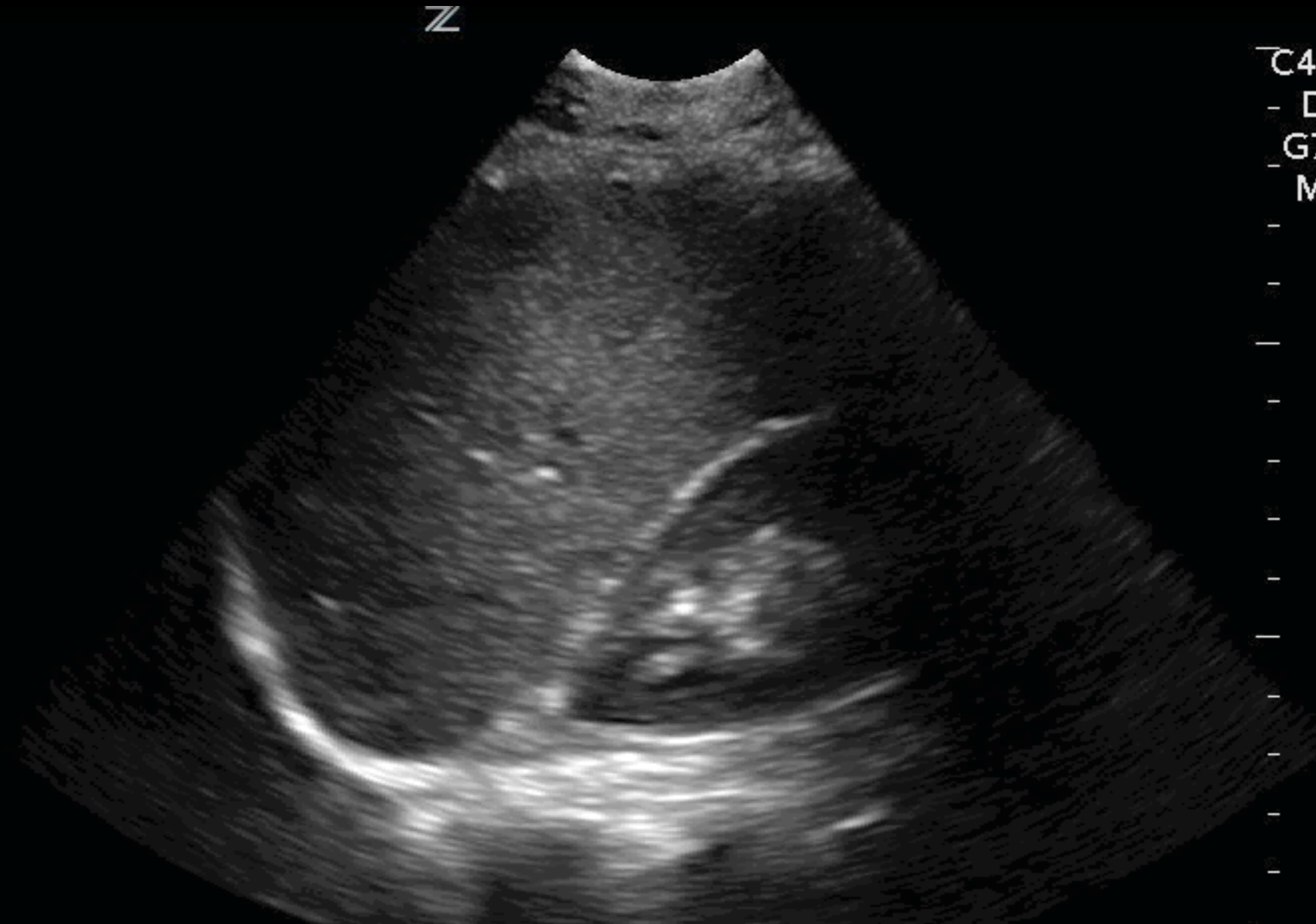
Approach



Scanning technique



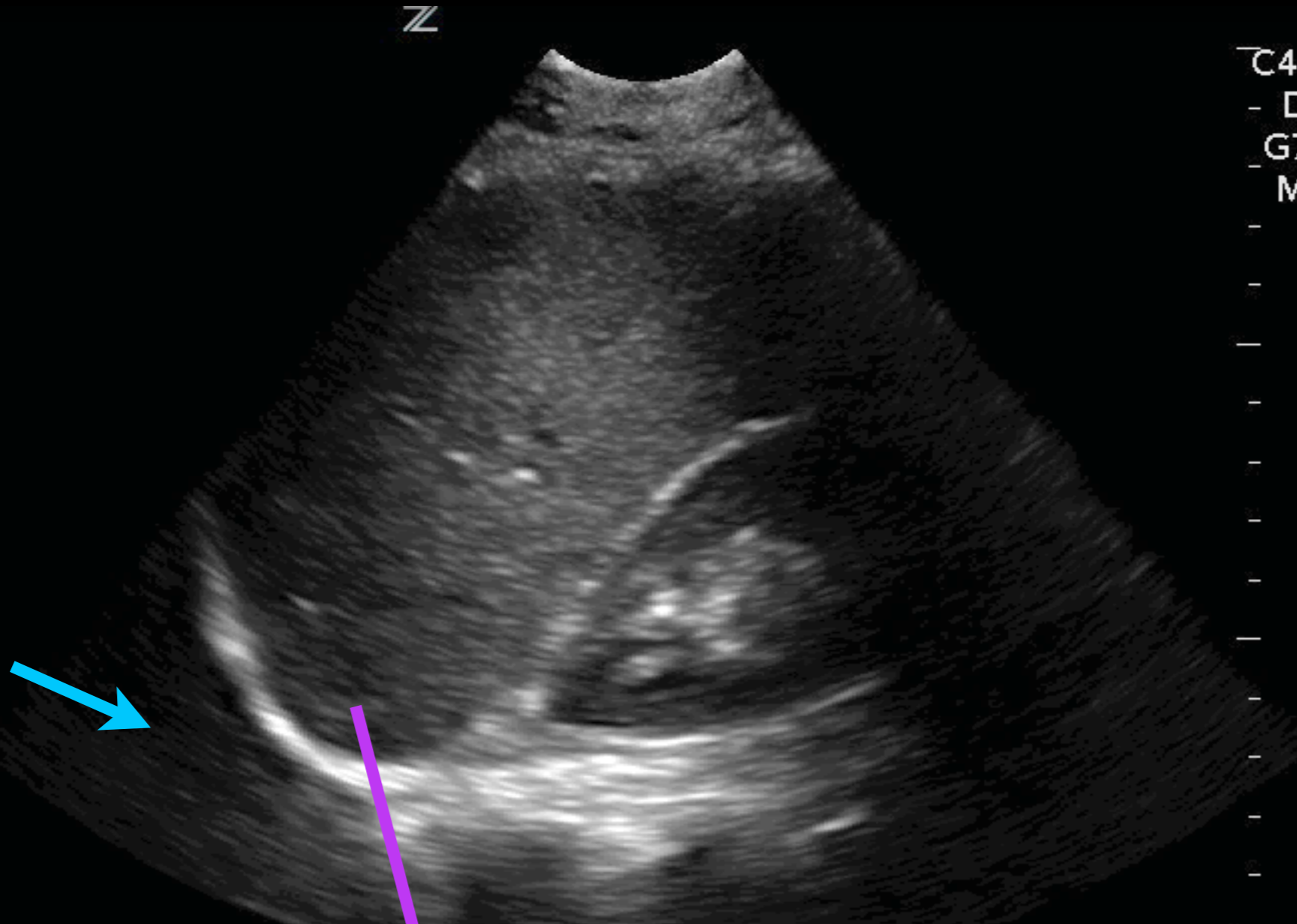
Scanning technique



Abd/Fast
C4-1/H3.5MHz
- DR65/M3/P1
G76/E2/100%
- MI1.5 TIs0.3
- 16.0 cm
- 28 Hz
△ ZSI 0

Right pleural space
Hepatic window

Scanning technique



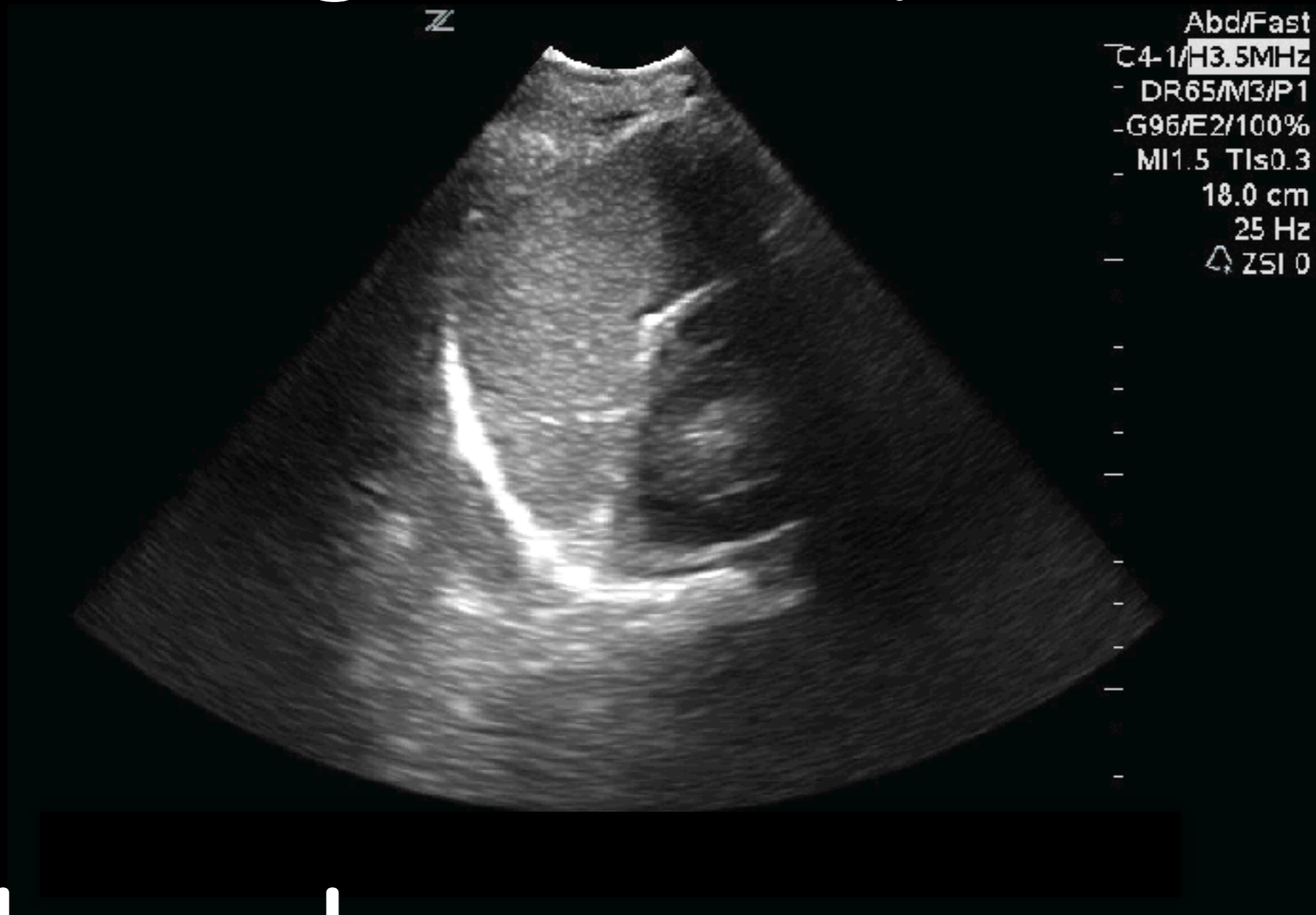
Abd/Fast
C4-1/H3.5MHz
- DR65/M3/P1
G76/E2/100%
- MI1.5 TIs0.3
- 16.0 cm
- 28 Hz
△ ZSI 0

Right pleural space
Hepatic window

Scanning technique

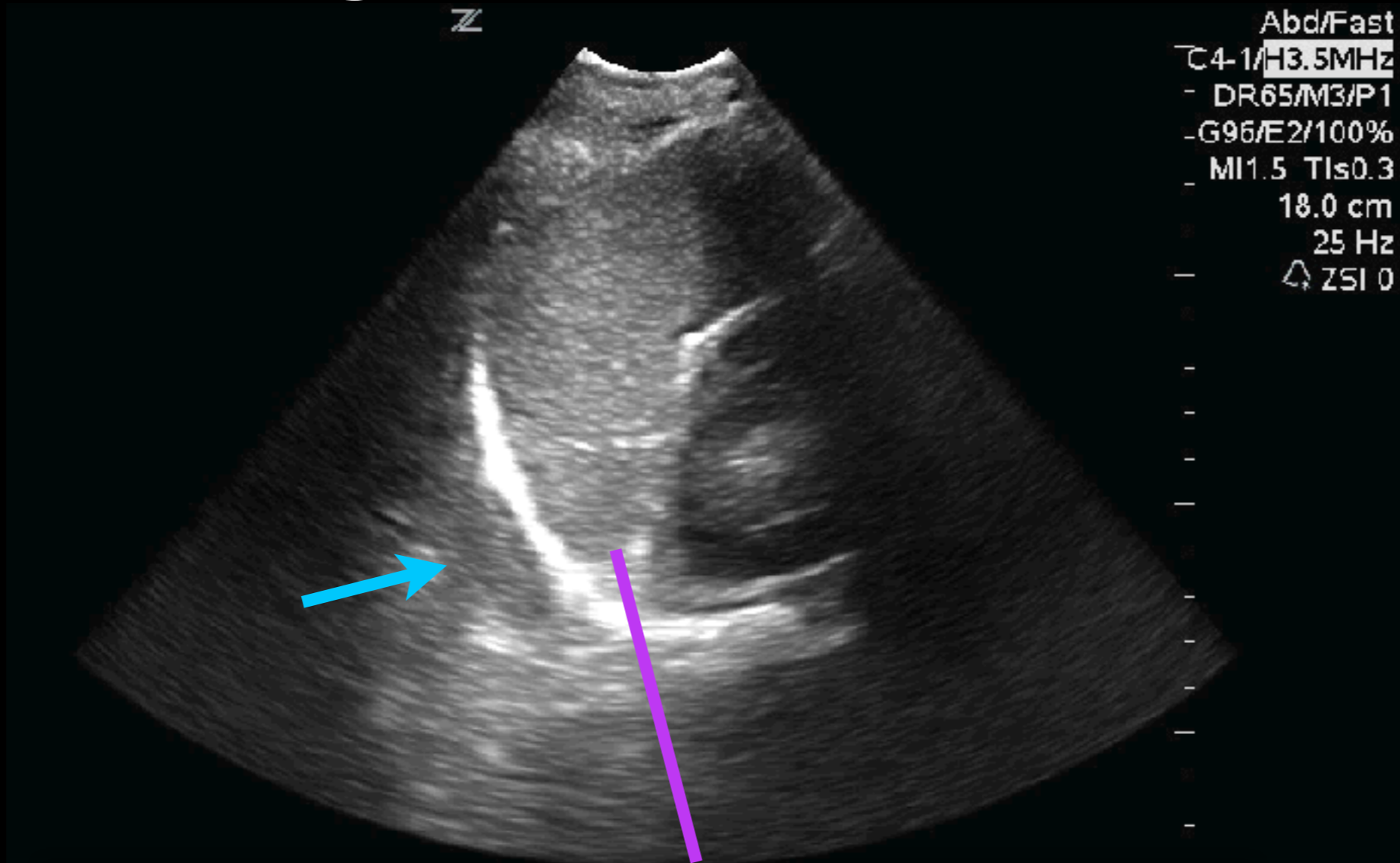


Scanning technique



L pleural space
Splenic window

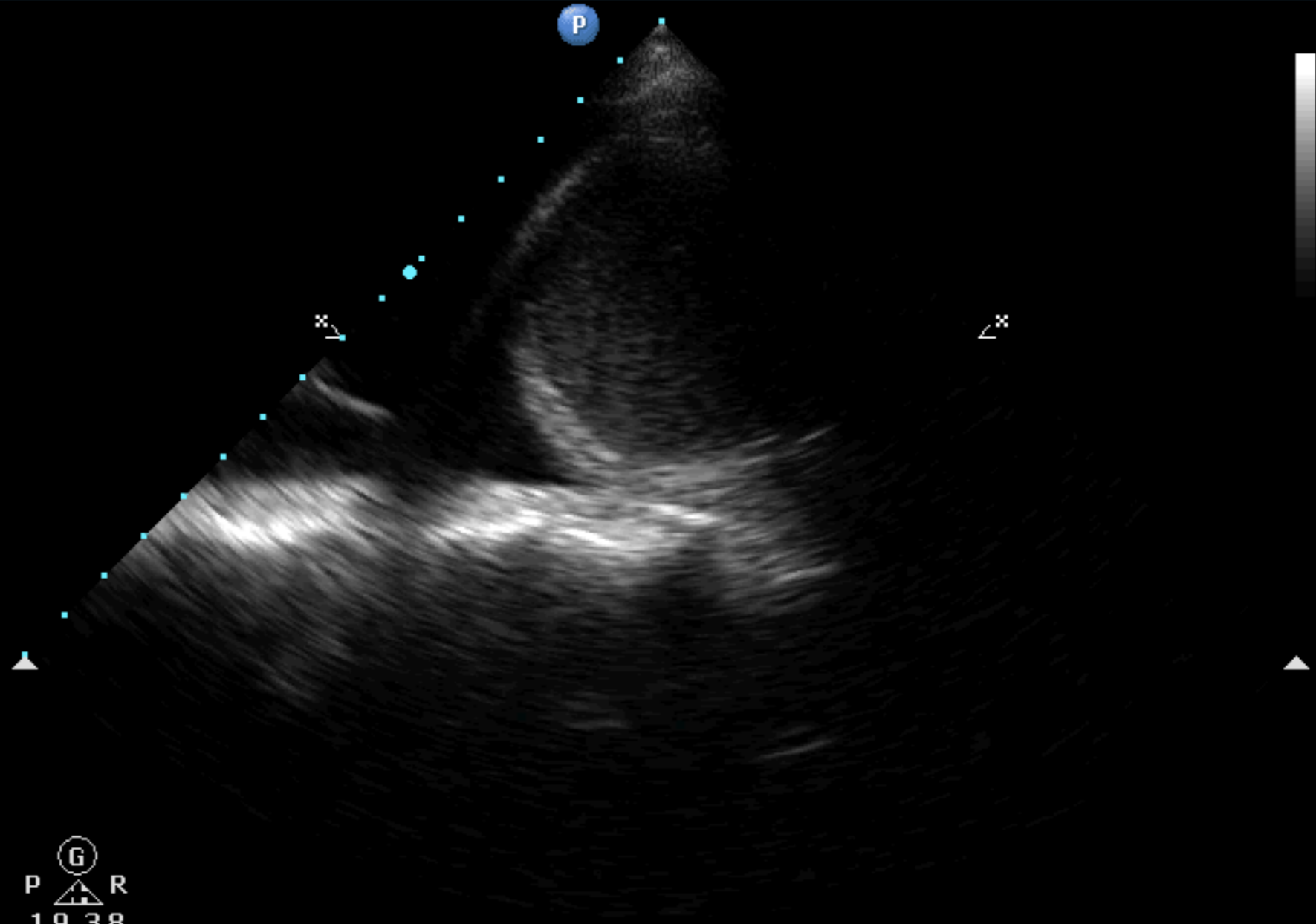
Scanning technique



L pleural space
Splenic window

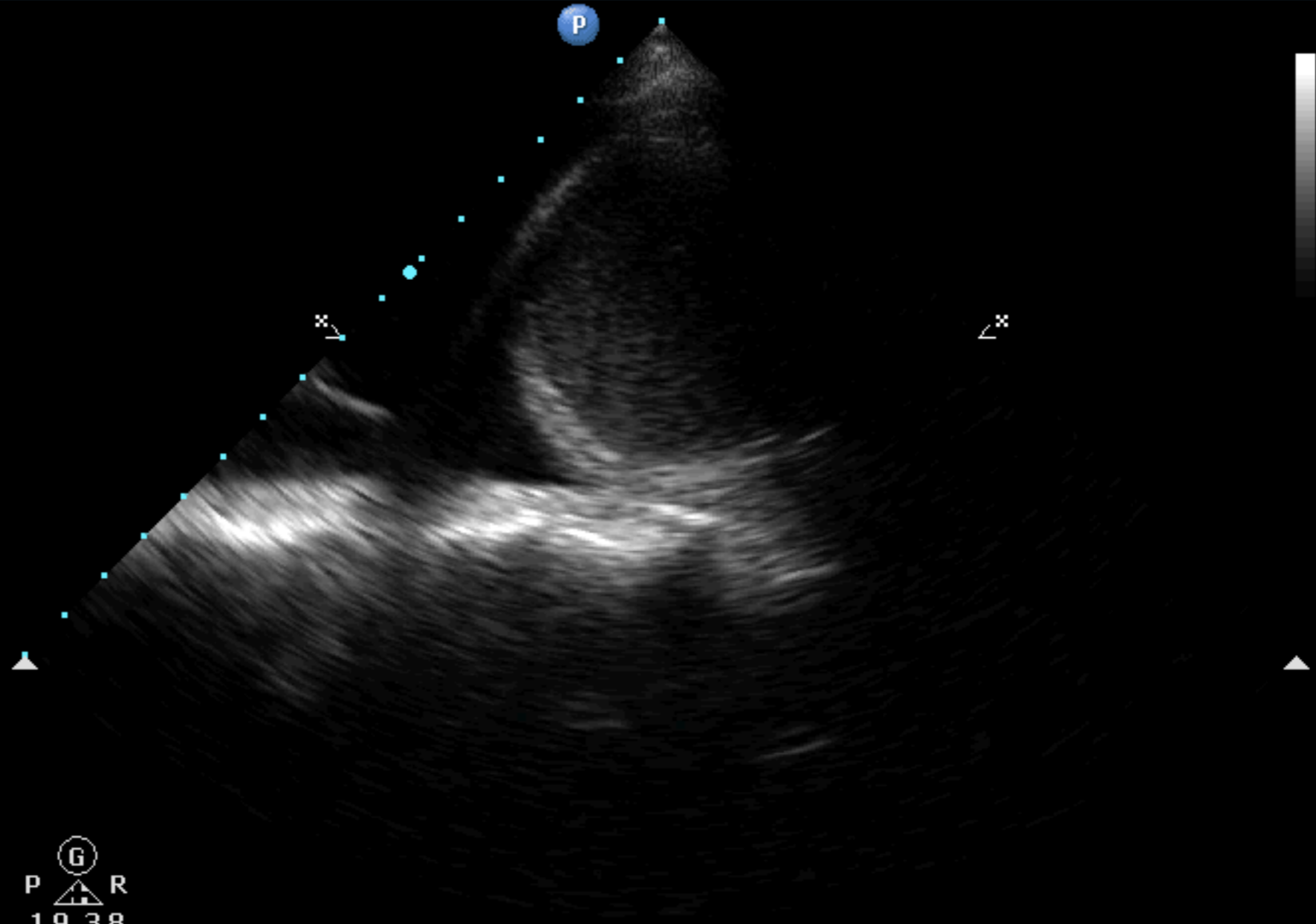
ED ECHO
S4-2
34Hz
16cm

2D
H3
Gn 45
232dB/C5
D/2/0



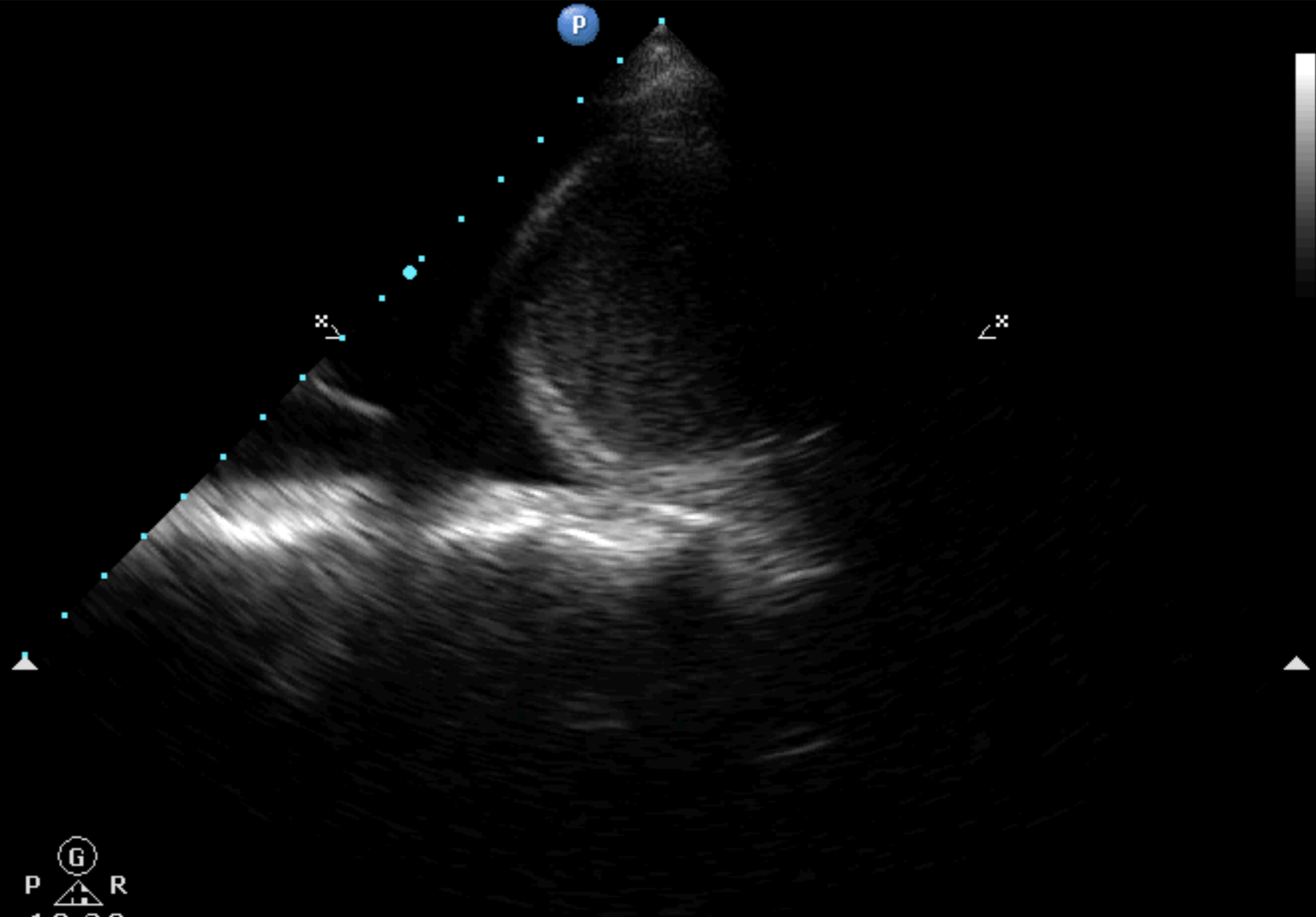
ED ECHO
S4-2
34Hz
16cm

2D
H3
Gn 45
232dB/C5
D/2/0



ED ECHO
S4-2
34Hz
16cm

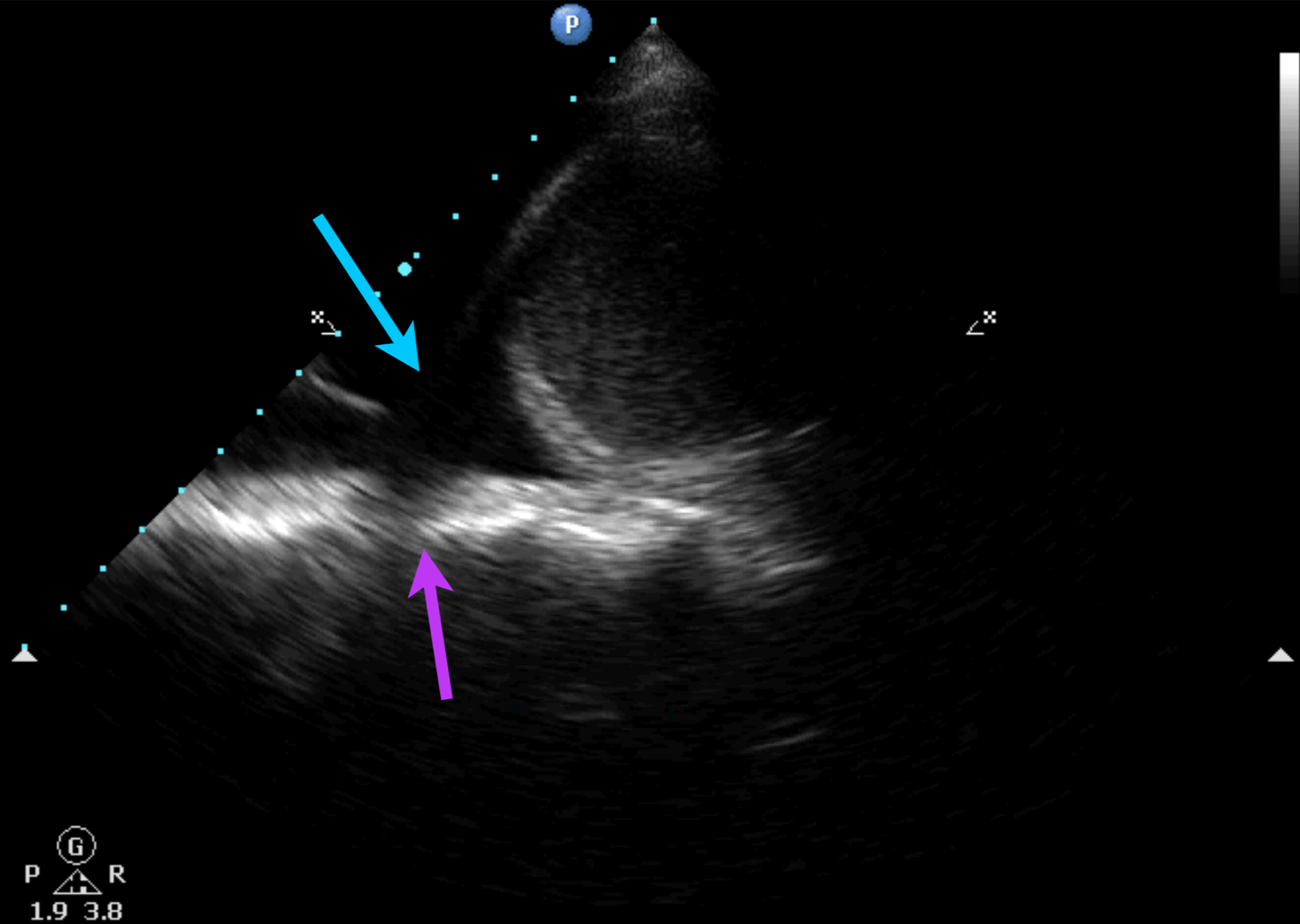
2D
H3
Gn 45
232dB/C5
D/2/0



Pleural effusion

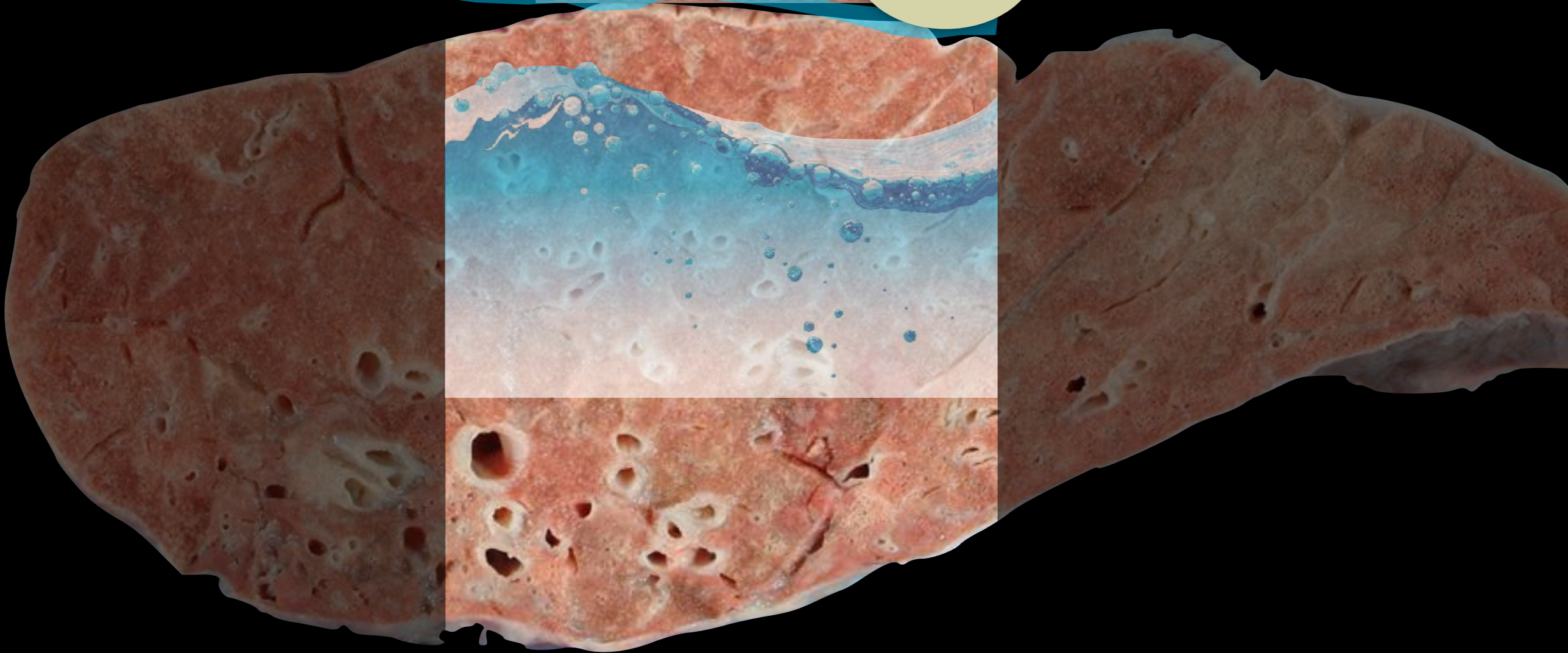
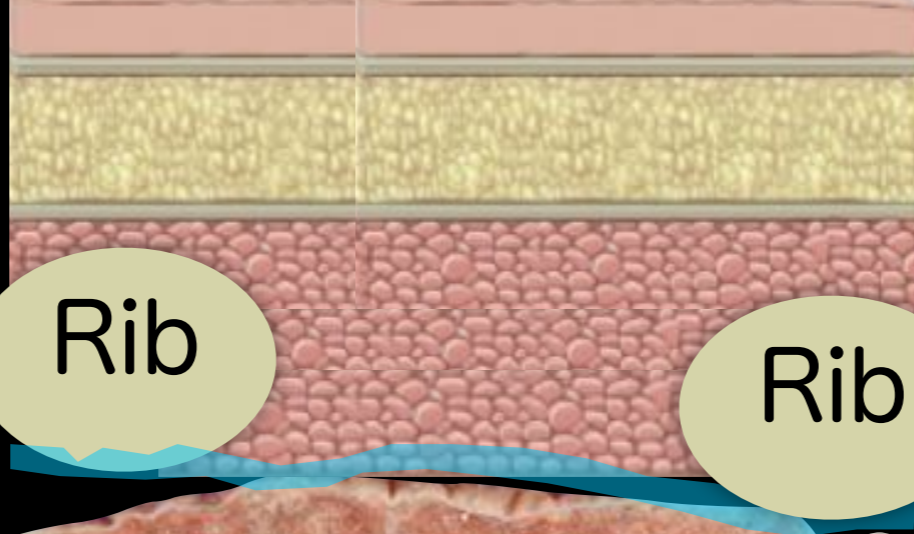
ED ECHO
S4-2
34Hz
16cm

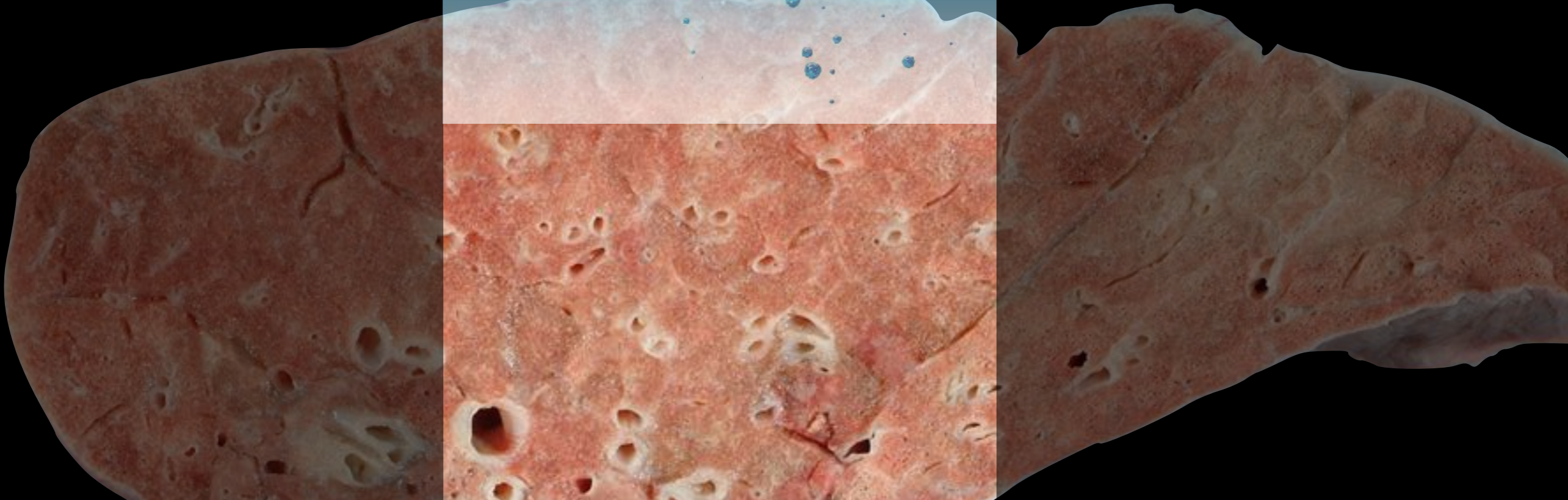


2D
H3
Gn 45
232dB/C5
D/2/0

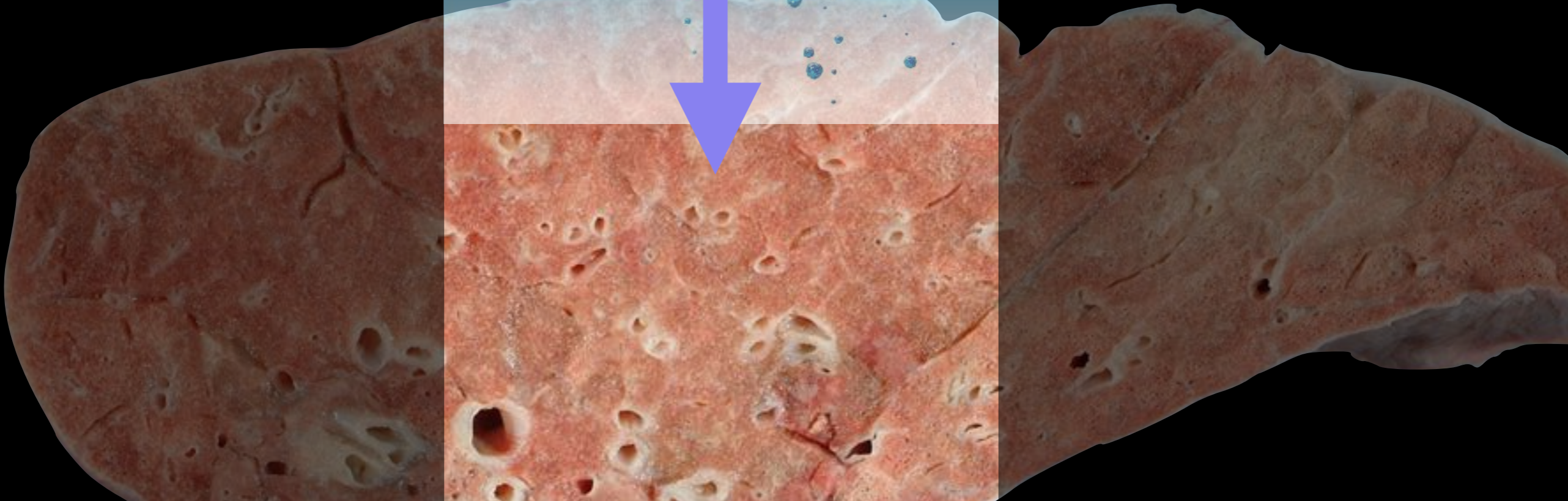
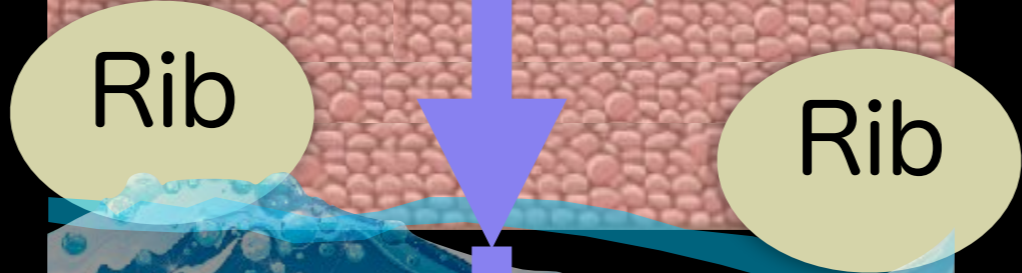



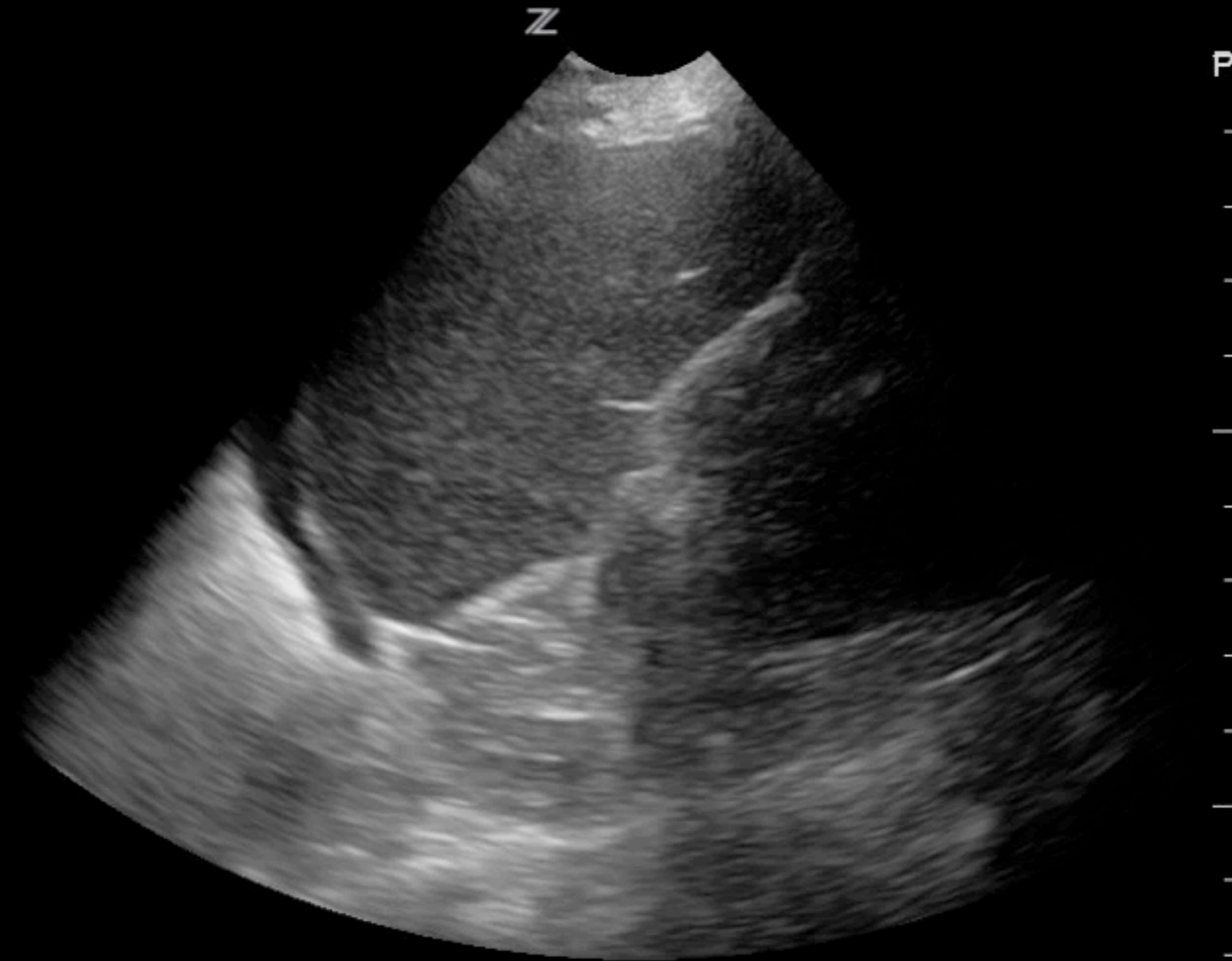Pleural effusion

(-) mirror image, (+) spine sign



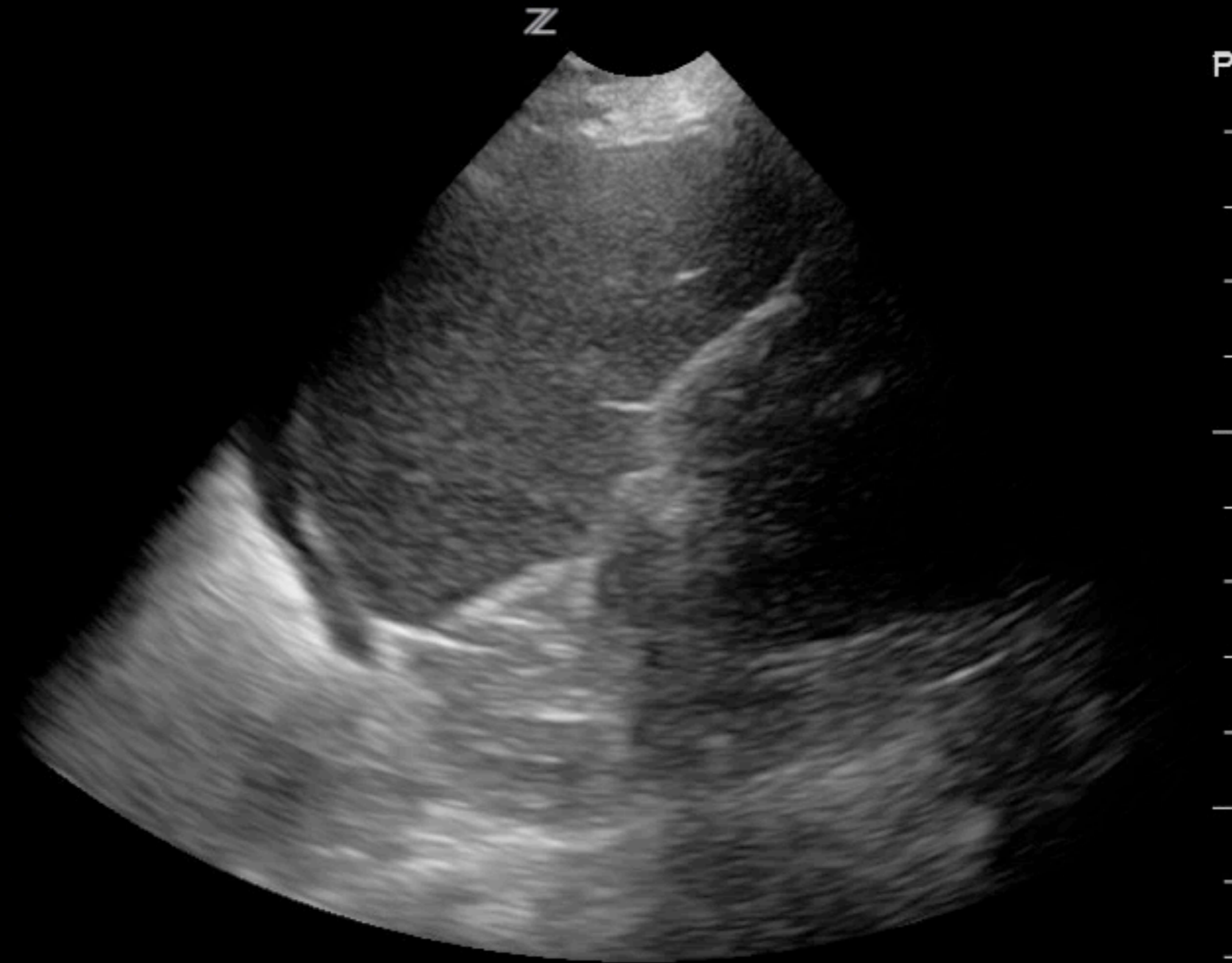





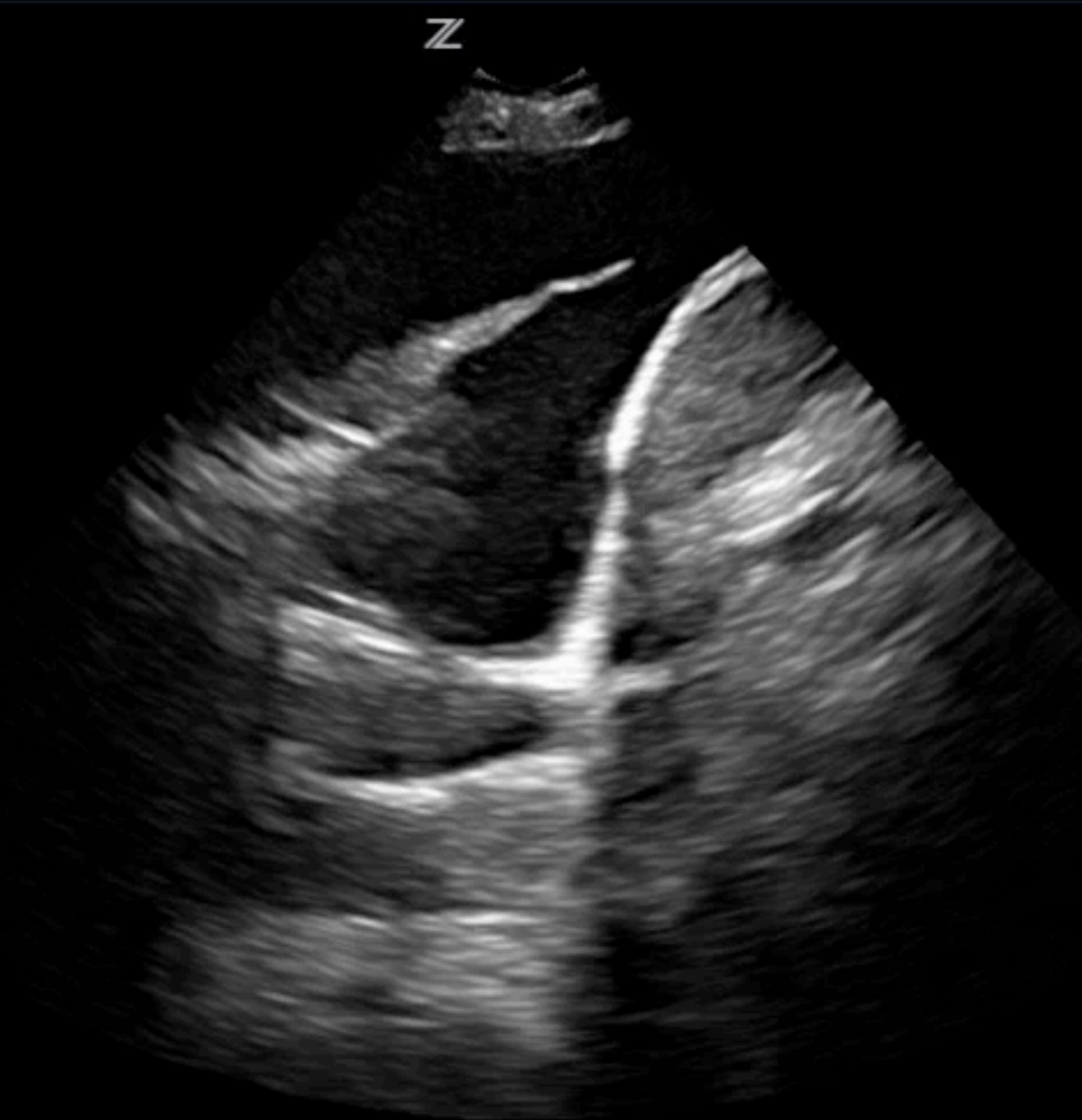Abd/General
P4-1c/CH4MHz
DR50/M2/P2
G78/E1/100%
MI1.5 TIs0.4
12.0 cm
18 Hz
ZSI 0

Pleural effusion



Abd/General
P4-1c/CH4MHz
DR50/M2/P2
G78/E1/100%
MI1.5 TIs0.4
12.0 cm
18 Hz
ZSI 0

Pleural effusion
Small



Card/General
P4-1c/H3.5MHz
- DR65/M3/P1
_G76/E2/100%
MI1.5 TIs0.3
18.0 cm
31 Hz
△ ZSI 0

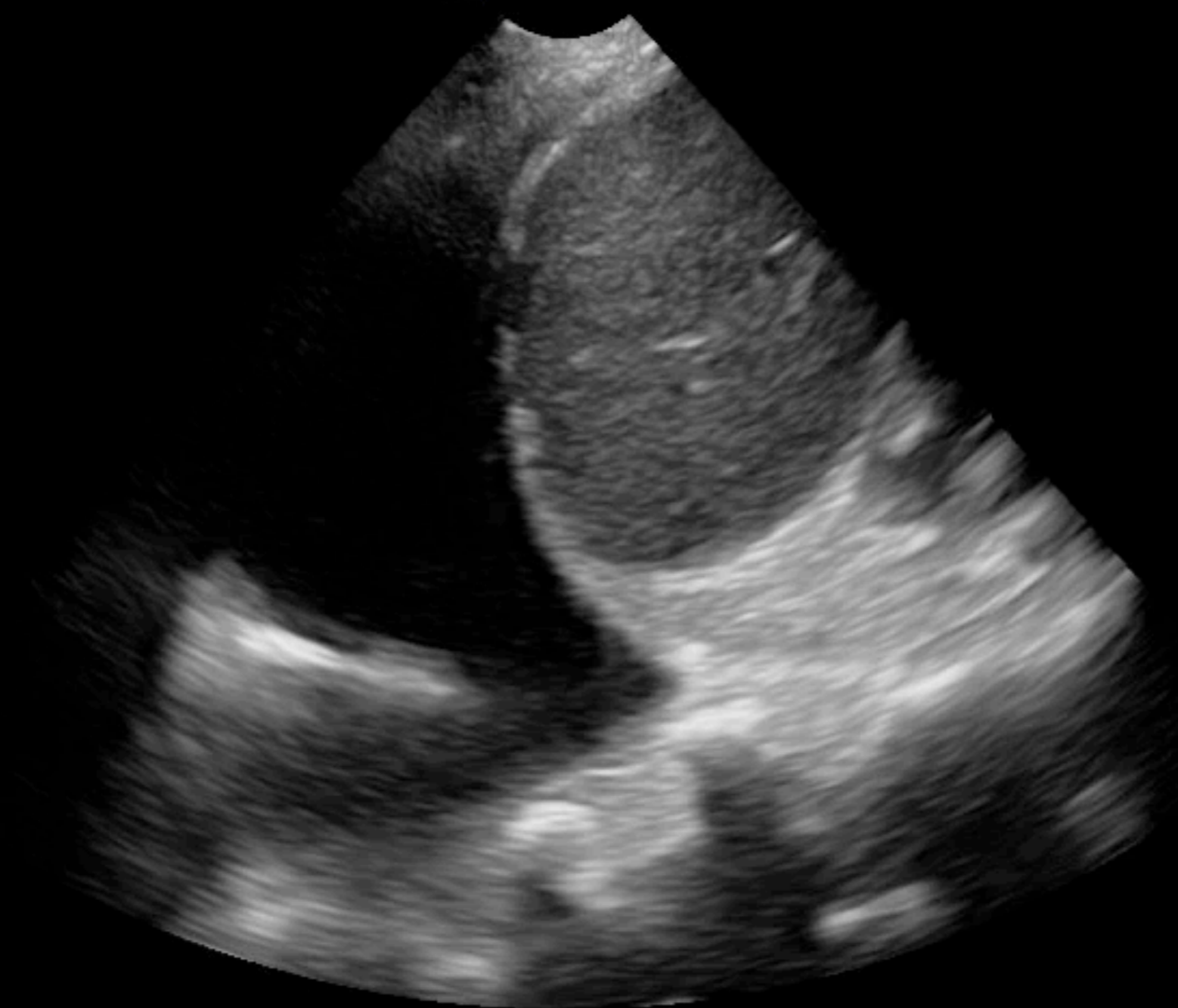Pleural effusion
Lung visualized




Card/General
P4-1c/H3.5MHz
- DR65/M3/P1
_G76/E2/100%
MI1.5 TIs0.3
18.0 cm
31 Hz
△ ZSI 0

Pleural effusion
Lung visualized

Z

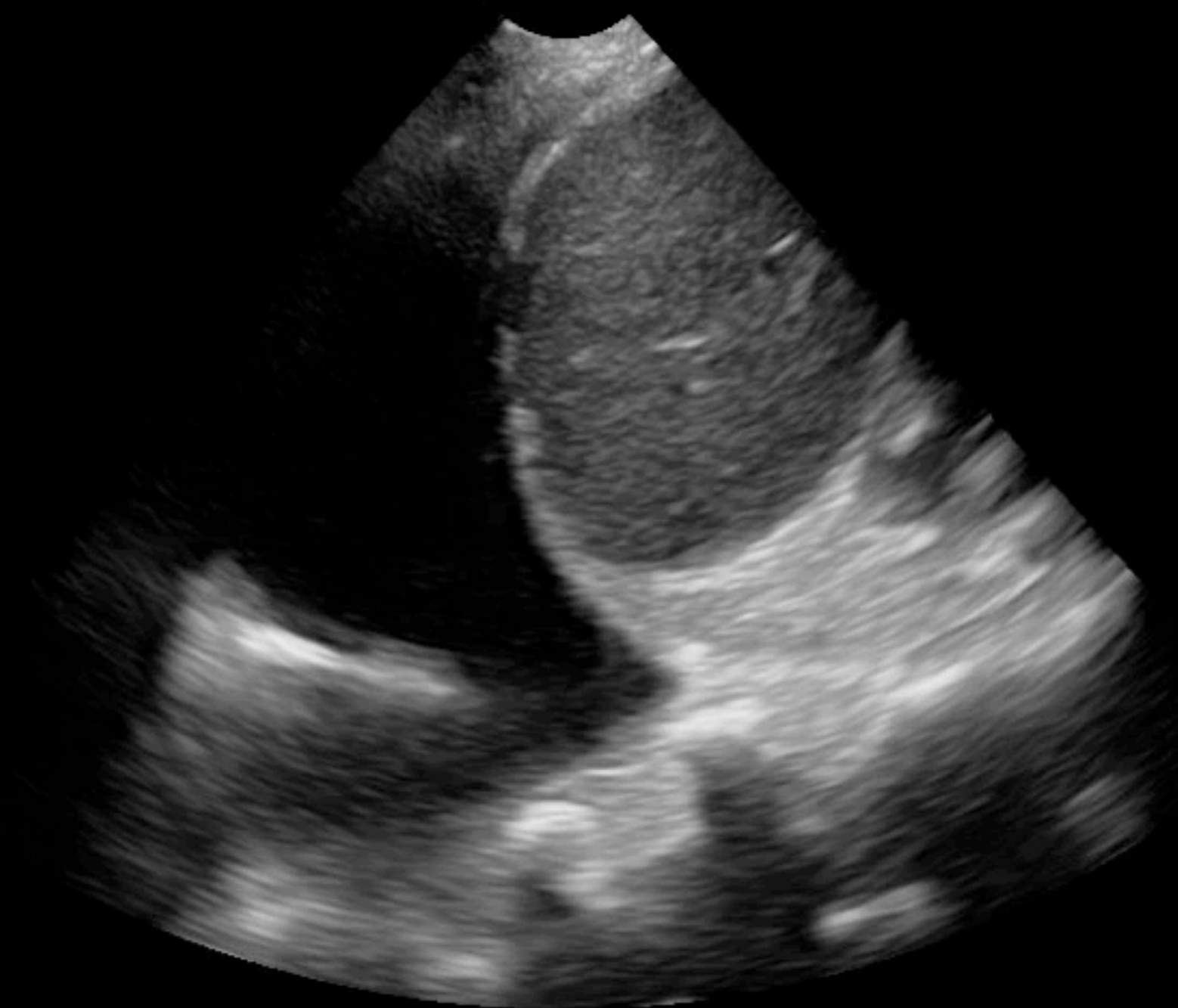


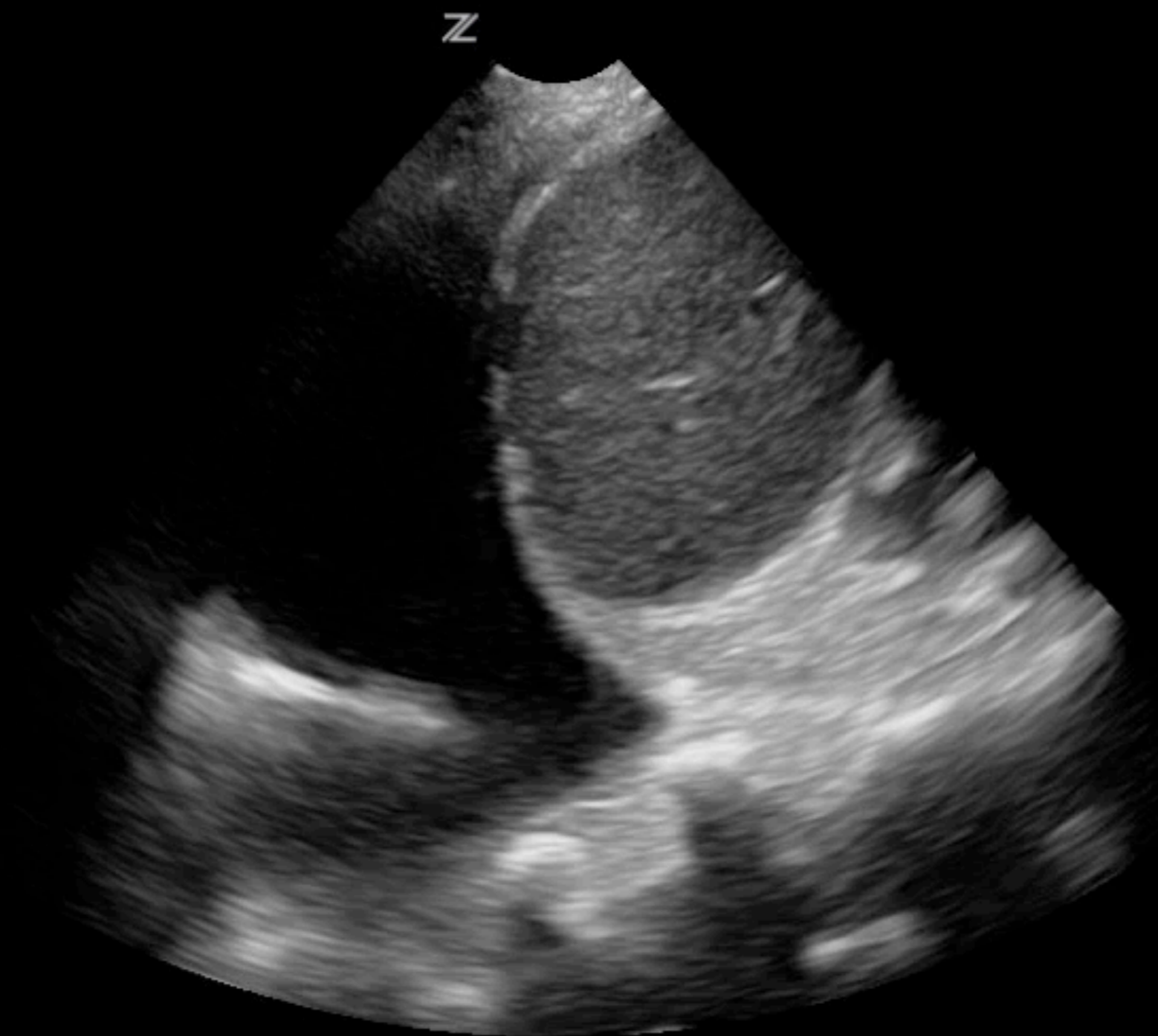Abd/General
P4-1c/CH4MHz
- DR50/M2/P2
- G82/E1/100%
- MI1.5 TIs0.5
14.0 cm
17 Hz
△ ZSI 0



Z

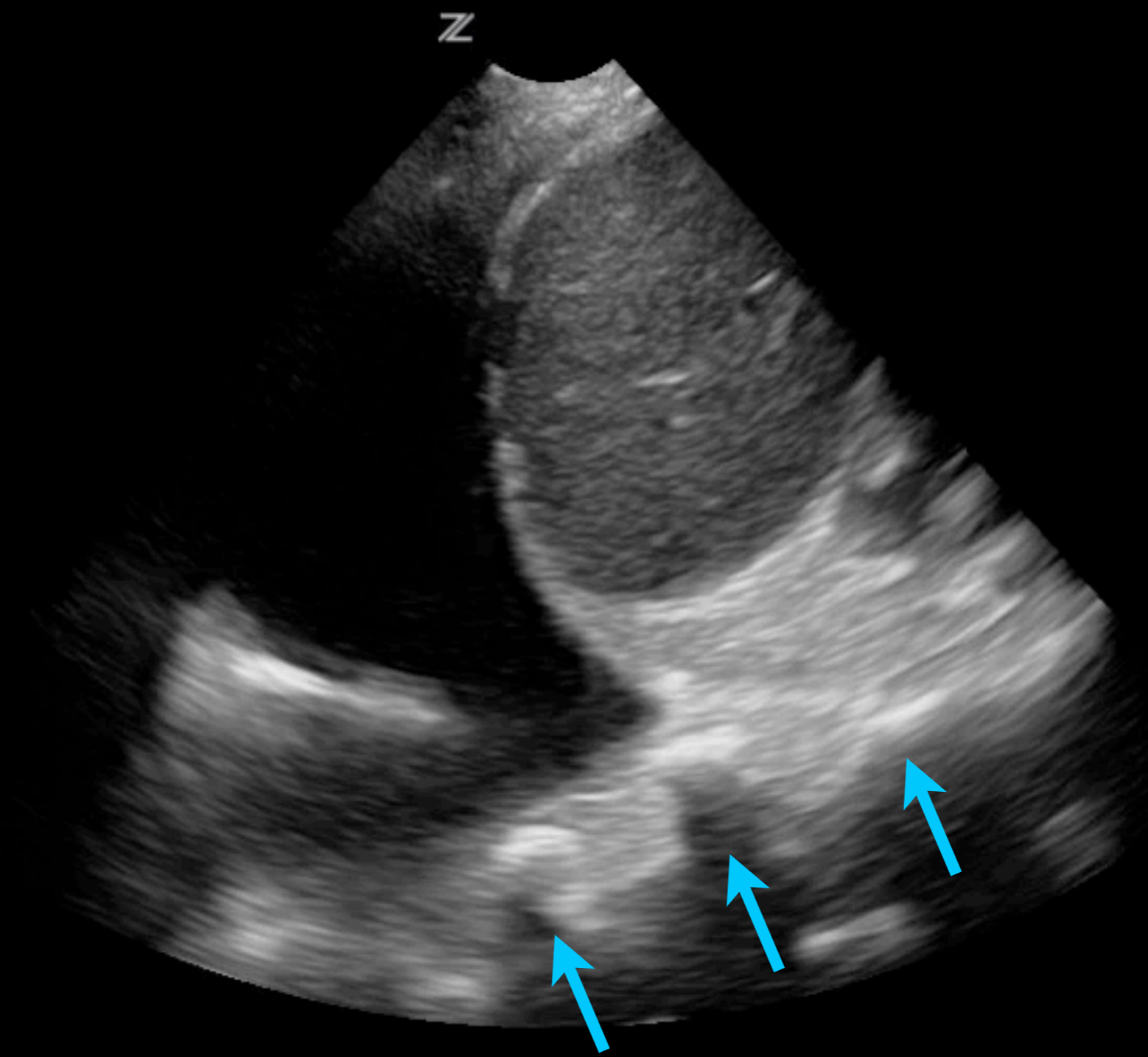
Abd/General
P4-1c/CH4MHz
- DR50/M2/P2
- G82/E1/100%
- MI1.5 TIs0.5
14.0 cm
17 Hz
△ ZSI 0





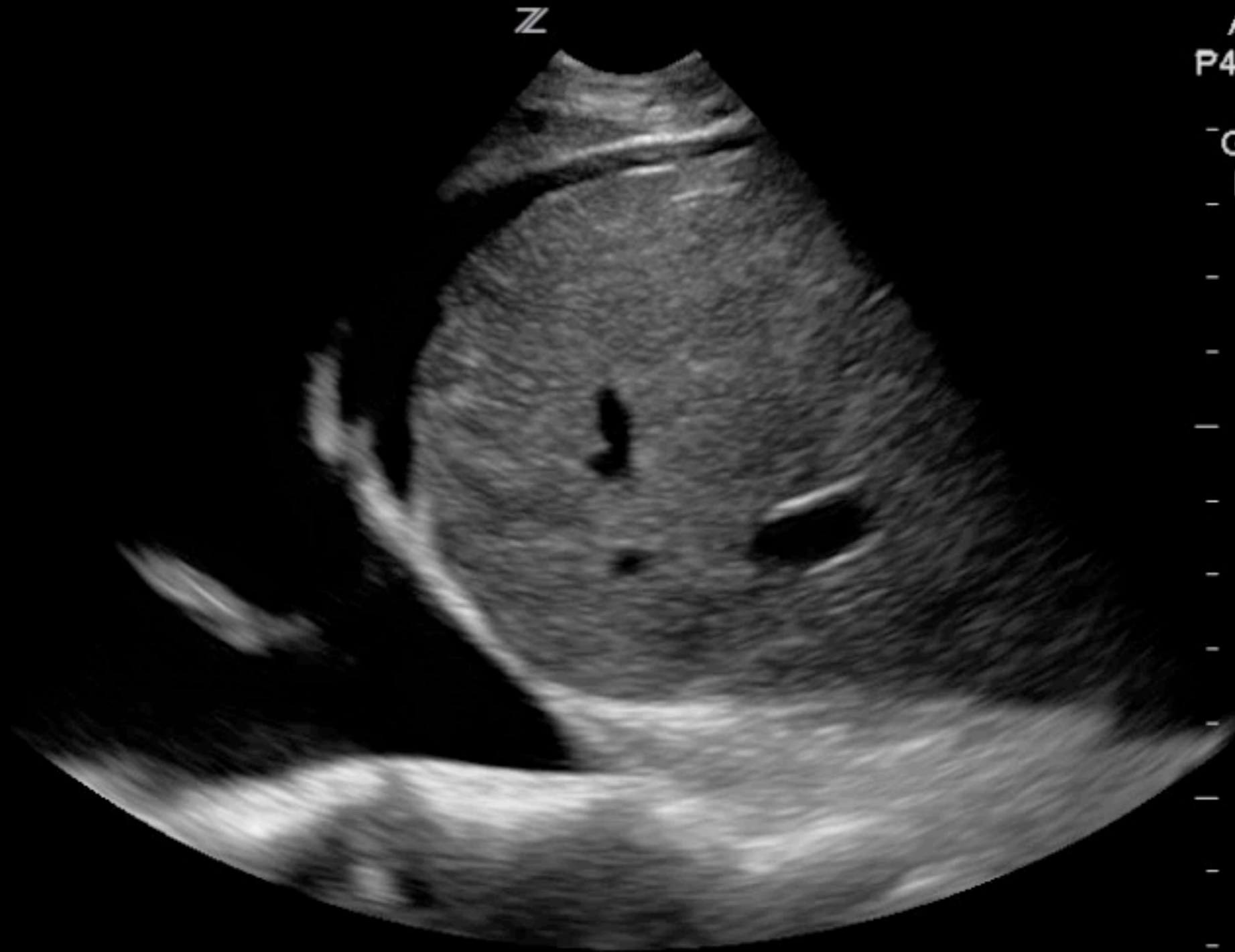Abd/General
P4-1c/CH4MHz
- DR50/M2/P2
- G82/E1/100%
- MI1.5 TIs0.5
14.0 cm
17 Hz
△ ZSI 0

Pleural effusion



Abd/General
P4-1c/CH4MHz
- DR50/M2/P2
G82/E1/100%
- MI1.5 TIs0.5
14.0 cm
17 Hz
△ ZSI 0

Pleural effusion
Note spine sign



Abd/General
P4-1c/CH4MHz
DR50/M2/P2
G72/E1/100%
MI1.5 TIs0.4
12.0 cm
18 Hz
ZSI 0

Pleural effusion

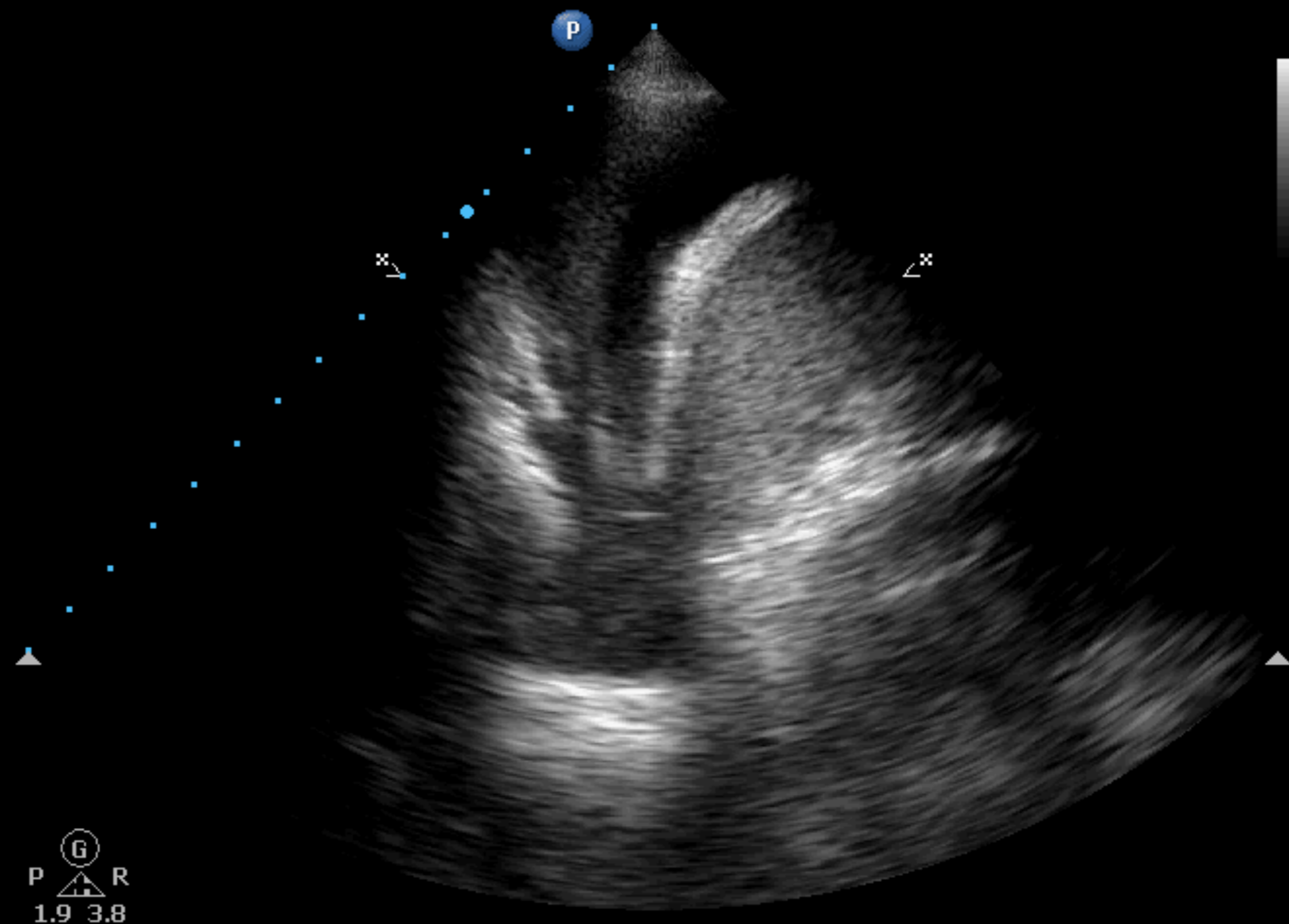


Abd/General
P4-1c/CH4MHz
DR50/M2/P2
G72/E1/100%
MI1.5 TIs0.4
12.0 cm
18 Hz
ZSI 0

Pleural effusion
Ascites present

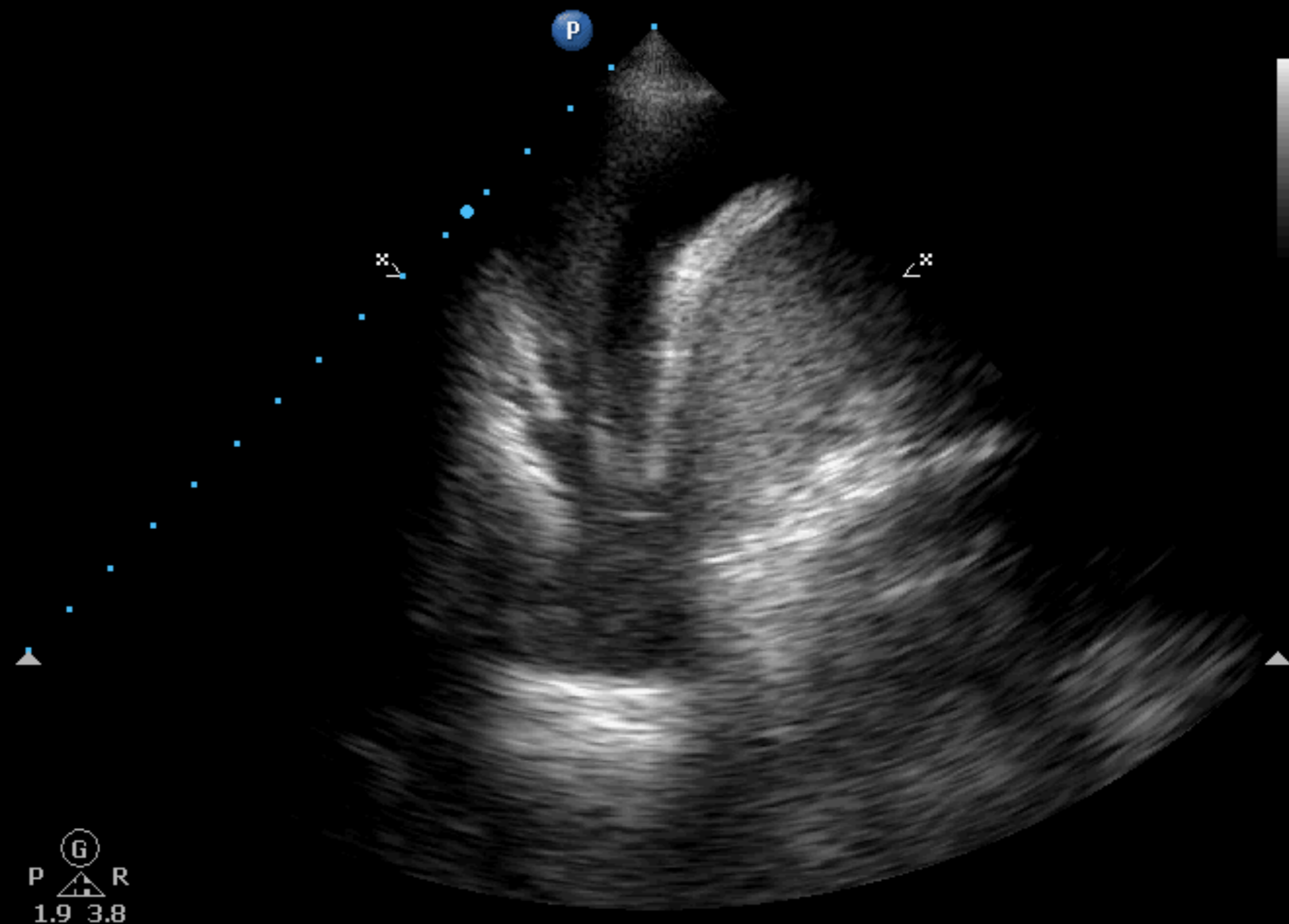
ED ECHO
S4-2
34Hz
15cm

2D
H3
Gn 45
232dB/C5
D/2/0



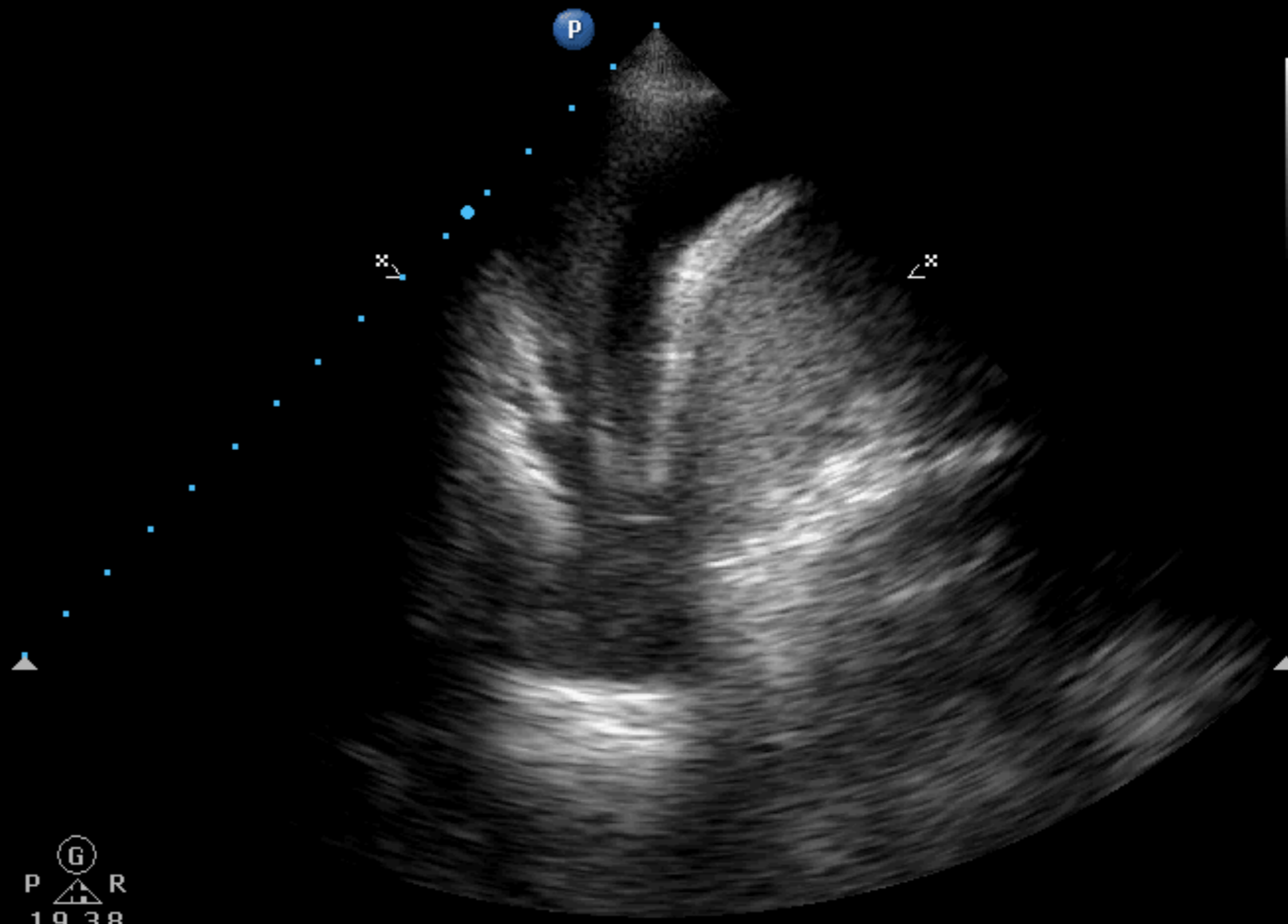
ED ECHO
S4-2
34Hz
15cm

2D
H3
Gn 45
232dB/C5
D/2/0



ED ECHO
S4-2
34Hz
15cm

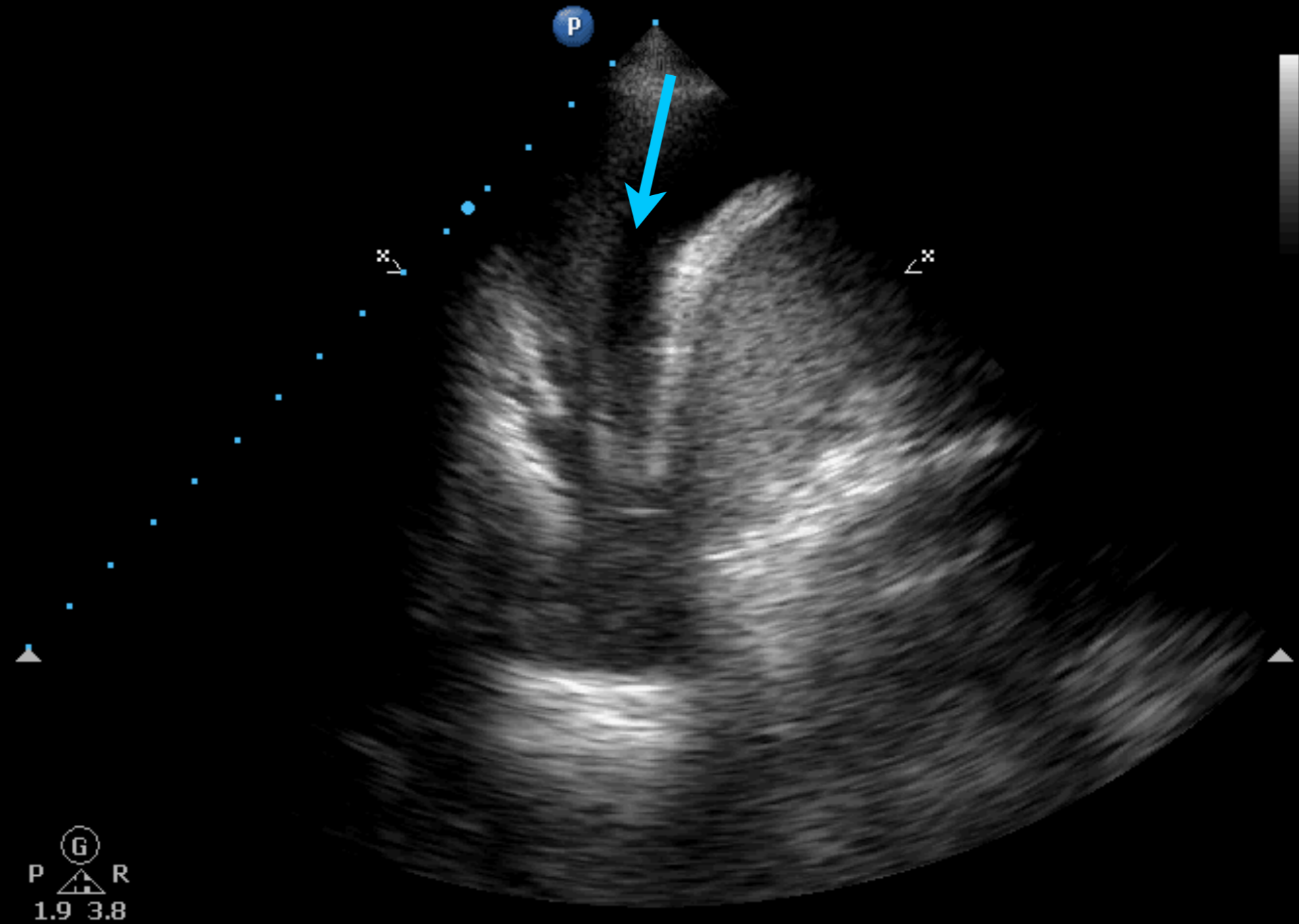
2D
H3
Gn 45
232dB/C5
D/2/0



Hemothorax

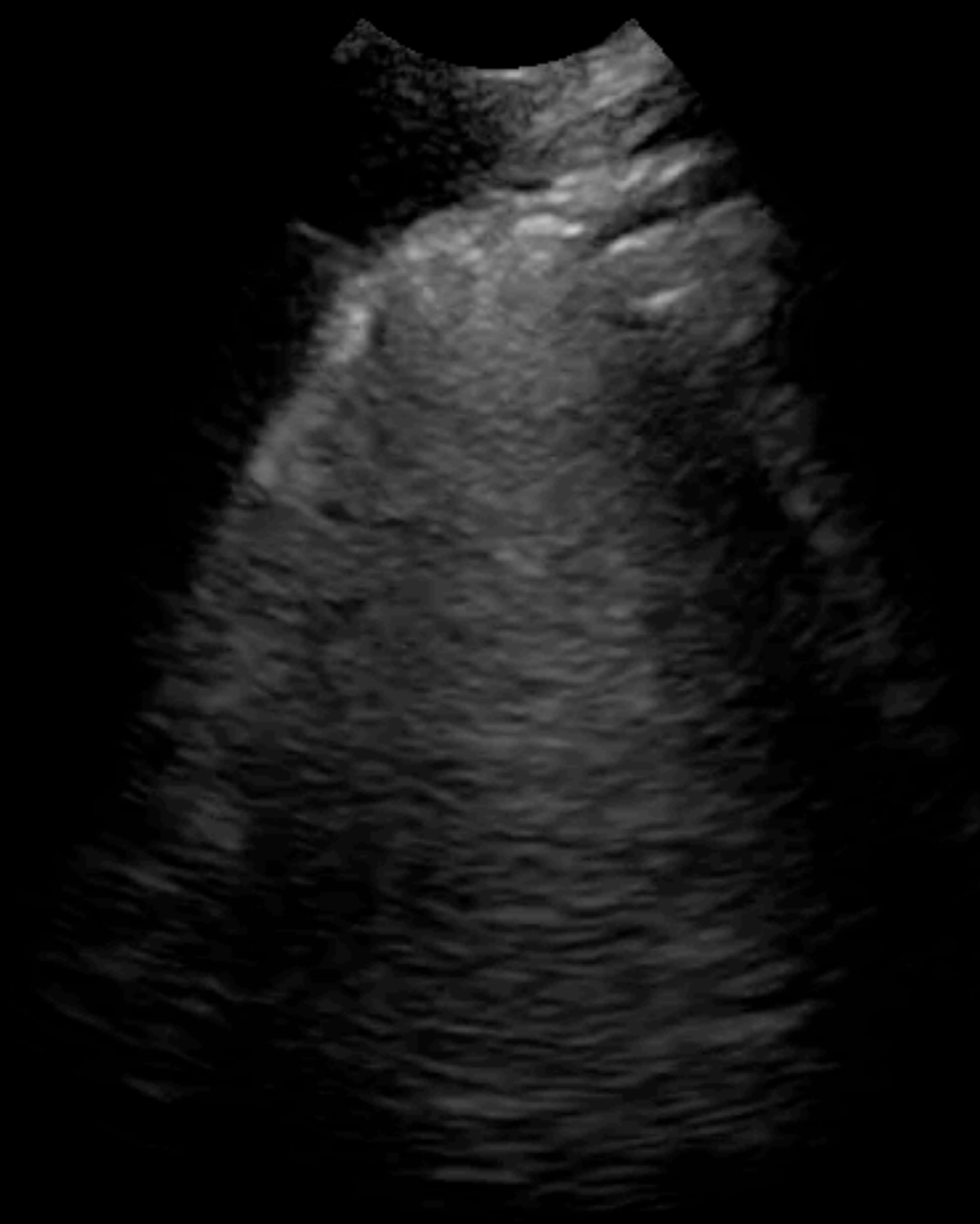ED ECHO
S4-2
34Hz
15cm

2D
H3
Gn 45
232dB/C5
D/2/0



Hemothorax
Note clotting

Z

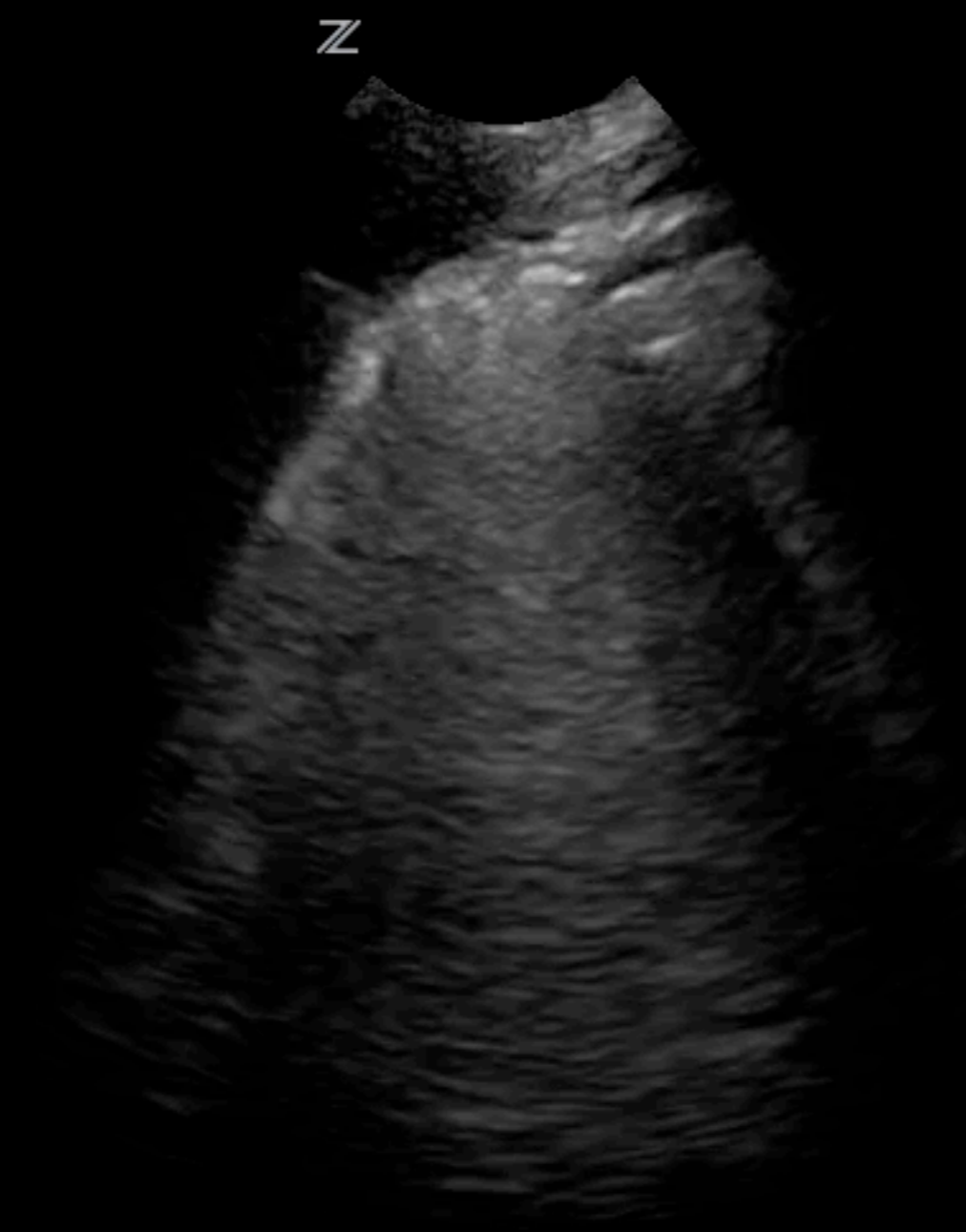


Abd/Thoracic
- P4-1c/4MHz
· DR50/M2/P2
G70/E1/100%
- MI1.4 TIs0.8
· 8.0 cm
- 23 Hz
· ZSI 0
- **Image**

Z

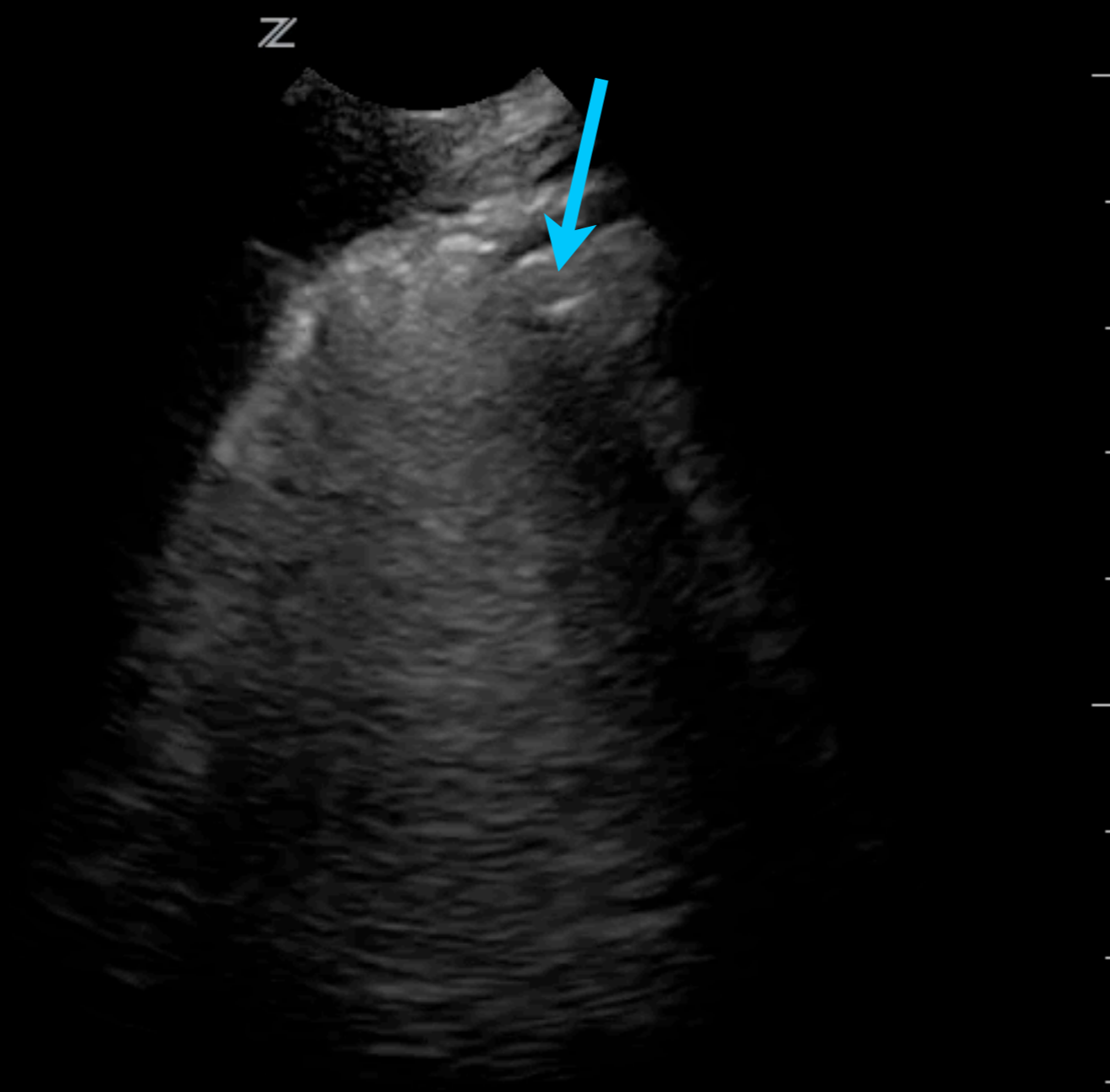

Abd/Thoracic
- P4-1c/4MHz
· DR50/M2/P2
· G70/E1/100%
- MI1.4 TIs0.8
· 8.0 cm
- 23 Hz
· ZSI 0
- **Image**



Abd/Thoracic
- P4-1c/4MHz
· DR50/M2/P2
· G70/E1/100%
- MI1.4 TIs0.8
· 8.0 cm
- 23 Hz
· ZSI 0
- **Image**

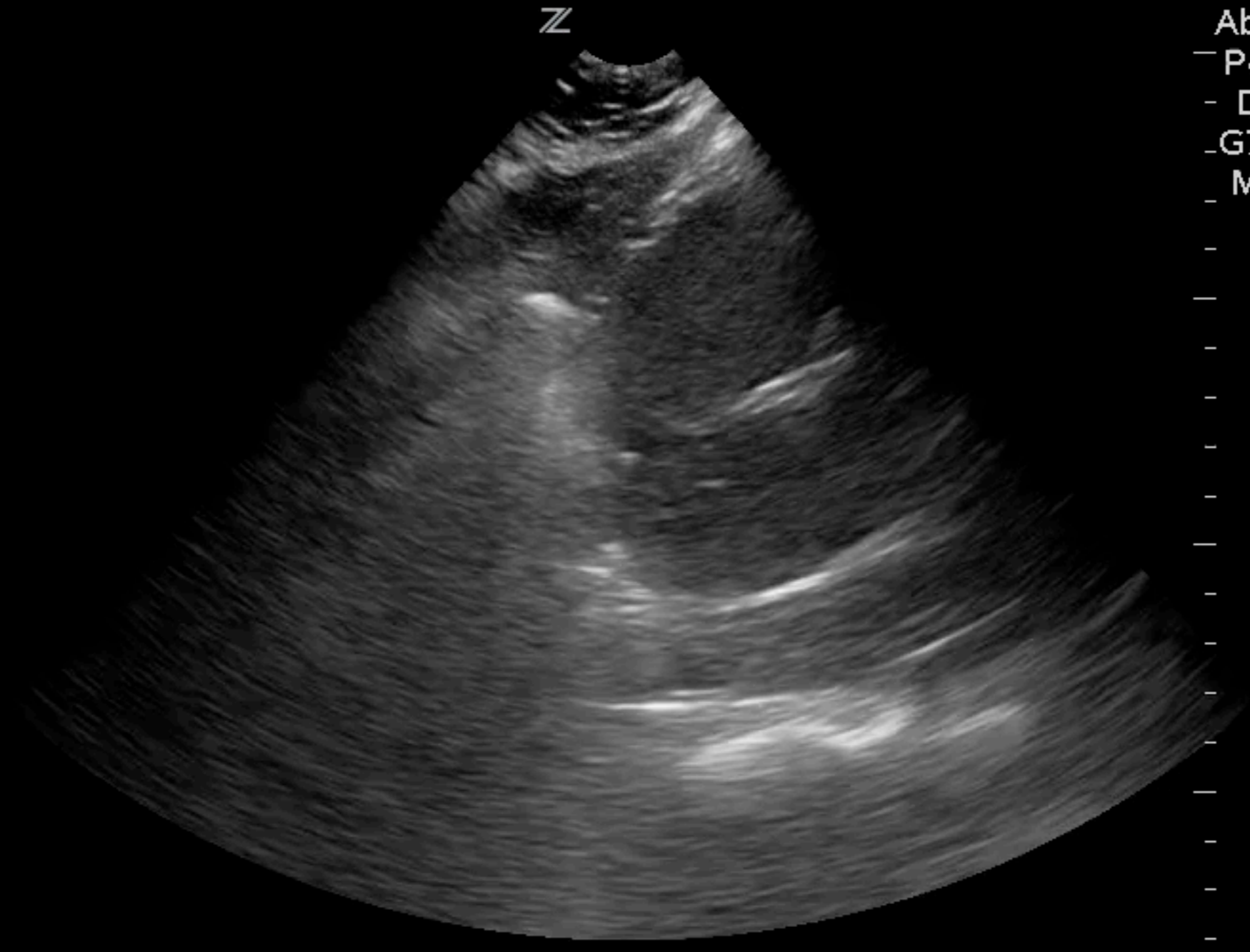
Continuum




Abd/Thoracic
- P4-1c/4MHz
· DR50/M2/P2
G70/E1/100%
- MI1.4 TIs0.8
· 8.0 cm
- 23 Hz
· ZSI 0
- **Image**

Continuum

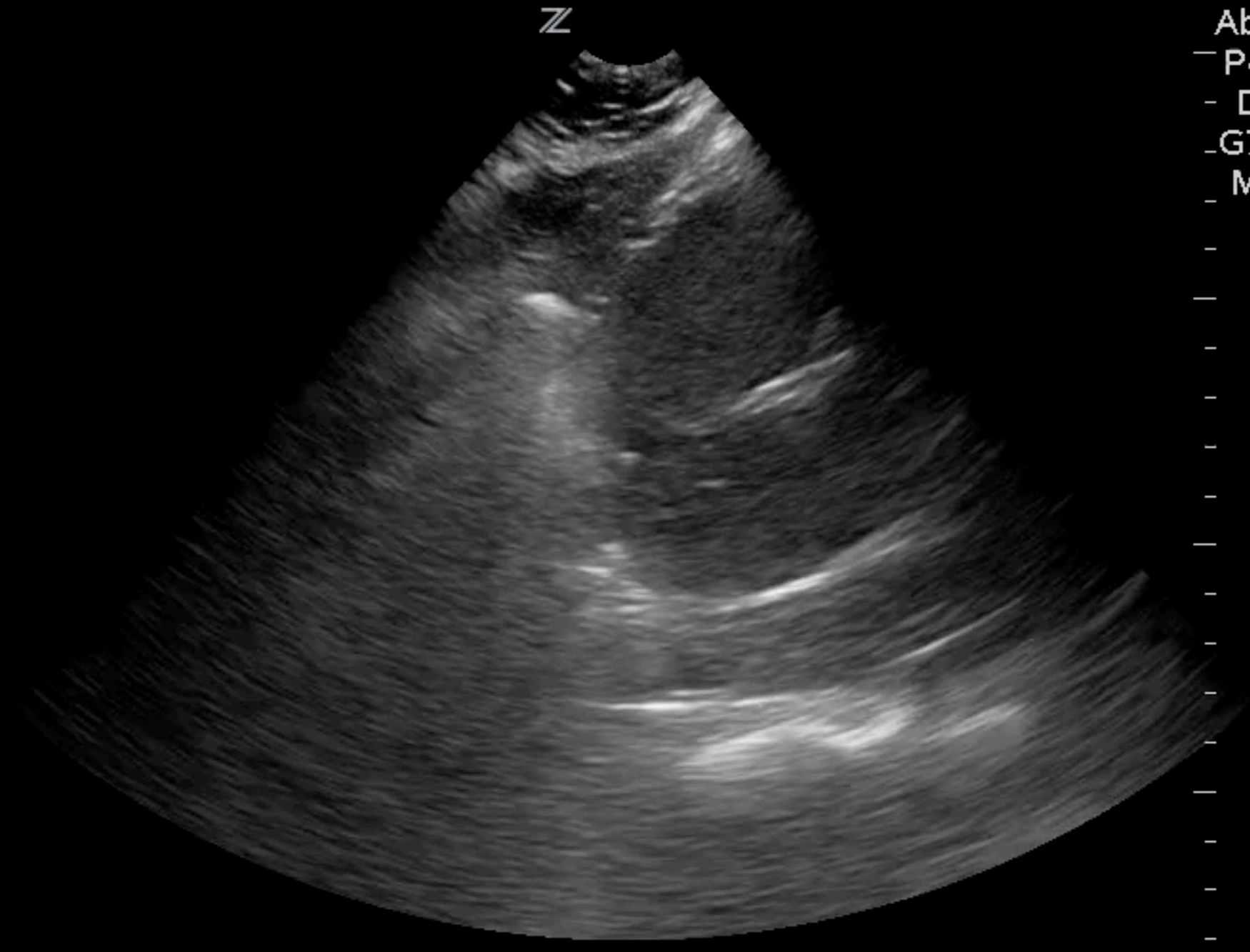
B-lines, consolidation, effusion




Z

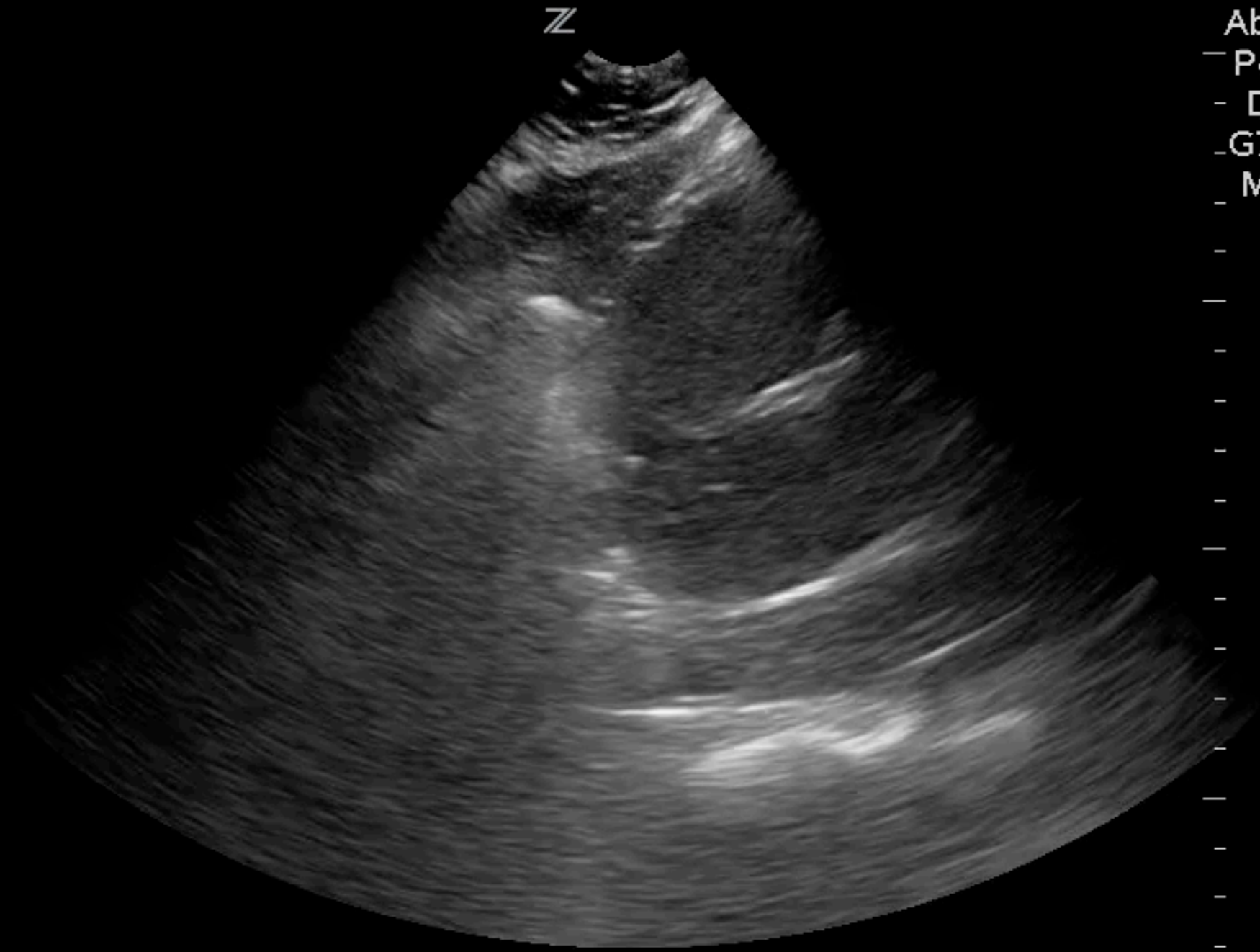Abd/Thoracic
- P4-1c/4MHz
- DR50/M2/P2
- G78/E1/100%
- MI1.5 TIs1.0
- 18.0 cm
- 20 Hz
-  ZSI 0
- **Image**


Consolidations



Abd/Thoracic
- P4-1c/4MHz
- DR50/M2/P2
- G78/E1/100%
- MI1.5 TIs1.0
- 18.0 cm
- 20 Hz
-  ZSI 0
- **Image**

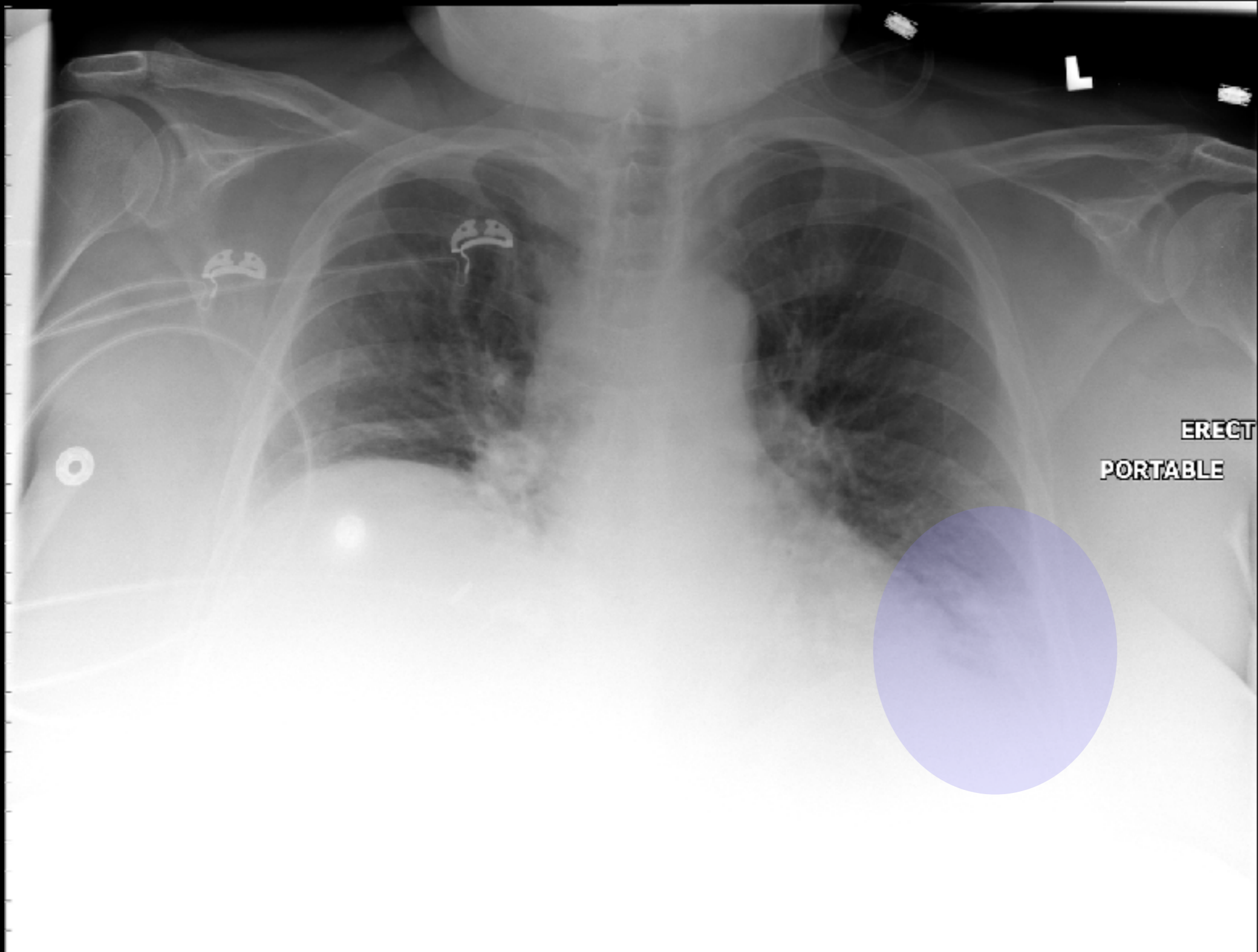
Consolidations



Abd/Thoracic
- P4-1c/4MHz
- DR50/M2/P2
- G78/E1/100%
- MI1.5 TIs1.0
- 18.0 cm
- 20 Hz
-  ZSI 0
- **Image**

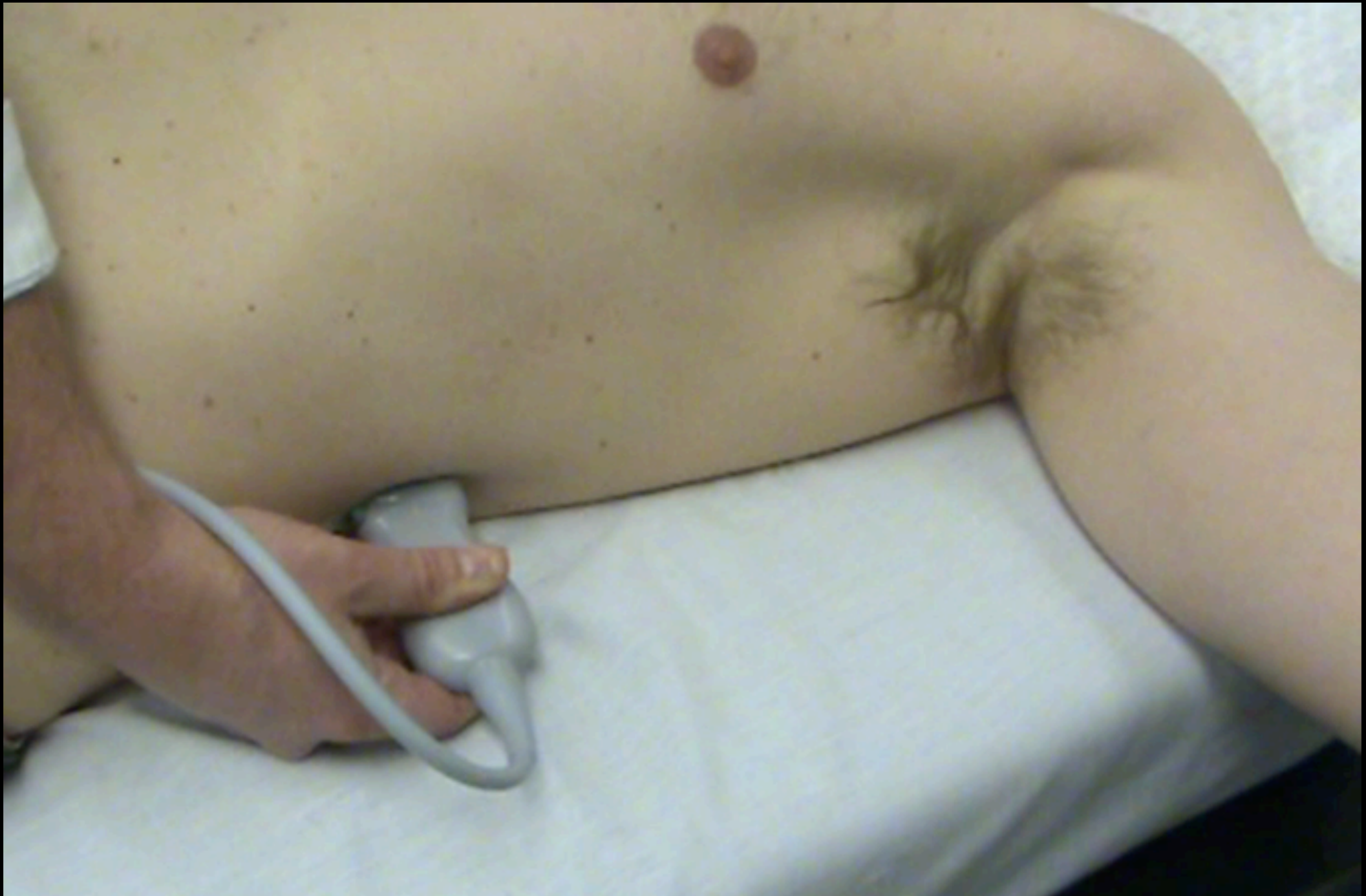Consolidations

Pneumonia

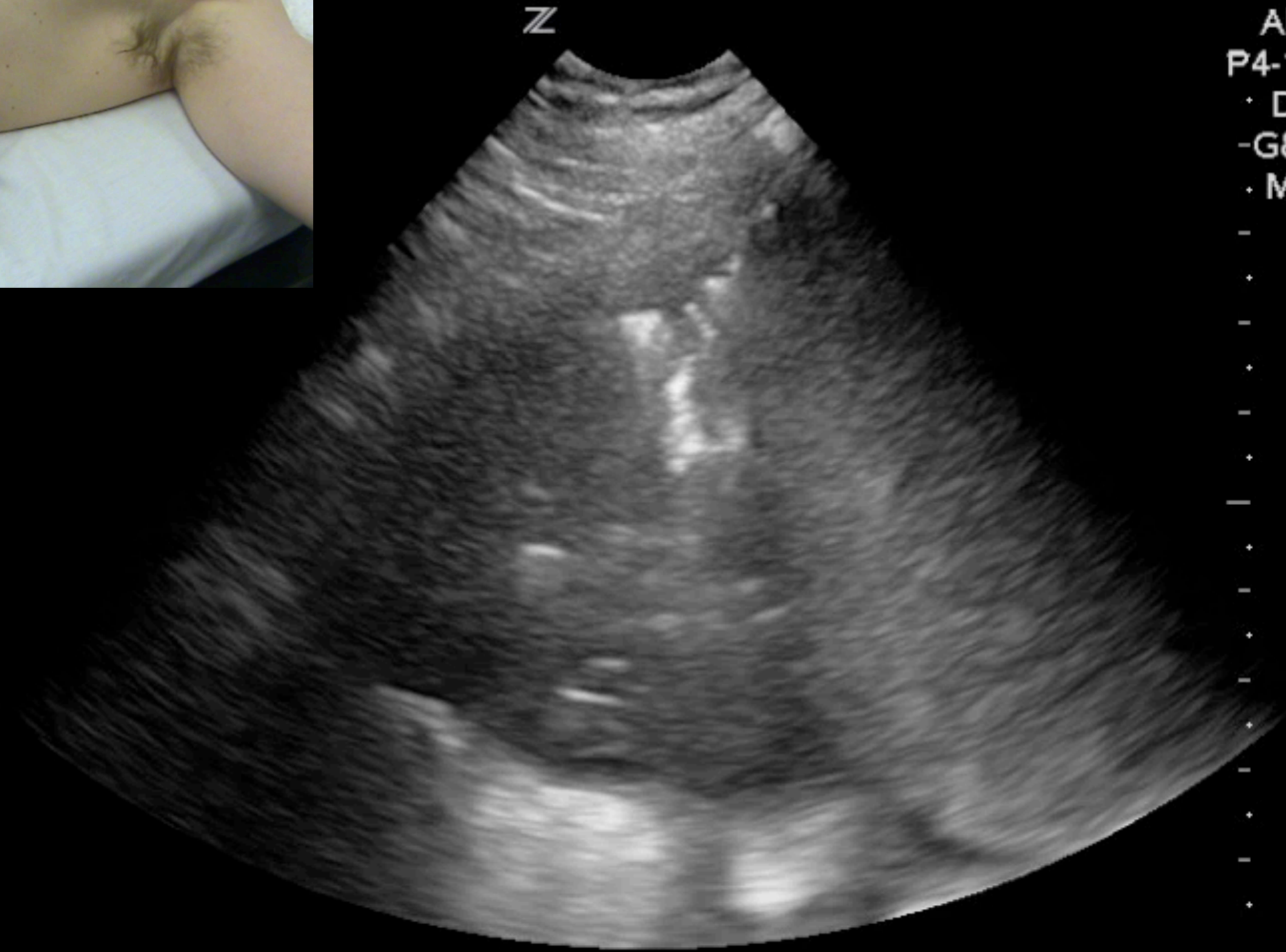
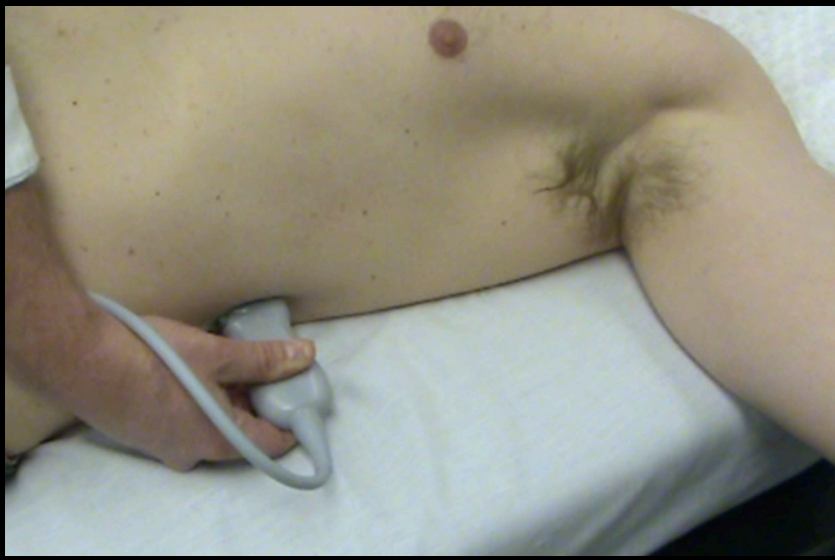

Consolidations

Pneumonia

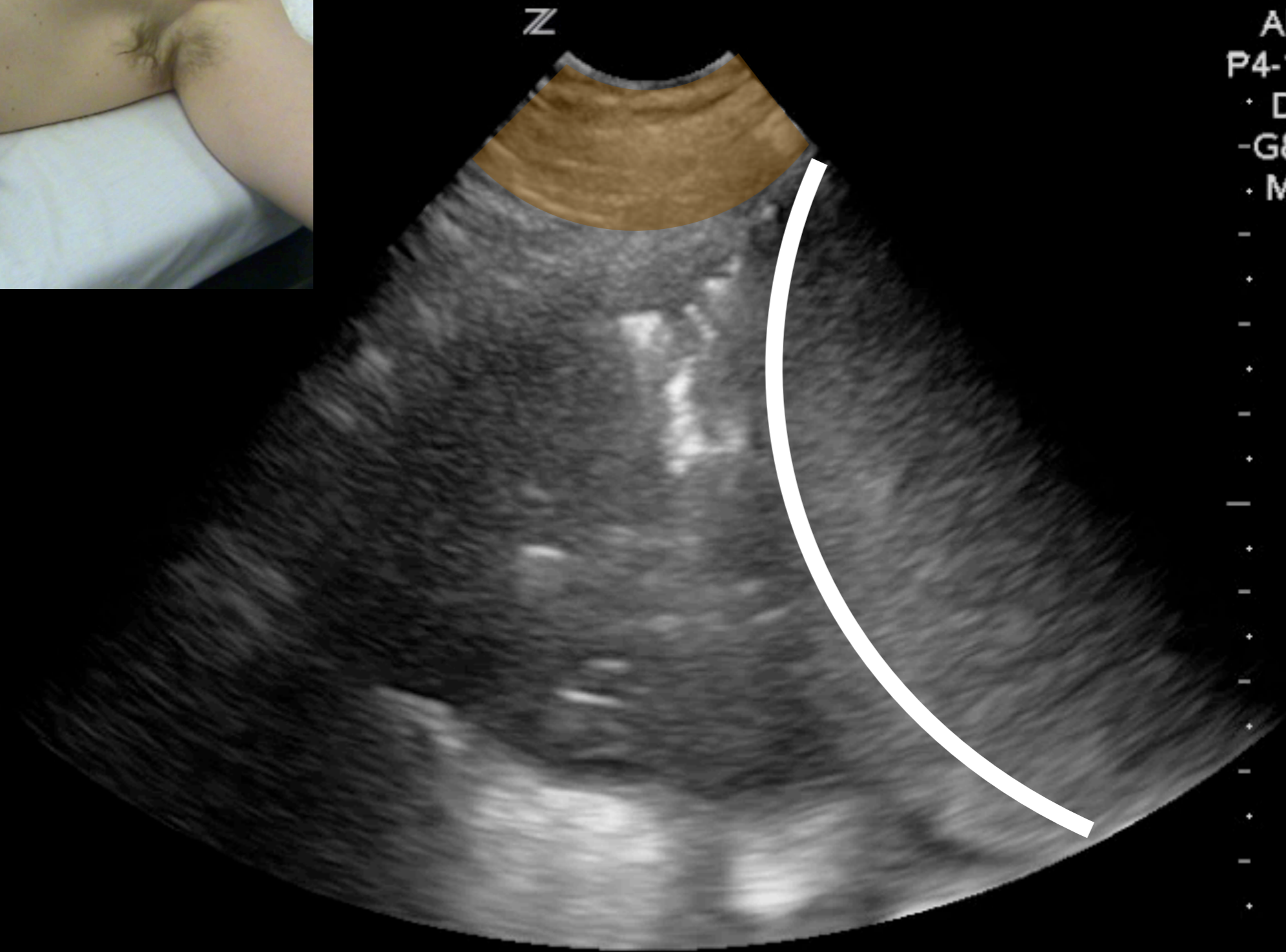
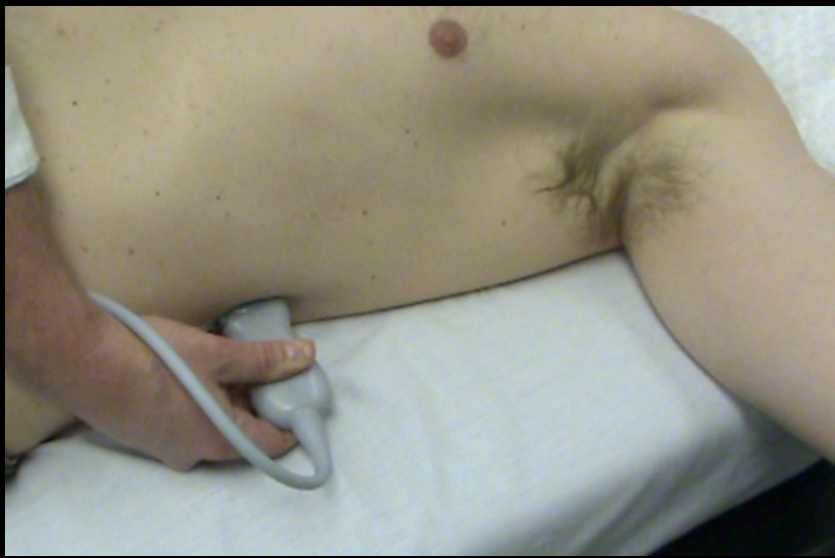

Pneumonia



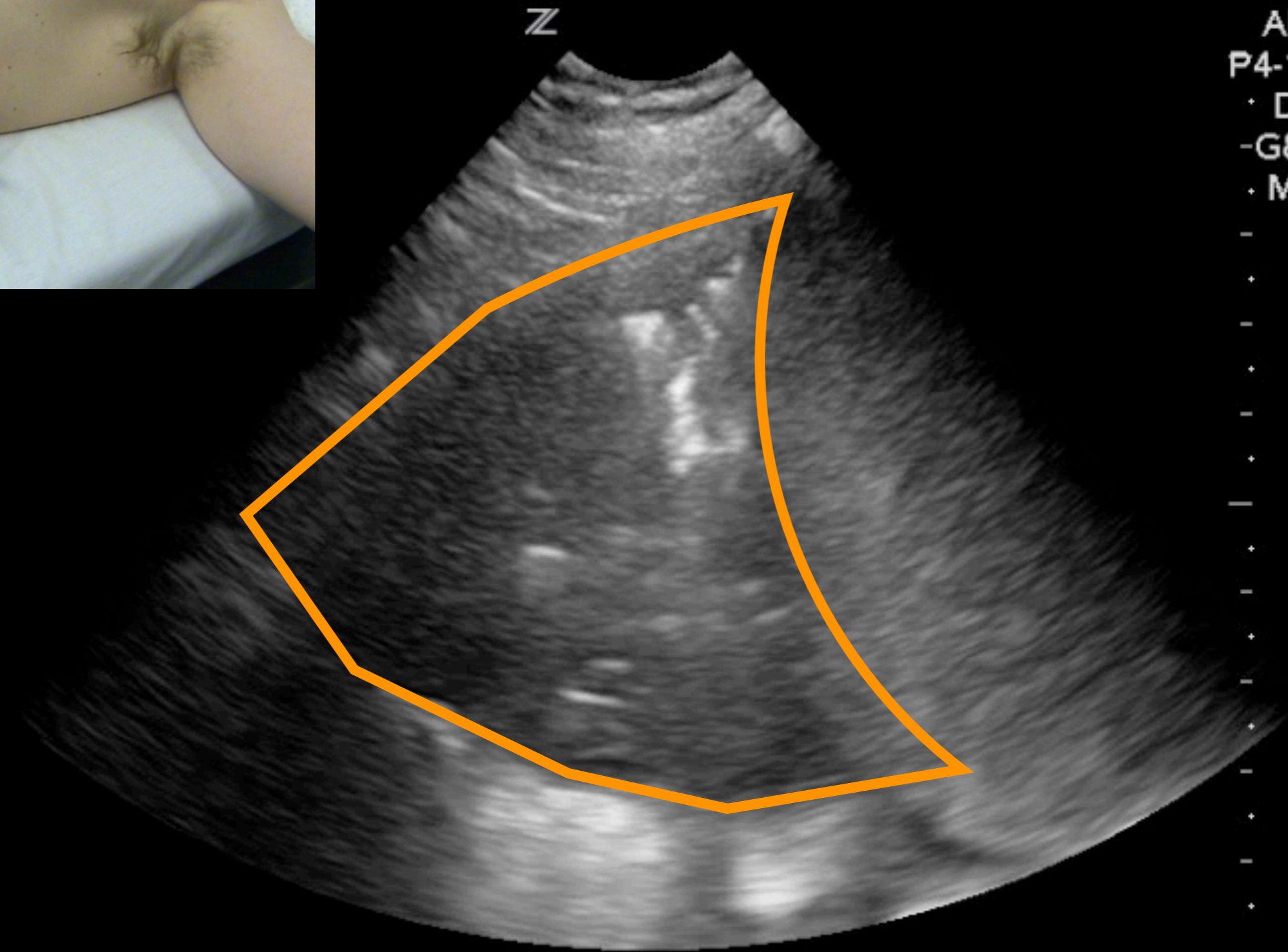
Abd/General
P4-1c/CH4MHz
· DR50/M2/P2
-G82/E1/100%
· MI1.5 TIs0.4
- 10.0 cm
· 17 Hz
△ ZSI 0
Image

Pneumonia



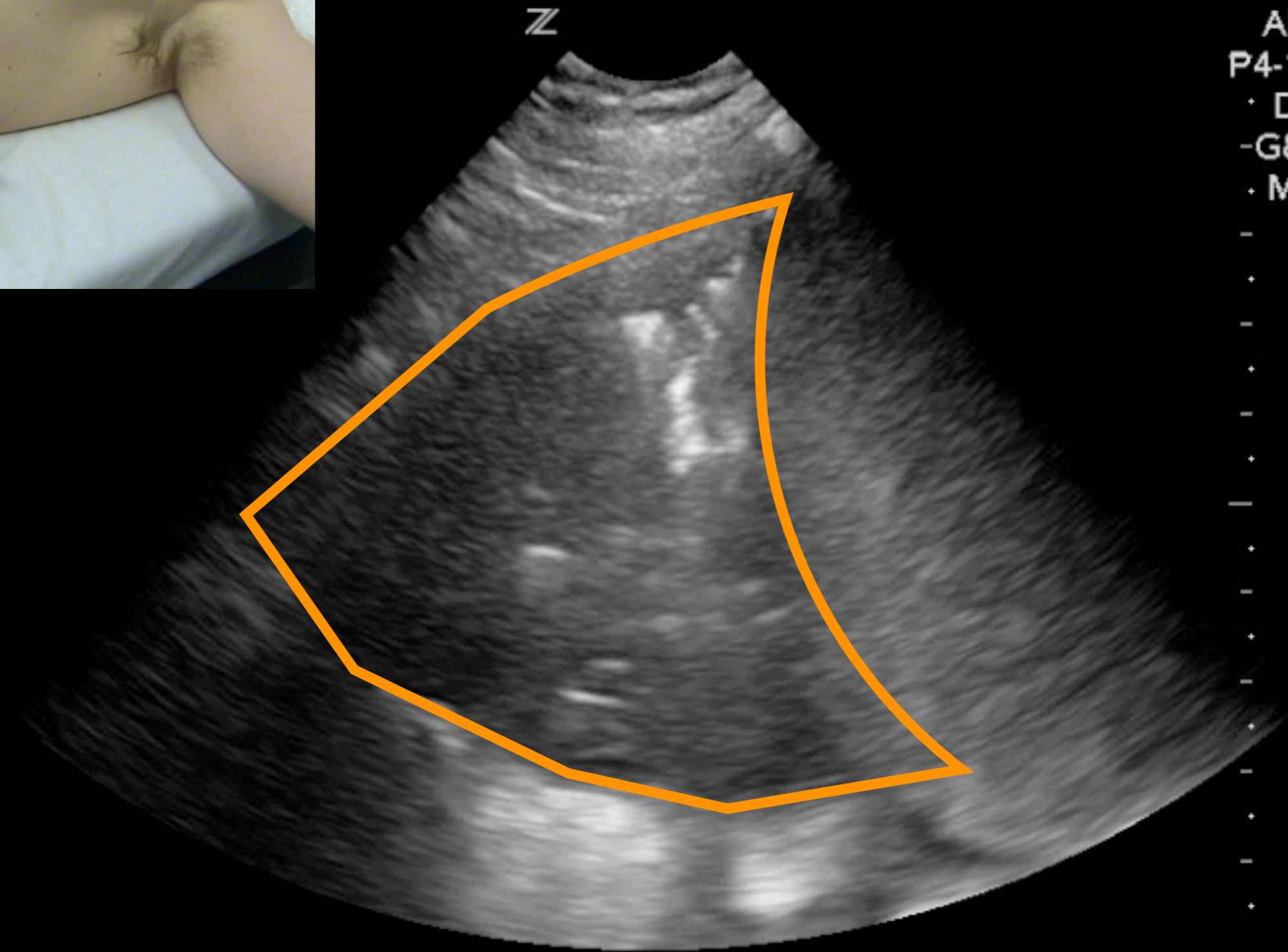
Abd/General
P4-1c/CH4MHz
· DR50/M2/P2
-G82/E1/100%
· MI1.5 TIs0.4
- 10.0 cm
· 17 Hz
△ ZSI 0
Image

Pneumonia



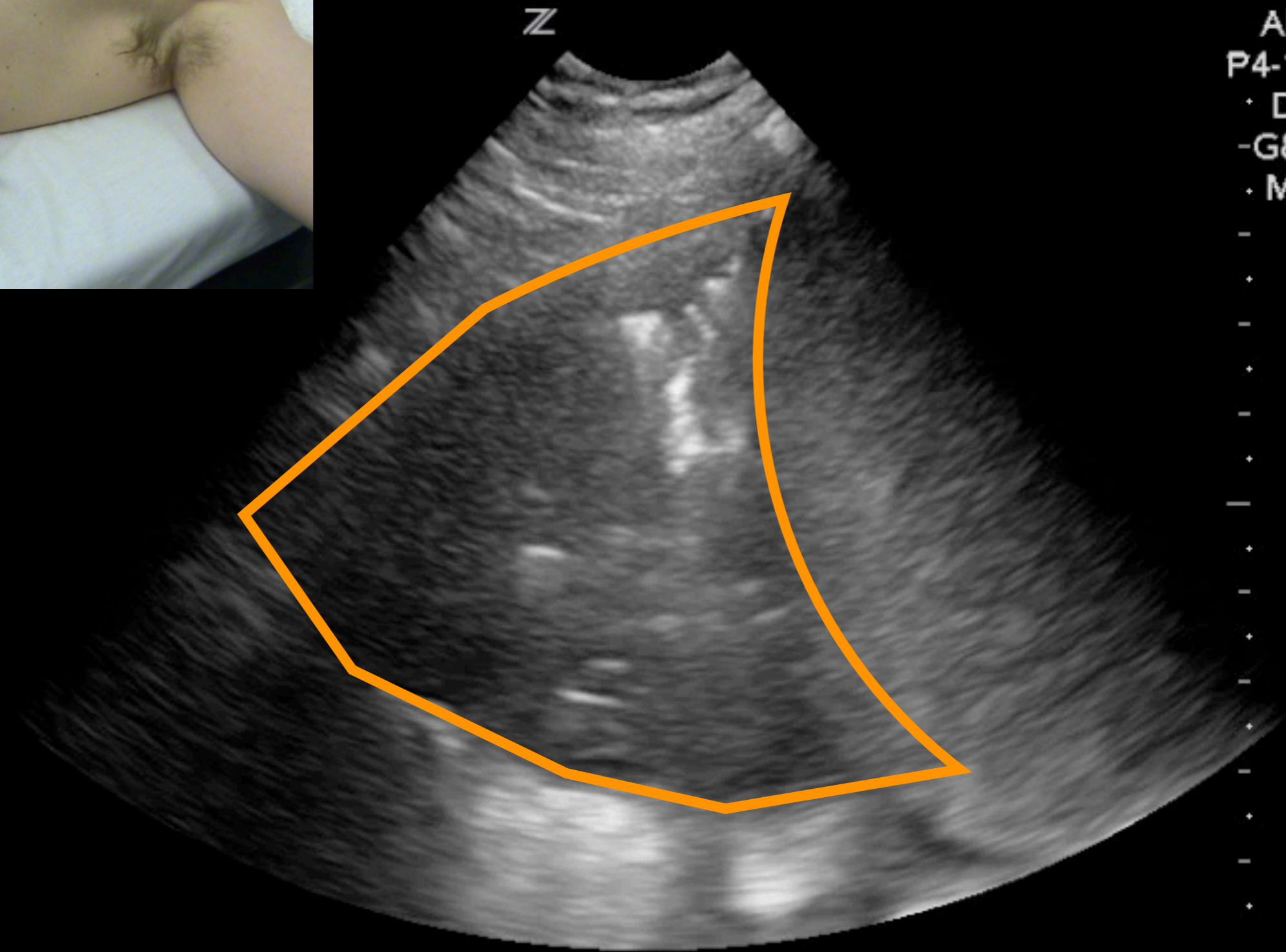
Abd/General
P4-1c/CH4MHz
· DR50/M2/P2
-G82/E1/100%
· MI1.5 TIs0.4
- 10.0 cm
· 17 Hz
△ ZSI 0
Image

Pneumonia
Consolidated lung



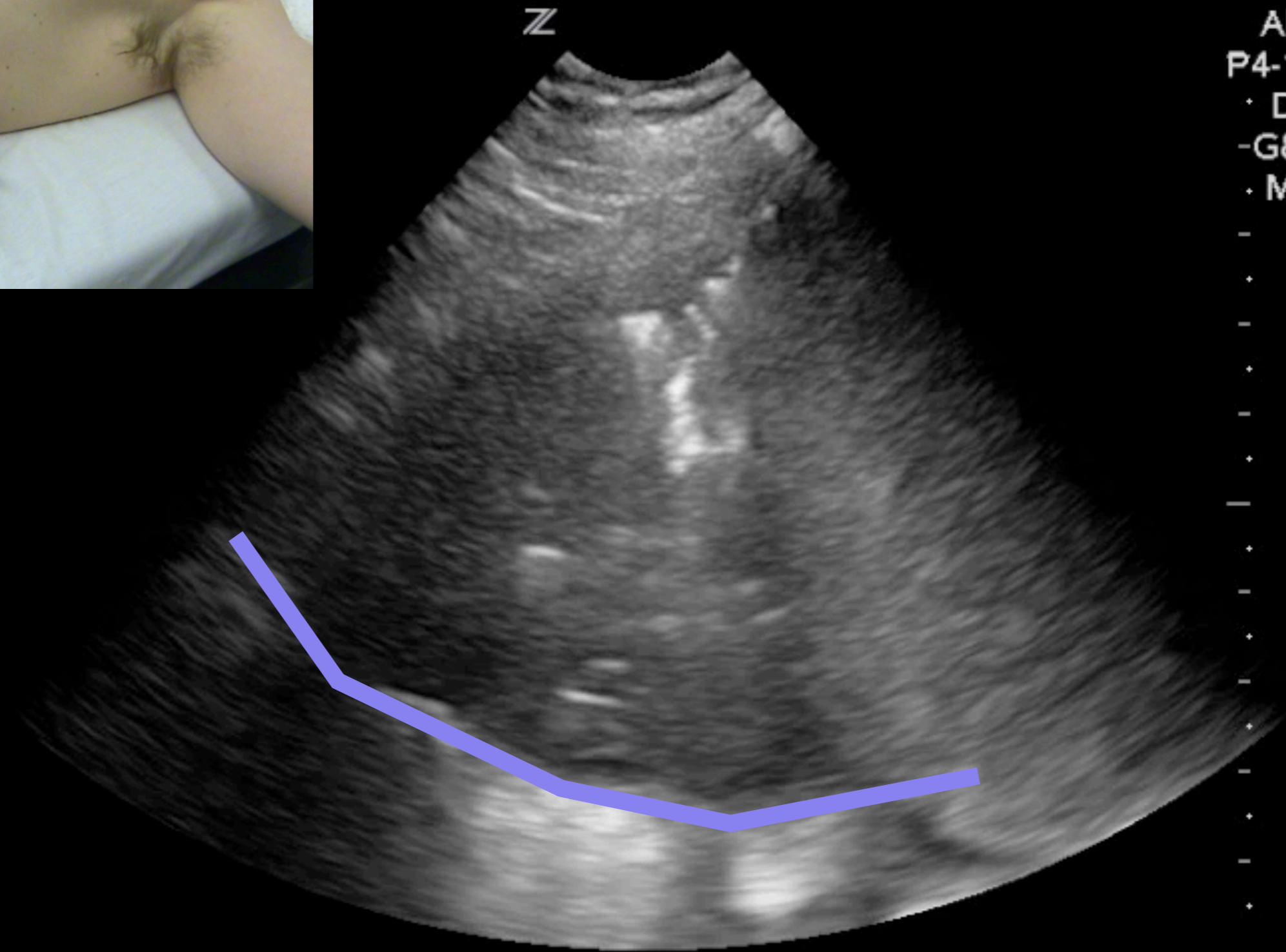
Abd/General
P4-1c/CH4MHz
· DR50/M2/P2
-G82/E1/100%
· MI1.5 TIs0.4
- 10.0 cm
· 17 Hz
△ ZSI 0
Image

Pneumonia
Hepatization



Abd/General
P4-1c/CH4MHz
· DR50/M2/P2
-G82/E1/100%
· MI1.5 TIs0.4
- 10.0 cm
· 17 Hz
△ ZSI 0
Image

Pneumonia
Air bronchograms



Abd/General
P4-1c/CH4MHz
· DR50/M2/P2
-G82/E1/100%
· MI1.5 TIs0.4
- 10.0 cm
· 17 Hz
△ ZSI 0
Image

Pneumonia
Shred sign



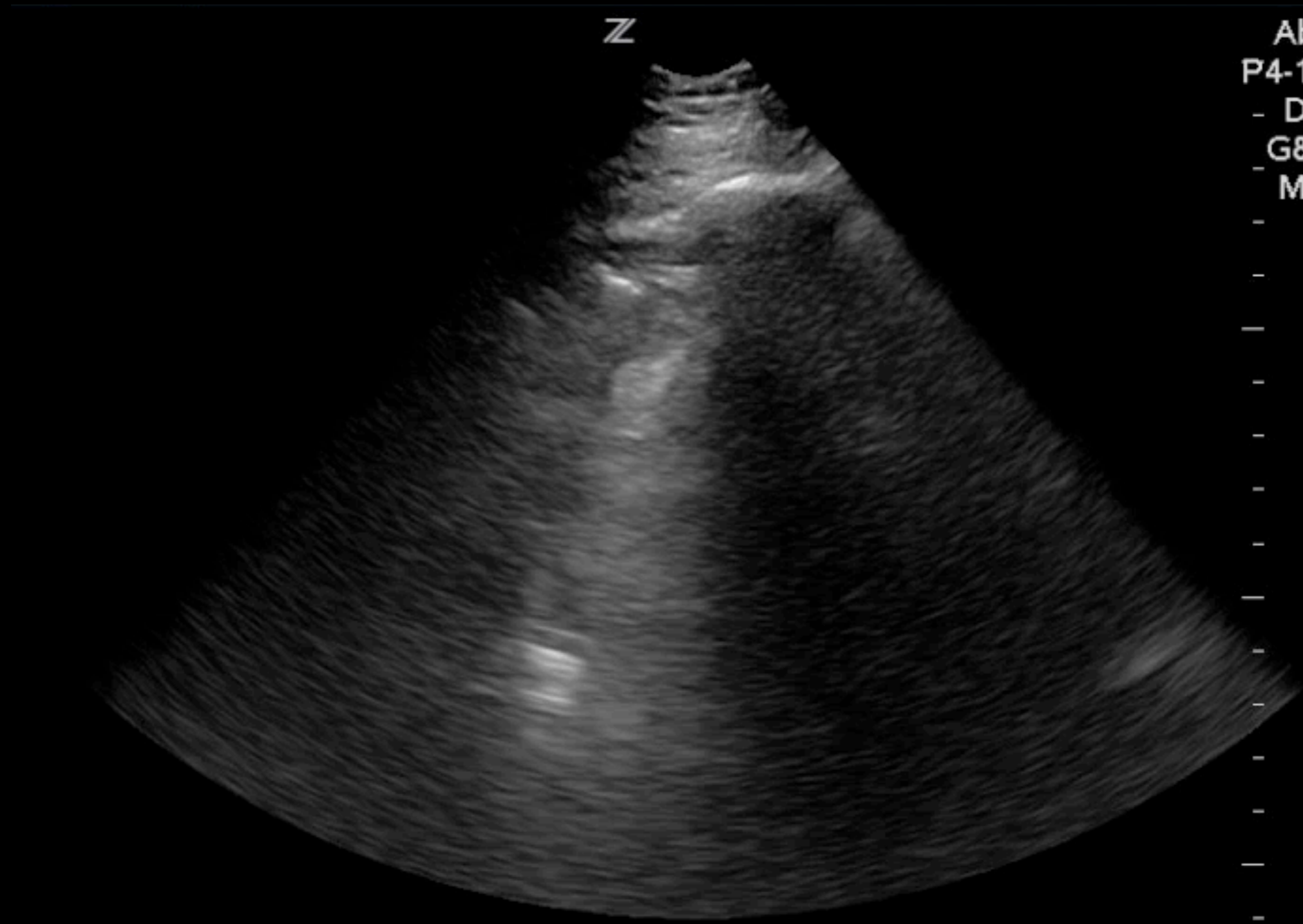
Abd/General
P4-1c/CH4MHz
· DR50/M2/P2
-G82/E1/100%
· MI1.5 TIs0.4
- 10.0 cm
· 17 Hz
△ ZSI 0
Image

Pneumonia
Shred sign



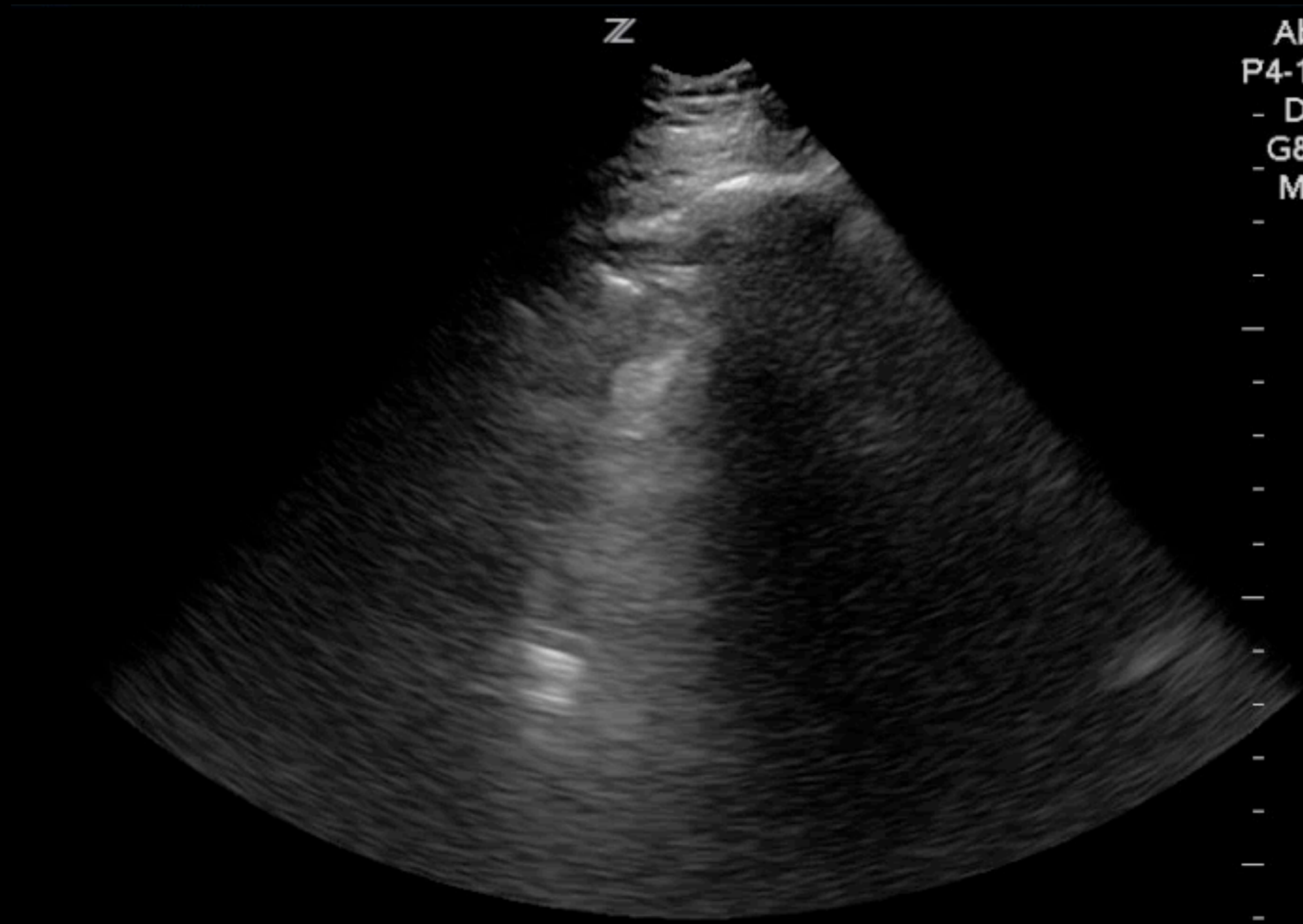
Abd/General
P4-1c/CH4MHz
· DR50/M2/P2
-G82/E1/100%
· MI1.5 TIs0.4
- 10.0 cm
· 17 Hz
△ ZSI 0
Image

Pneumonia



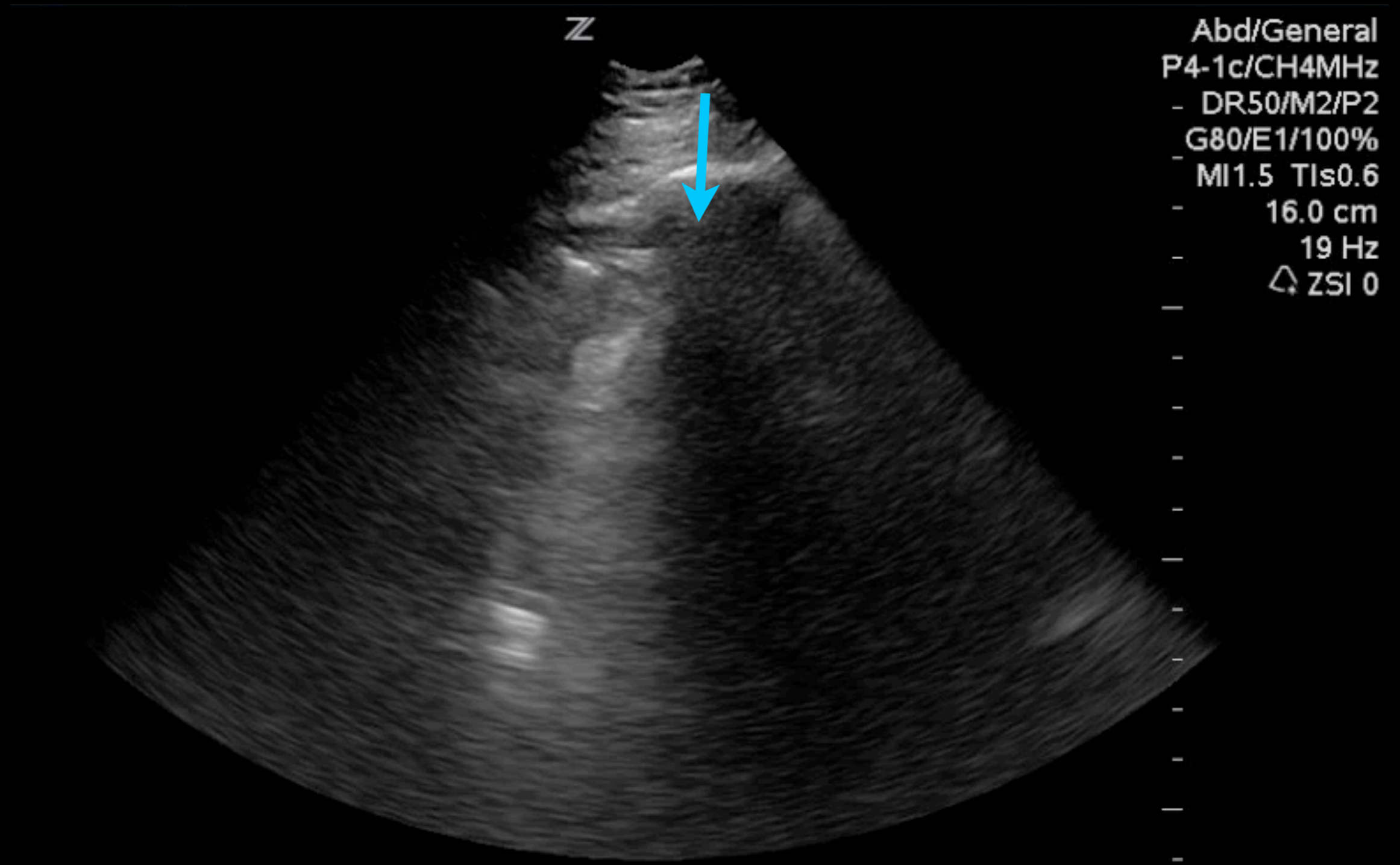
Abd/General
P4-1c/CH4MHz
- DR50/M2/P2
- G80/E1/100%
- MI1.5 TIs0.6
- 16.0 cm
- 19 Hz
△ ZSI 0

Pneumonia

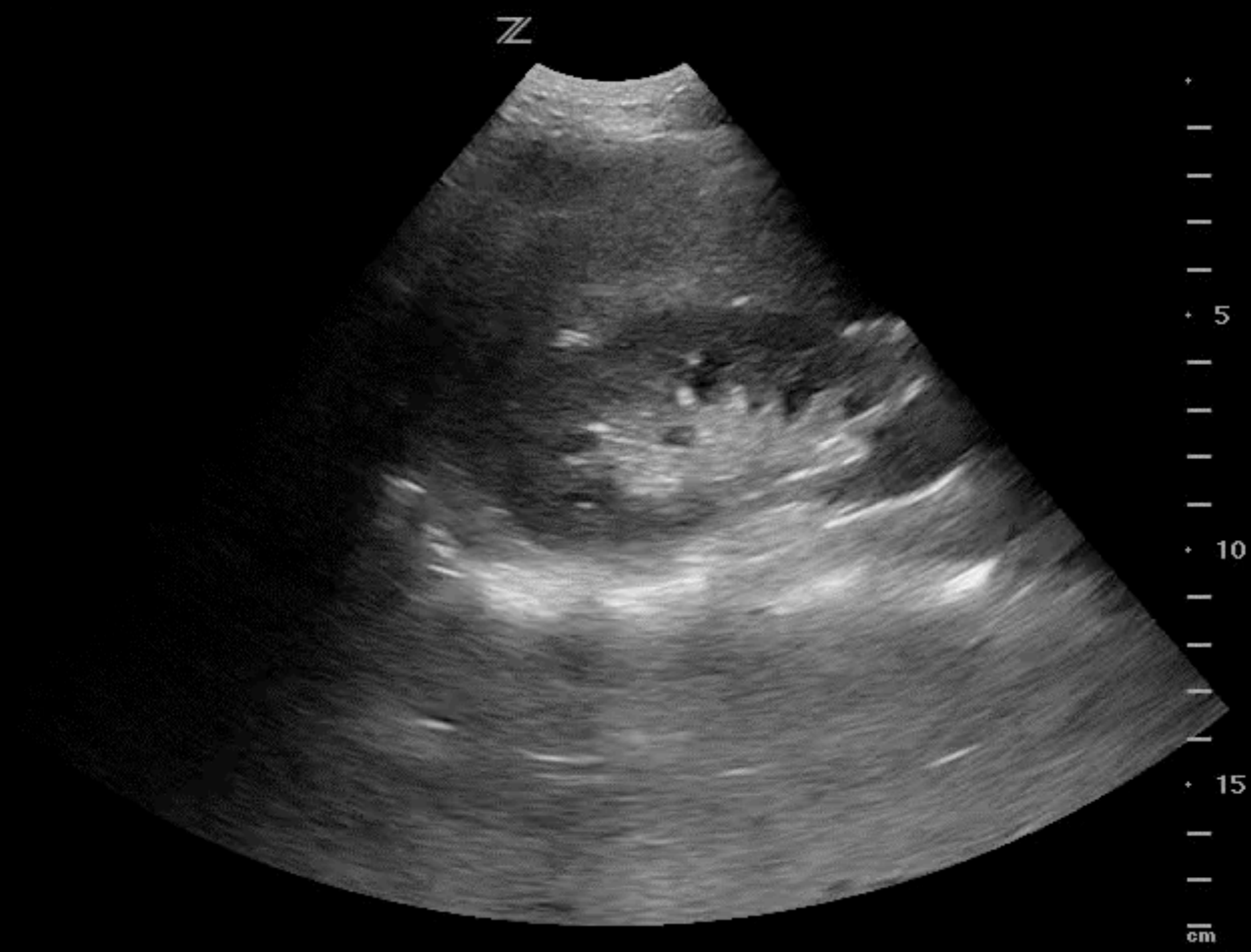

Abd/General
P4-1c/CH4MHz
- DR50/M2/P2
- G80/E1/100%
- MI1.5 TIs0.6
- 16.0 cm
- 19 Hz
△ ZSI 0

Pneumonia

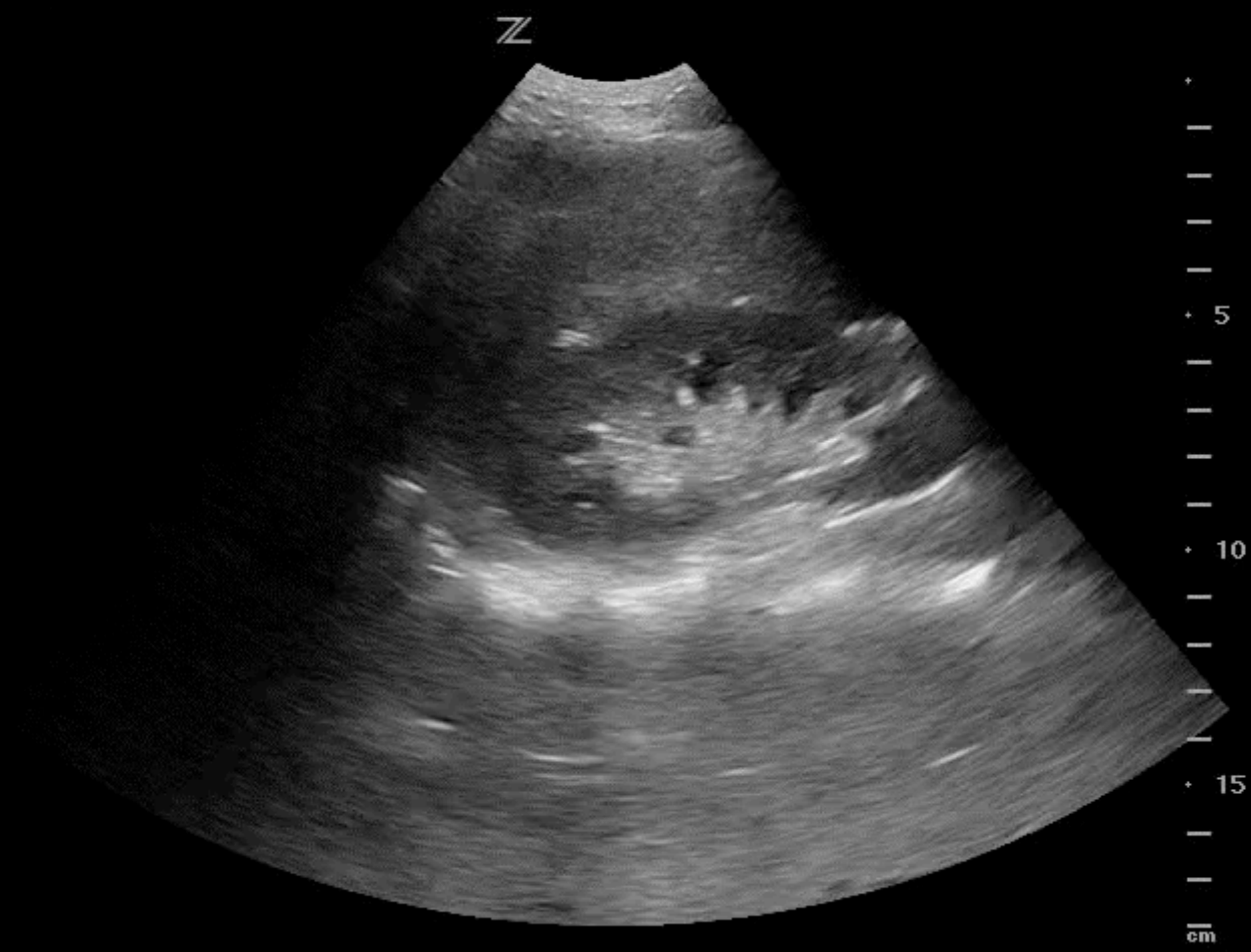


Pneumonia
Shred sign



C4-1/3.0
DR70/M3/P2
G84/E1/100%
MI0.8 TIs0.4
18.0 cm
20/20 Hz
ZSI 0
Image

Pneumonia



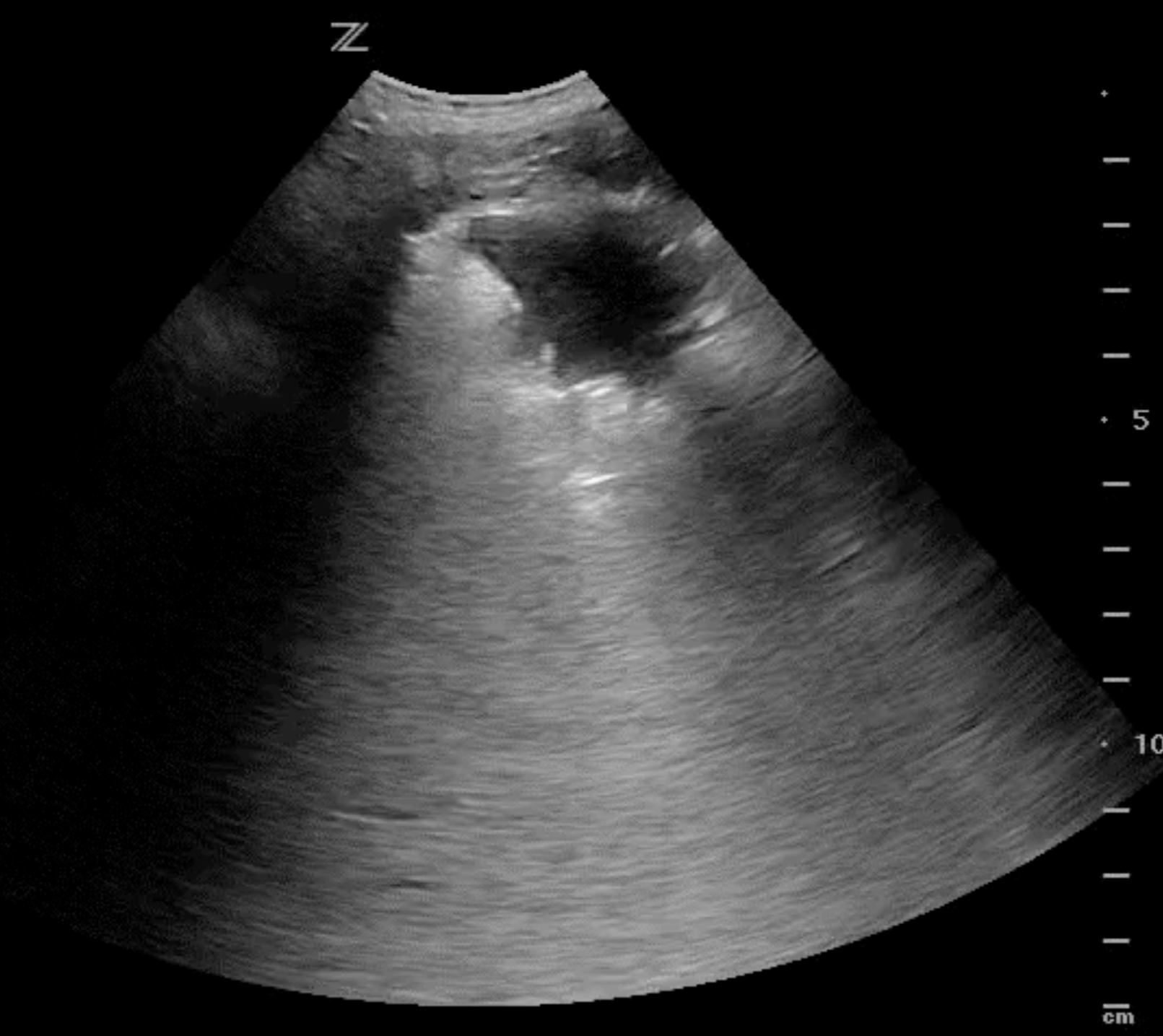C4-1/3.0
DR70/M3/P2
G84/E1/100%
MI0.8 TIs0.4
18.0 cm
20/20 Hz
ZSI 0
Image

Pneumonia



C4-1/3.0
DR70/M3/P2
G84/E1/100%
MI0.8 TIs0.4
18.0 cm
20/20 Hz
ZSI 0
Image

Pneumonia
Not mirror artifact



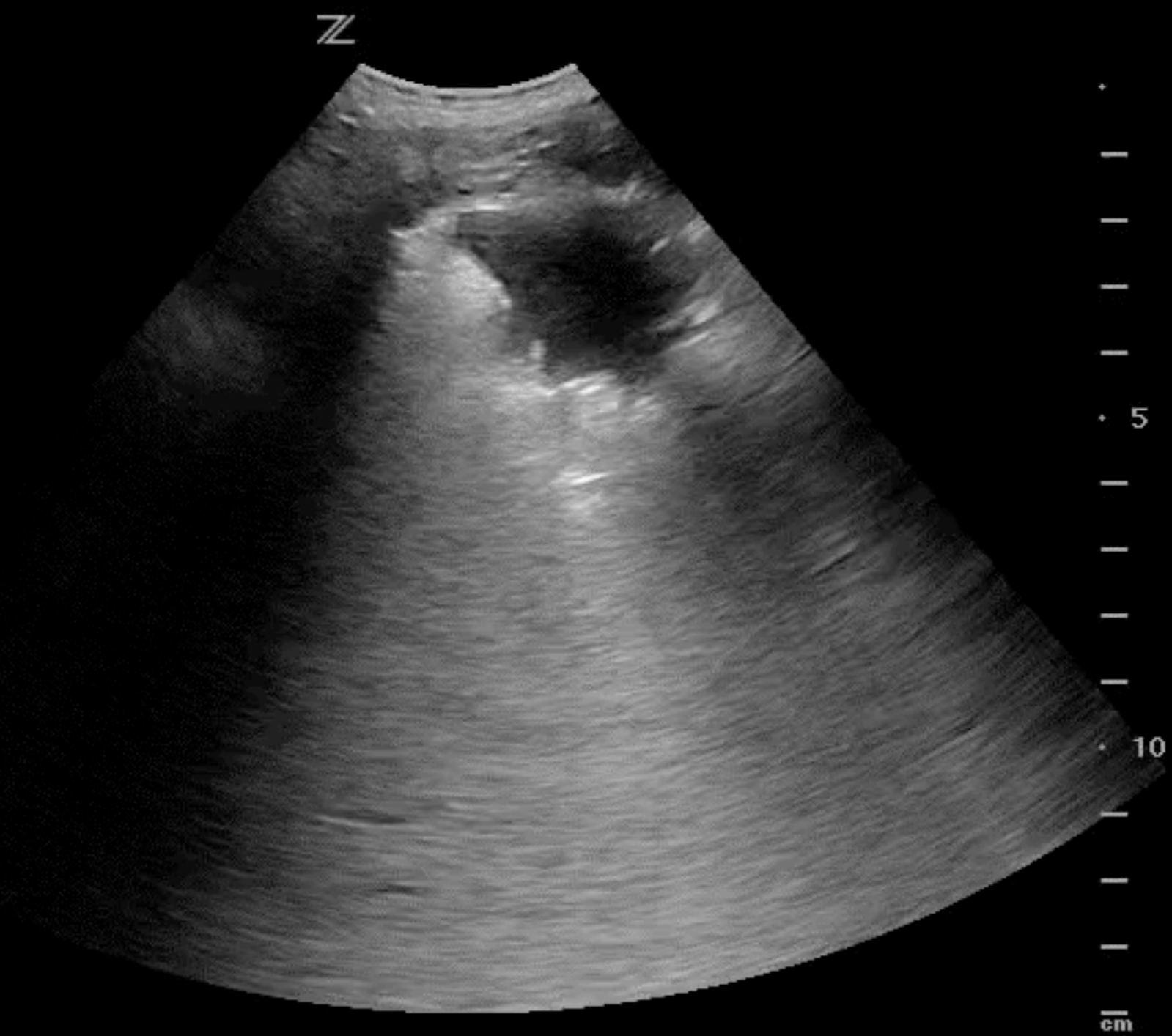C4-1/3.0
DR70/M3/P2
G76/E1/100%
MI0.7 TIs0.4
14.0 cm
22 Hz
ZSI 0
Image

Pneumonia



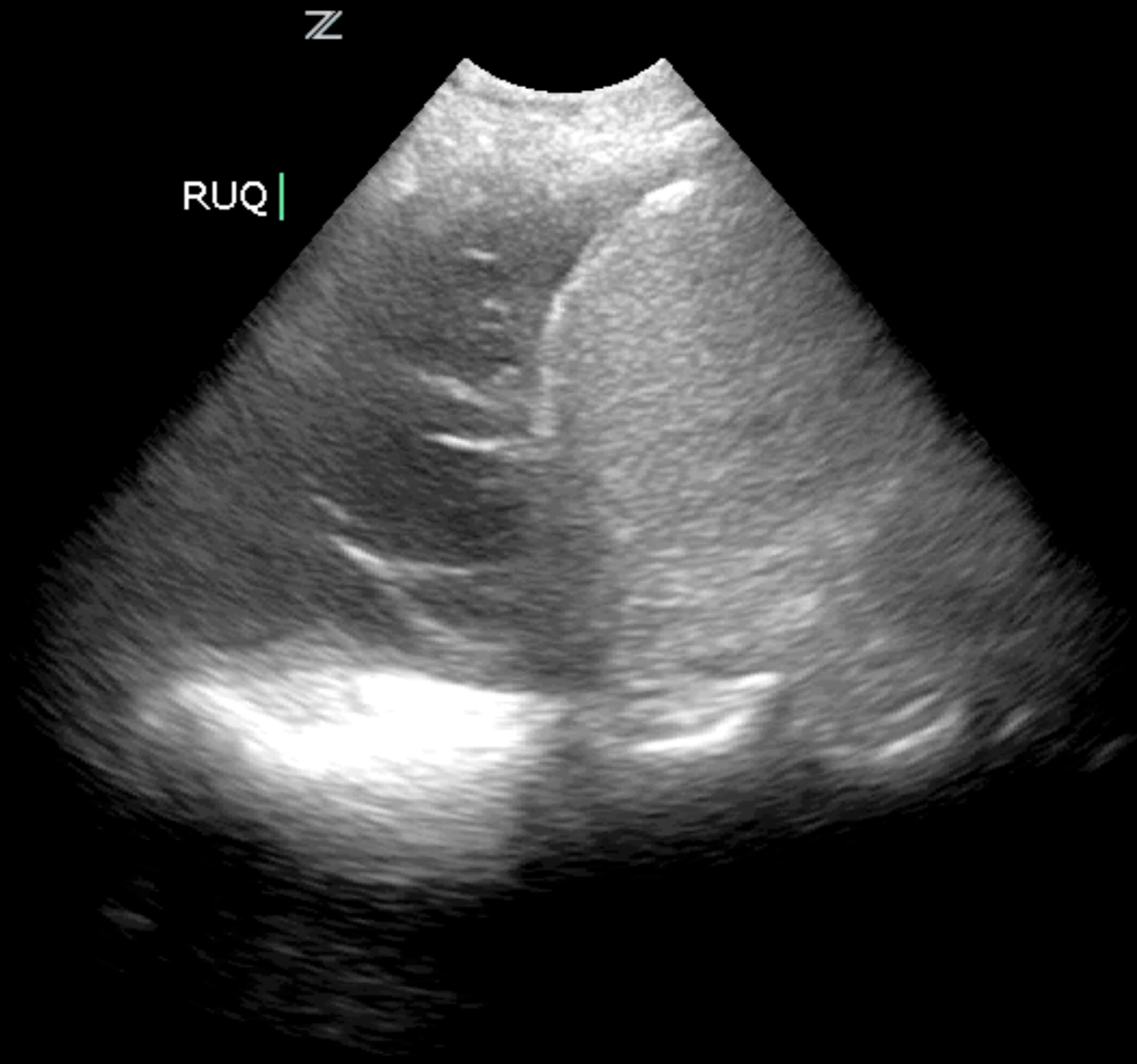C4-1/3.0
DR70/M3/P2
G76/E1/100%
MI0.7 TIs0.4
14.0 cm
22 Hz
ZSI 0
Image

Pneumonia



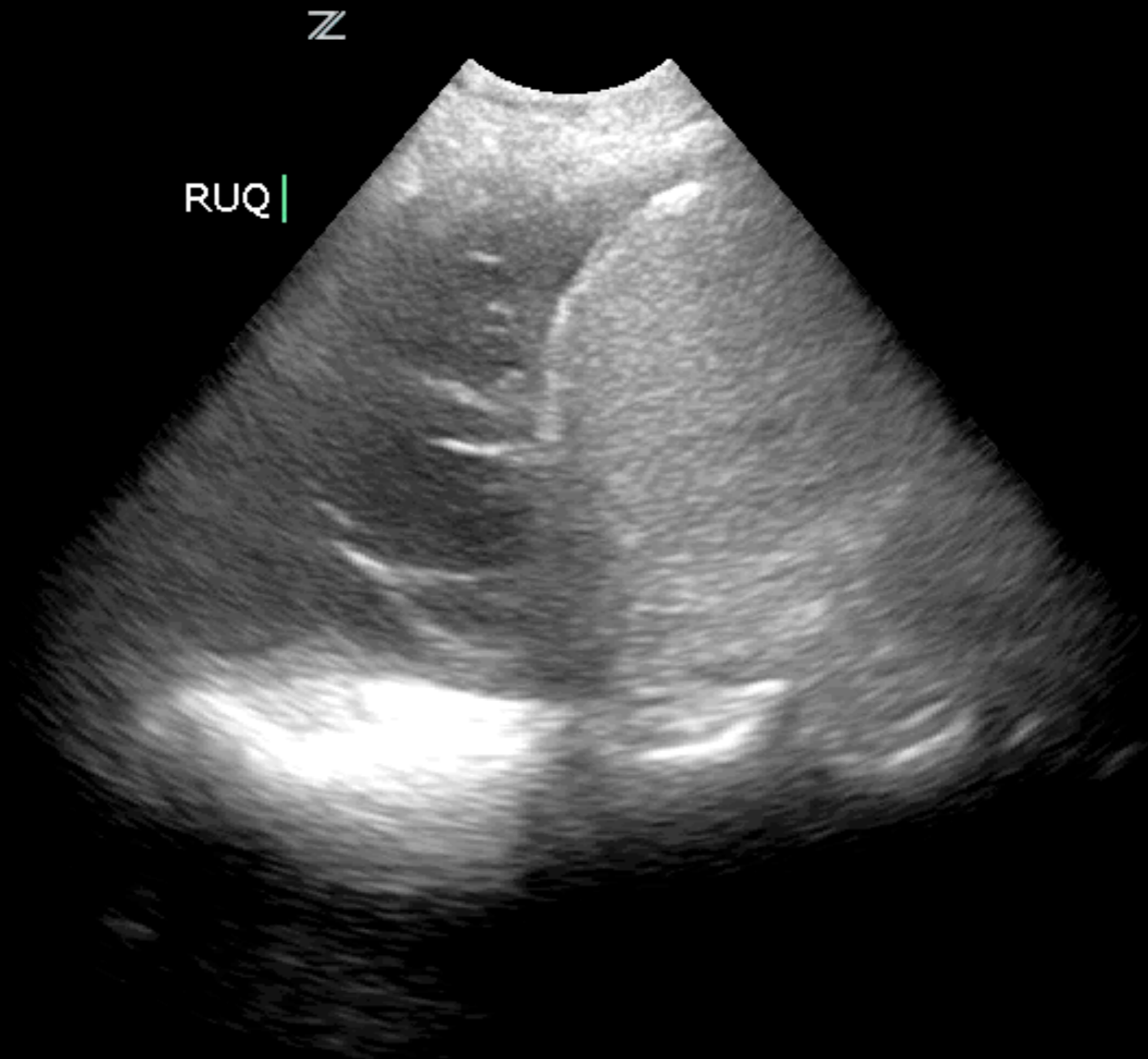
Pneumonia

Turn probe for transverse view



Abd/General
C4-1/CH4MHz
- DR60/M3/P2
G70/E1/100%
MI1.3 TIs0.4
- 16.0 cm
- 12 Hz
- ZSI 0

Consolidation

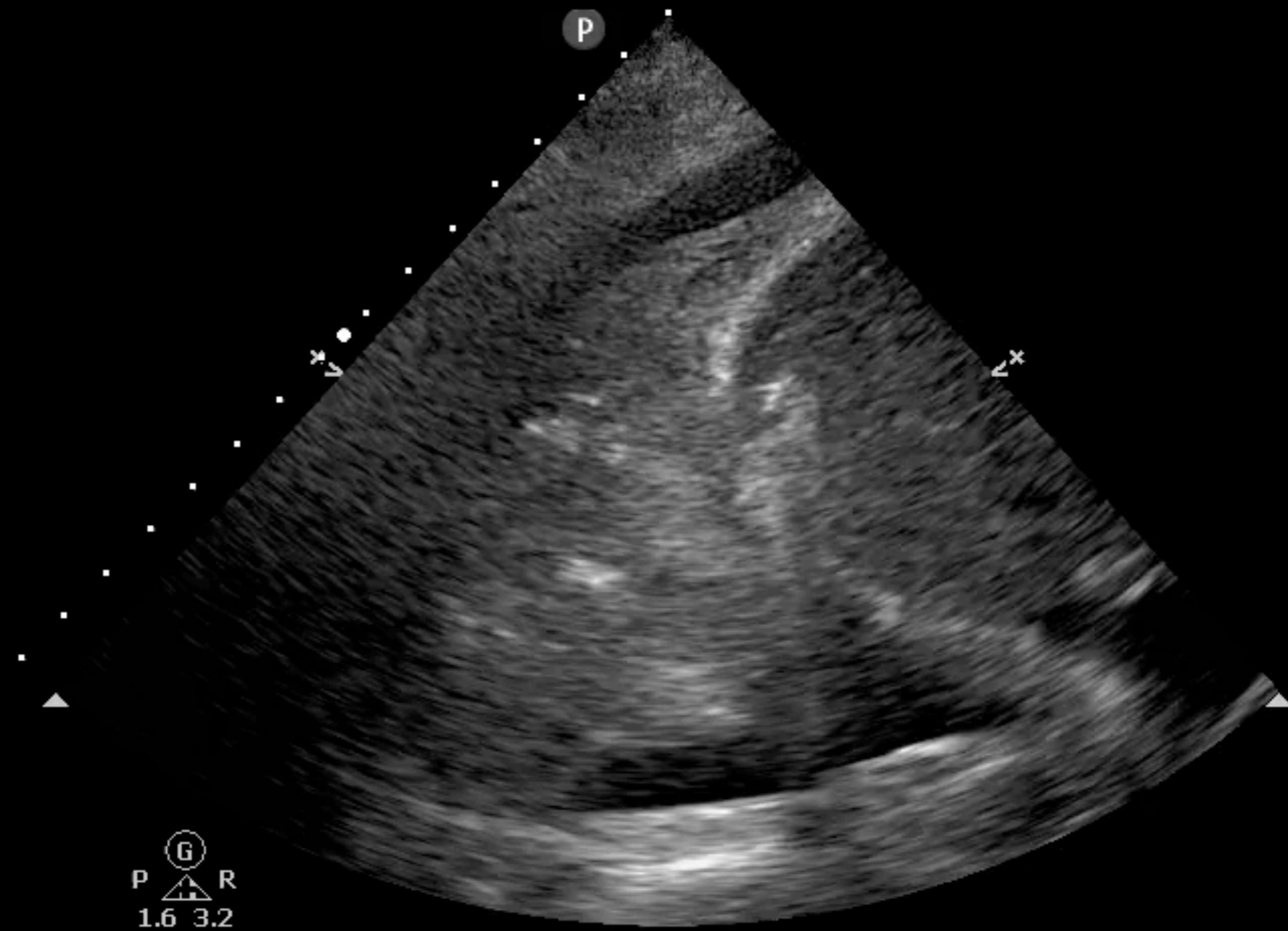


Abd/General
C4-1/CH4MHz
- DR60/M3/P2
G70/E1/100%
MI1.3 TIs0.4
- 16.0 cm
- 12 Hz
- ZSI 0

Consolidation
Not a mirror image

ED ECHO
S4-2
34Hz
15.0cm

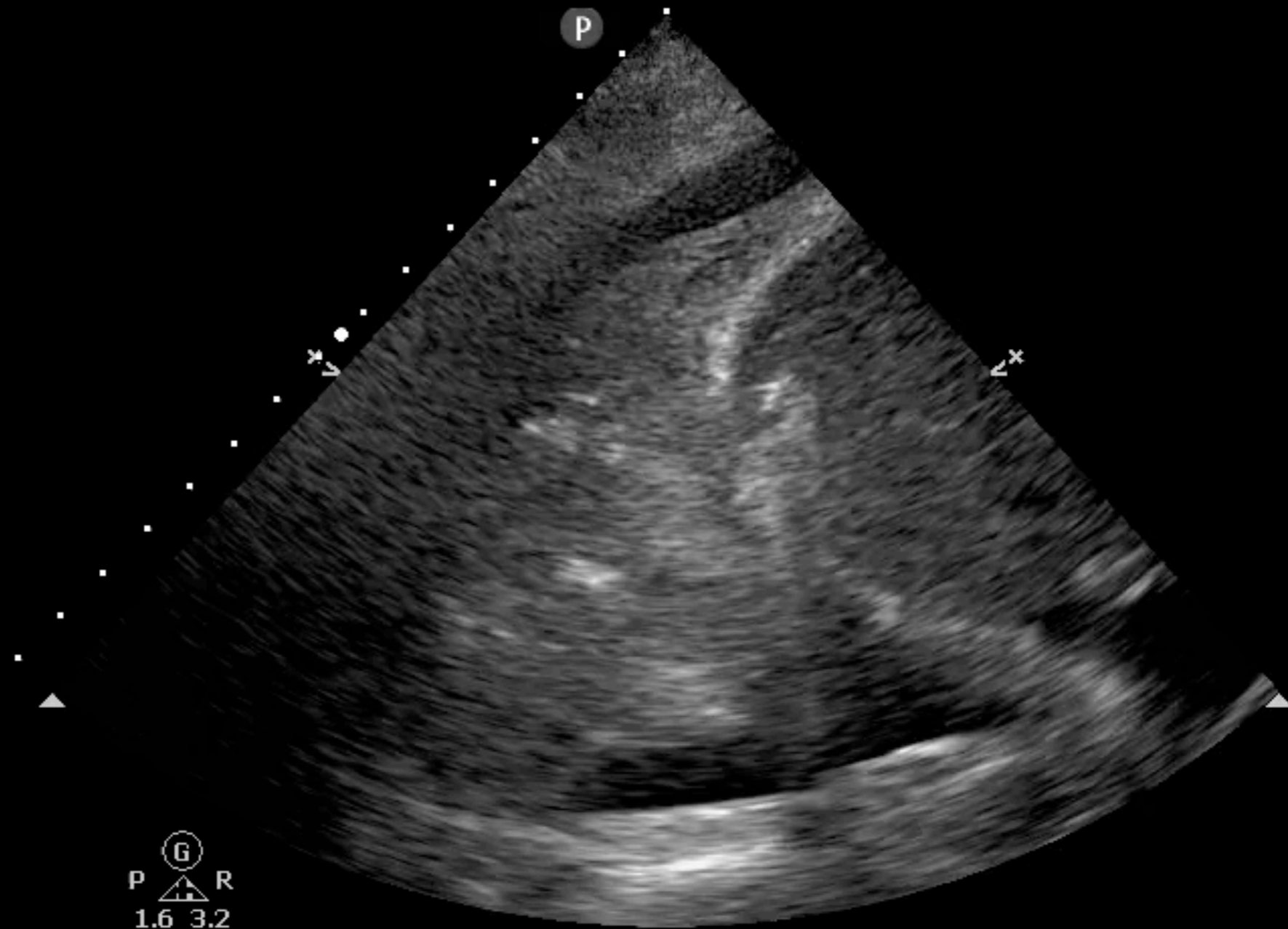
2D
HGen
Gn 50
50
5/2/0



Consolidation

ED ECHO
S4-2
34Hz
15.0cm

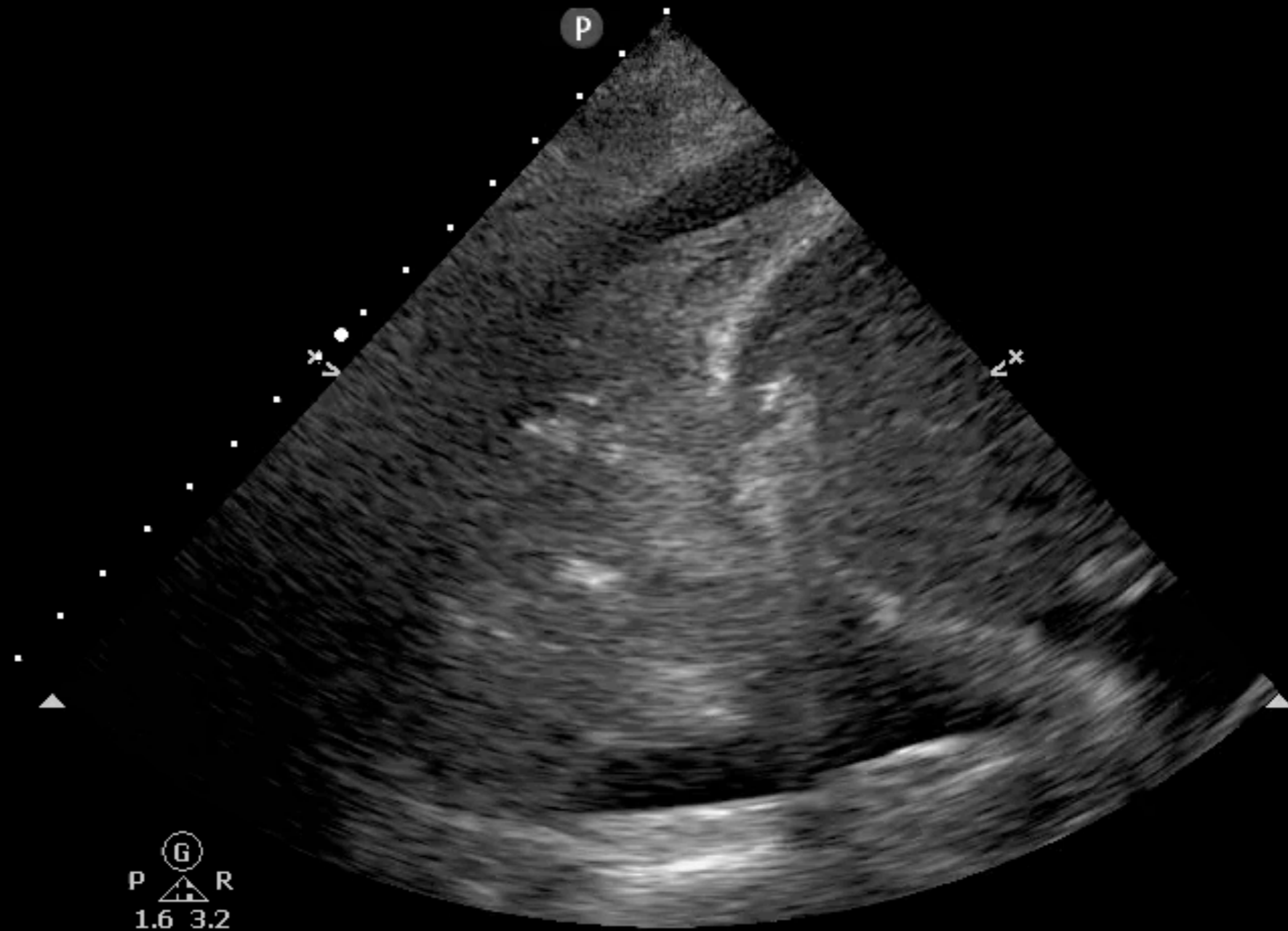
2D
HGen
Gn 50
50
5/2/0



Consolidation
Pleural effusion present

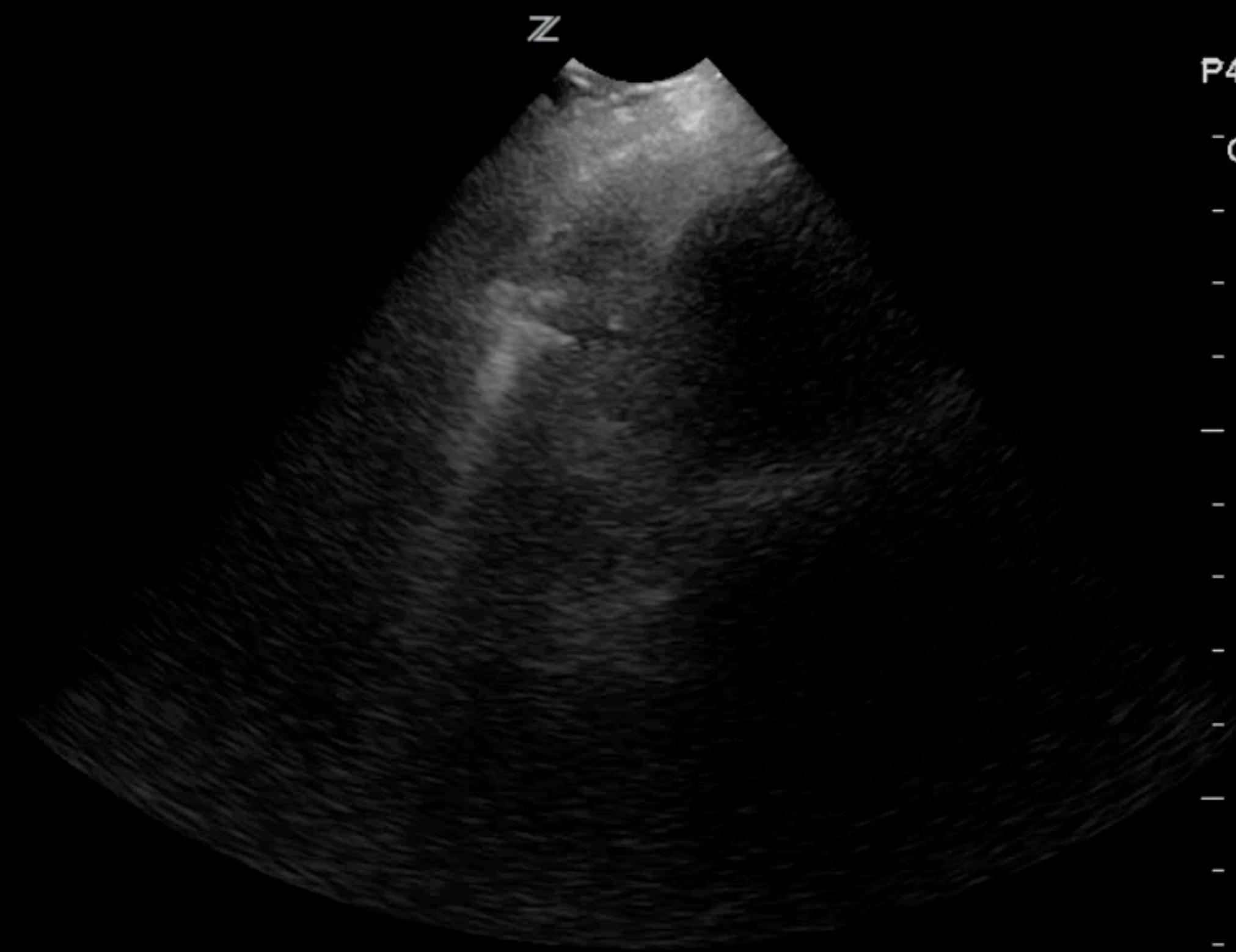
ED ECHO
S4-2
34Hz
15.0cm

2D
HGen
Gn 50
50
5/2/0



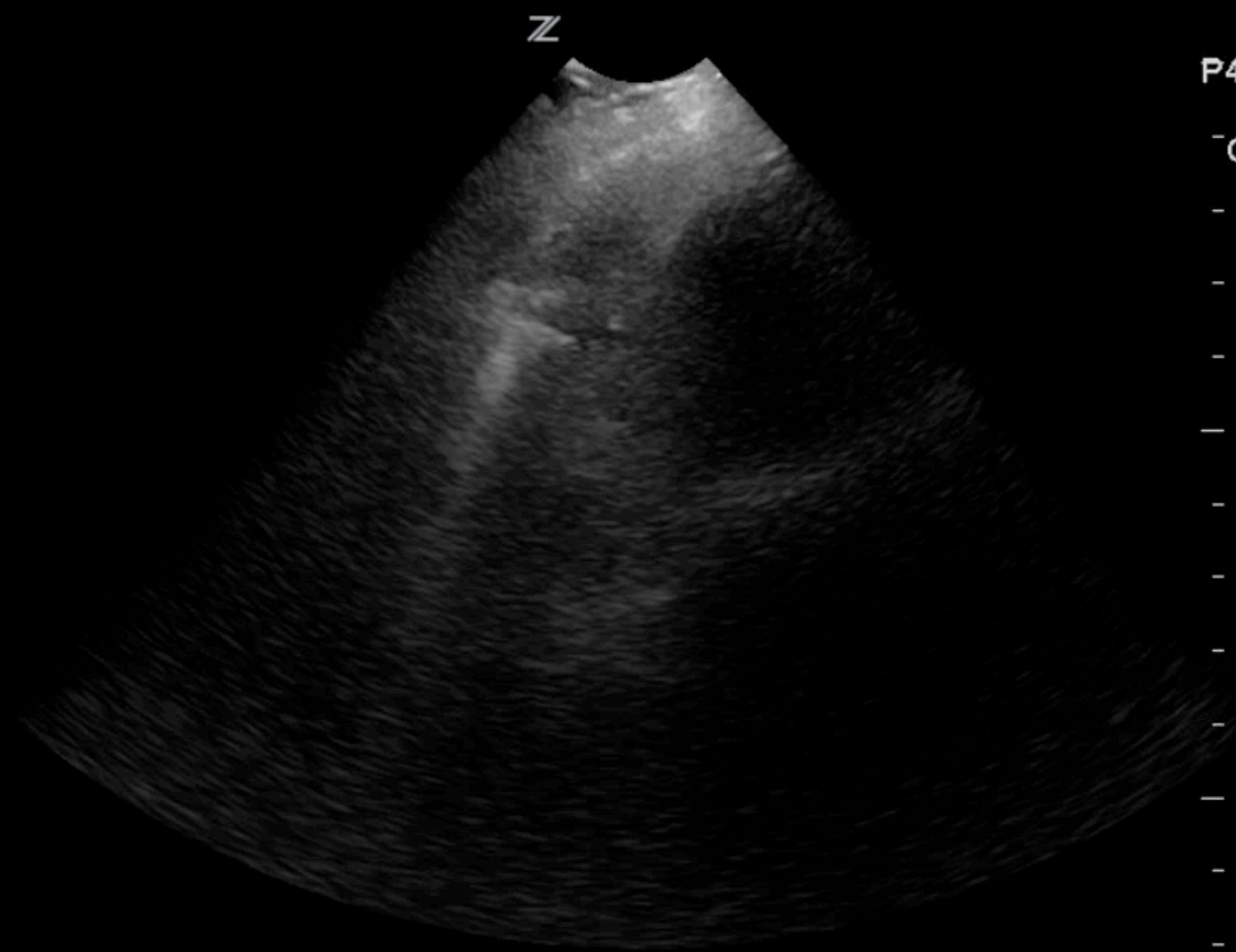
Consolidation

Air bronchograms may be due to atelectasis



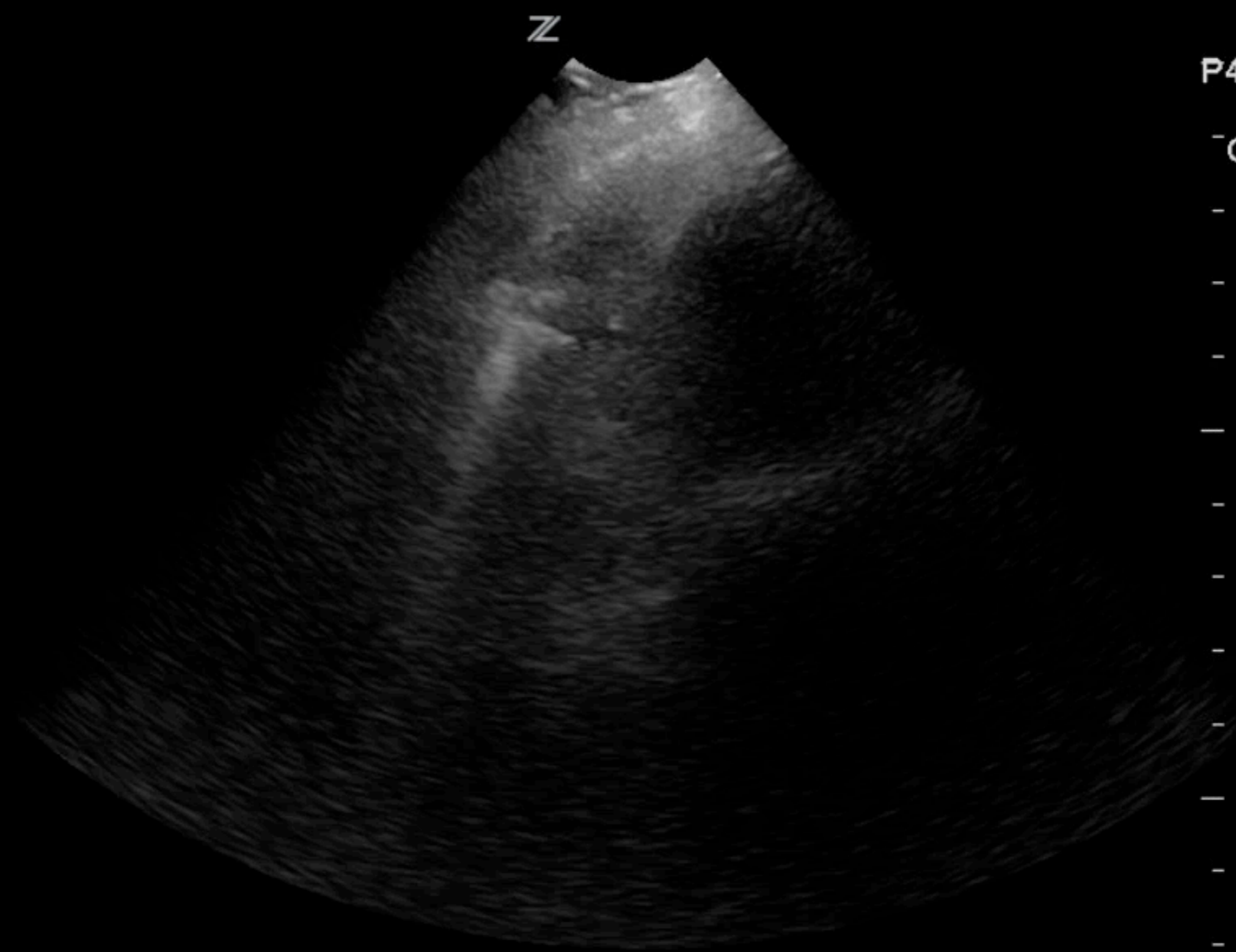
Abd/FAST
P4-1c/CH4MHz
DR50/M2/P2
G84/E1/100%
MI1.5 TIs0.4
12.0 cm
18/18 Hz
ZSI 0
Image

Consolidation



Abd/FAST
P4-1c/CH4MHz
DR50/M2/P2
G84/E1/100%
MI1.5 TIs0.4
12.0 cm
18/18 Hz
ZSI 0
Image

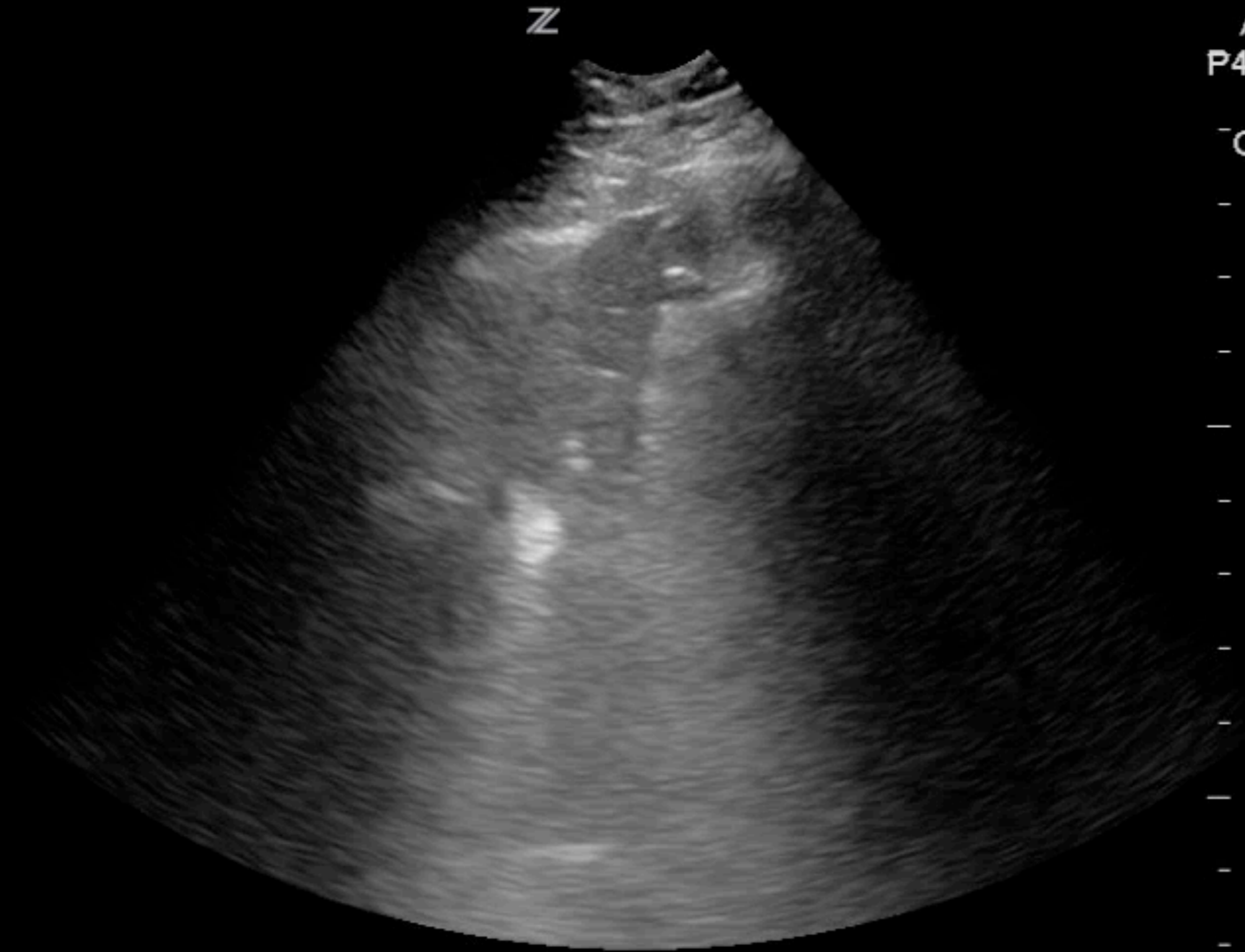Consolidation



Abd/FAST
P4-1c/CH4MHz
DR50/M2/P2
G84/E1/100%
MI1.5 TIs0.4
12.0 cm
18/18 Hz
ZSI 0
Image

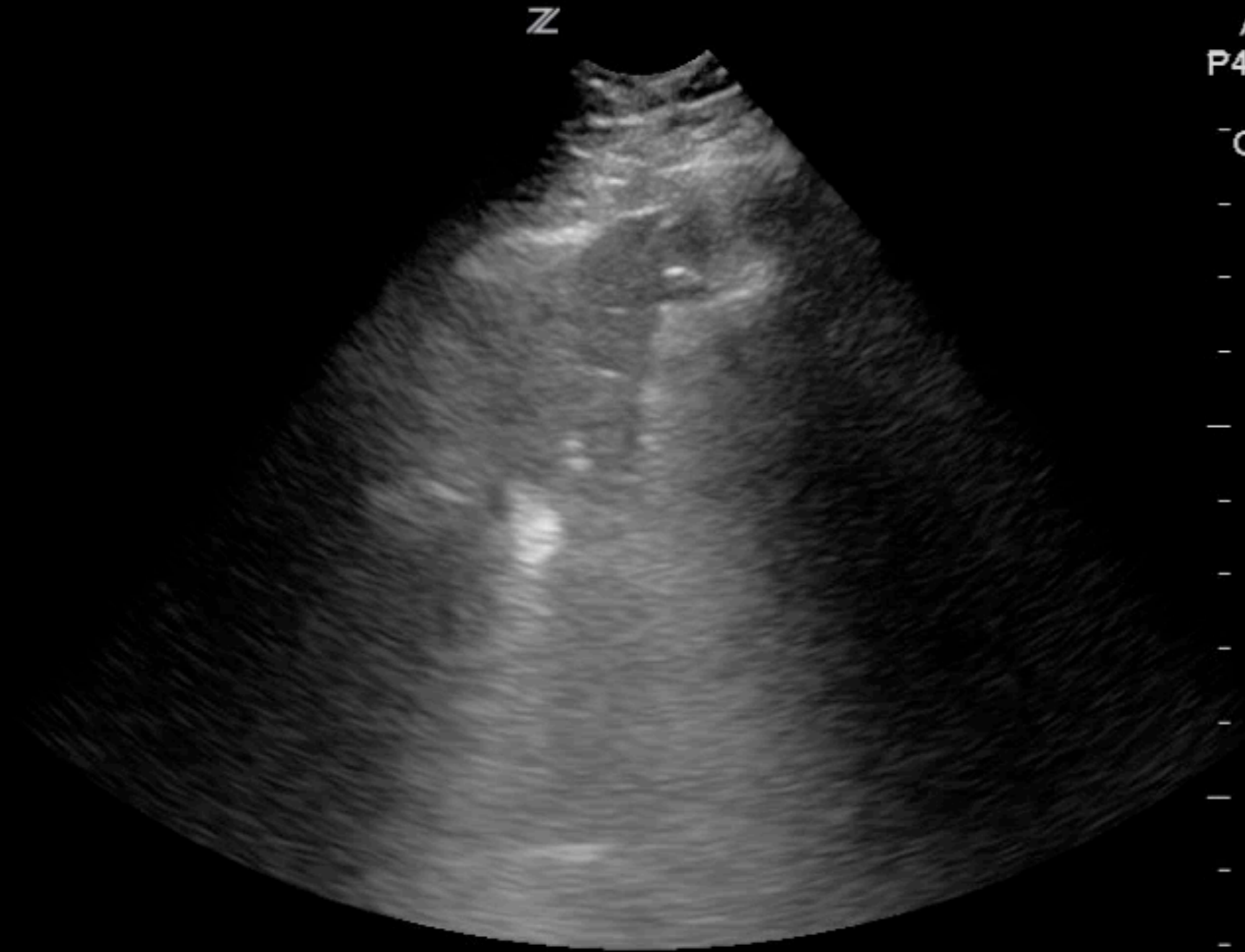
Consolidation

Air bronchograms may be due to atelectasis



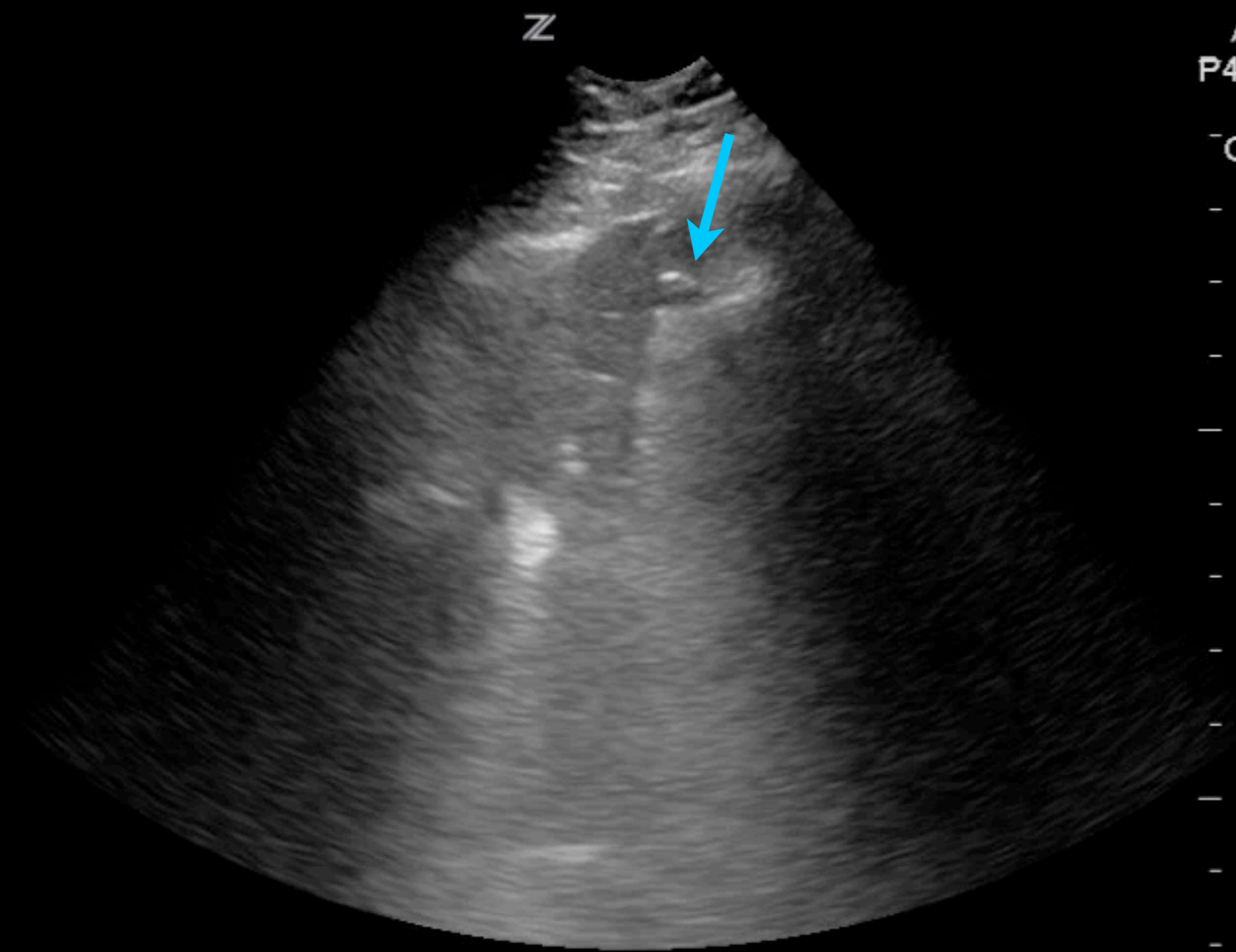
Abd/General
P4-1c/CH4MHz
DR50/M2/P2
G78/E1/100%
MI1.5 TIs0.4
12.0 cm
18 Hz
△ ZSI 0
Image

Dynamic air bronchogram



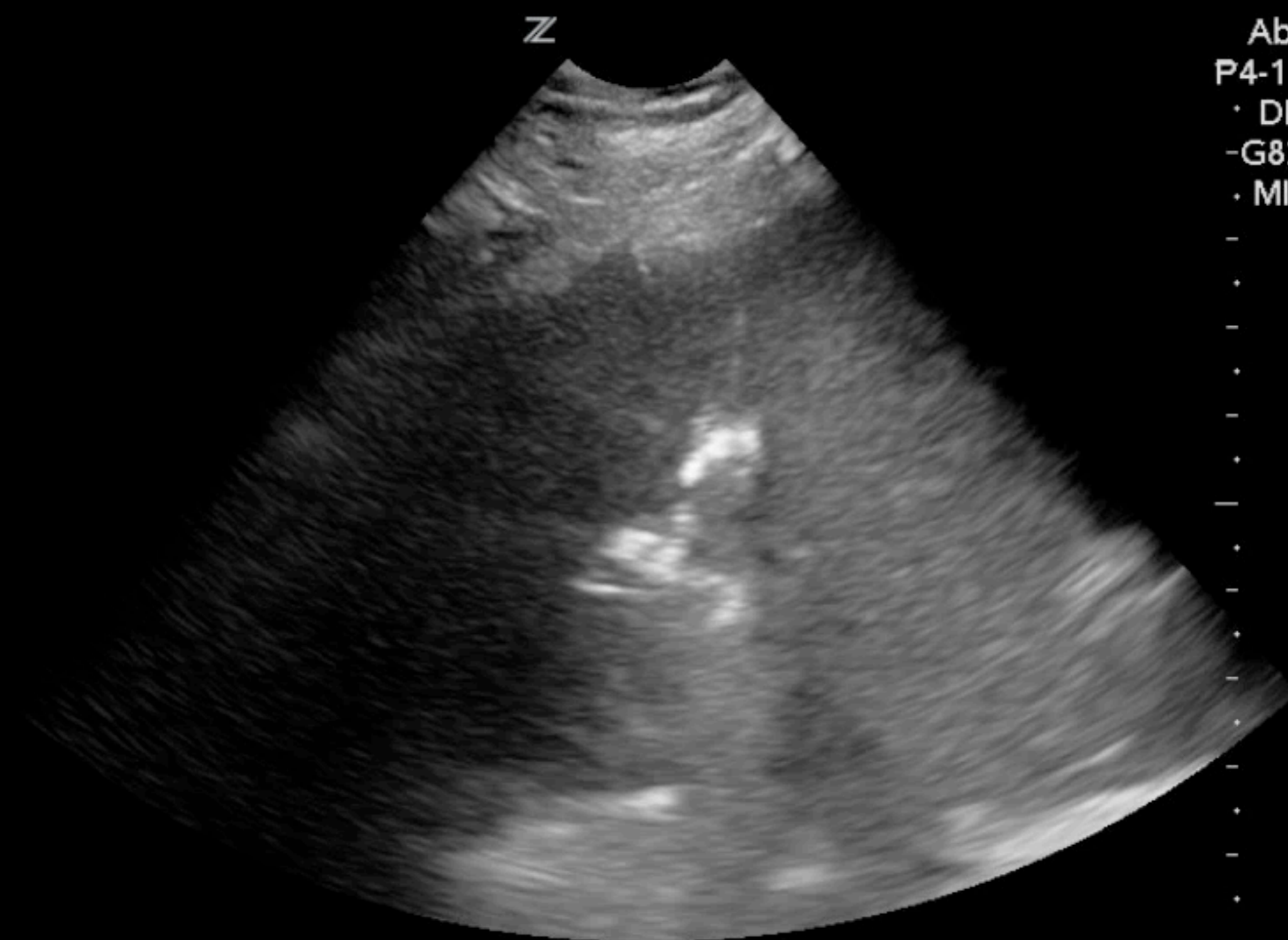Abd/General
P4-1c/CH4MHz
DR50/M2/P2
G78/E1/100%
MI1.5 TIs0.4
12.0 cm
18 Hz
△ ZSI 0
Image

Dynamic air bronchogram



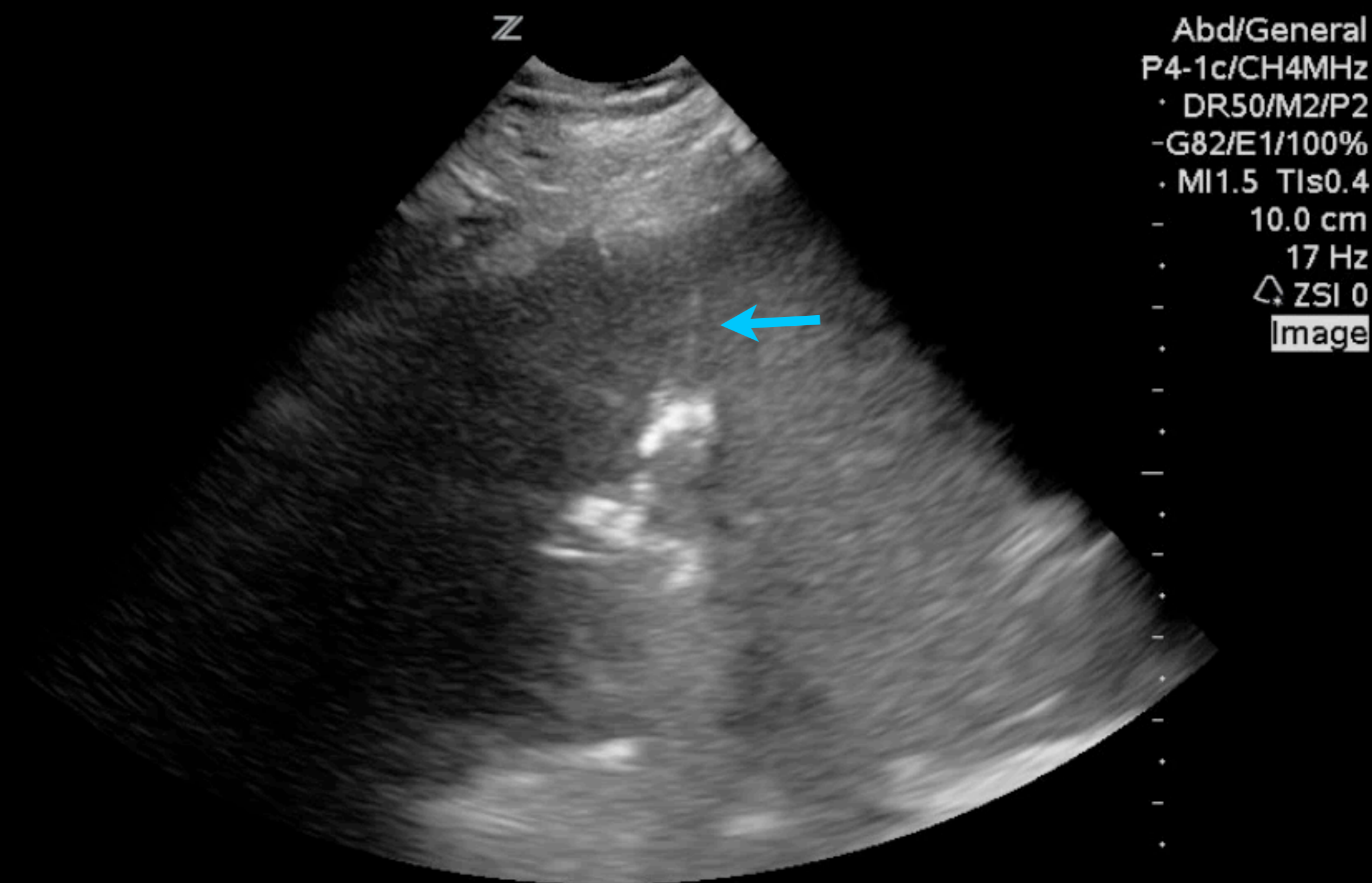
Abd/General
P4-1c/CH4MHz
DR50/M2/P2
G78/E1/100%
MI1.5 TIs0.4
12.0 cm
18 Hz
ZSI 0
Image

Dynamic air bronchogram
Specific for pneumonia



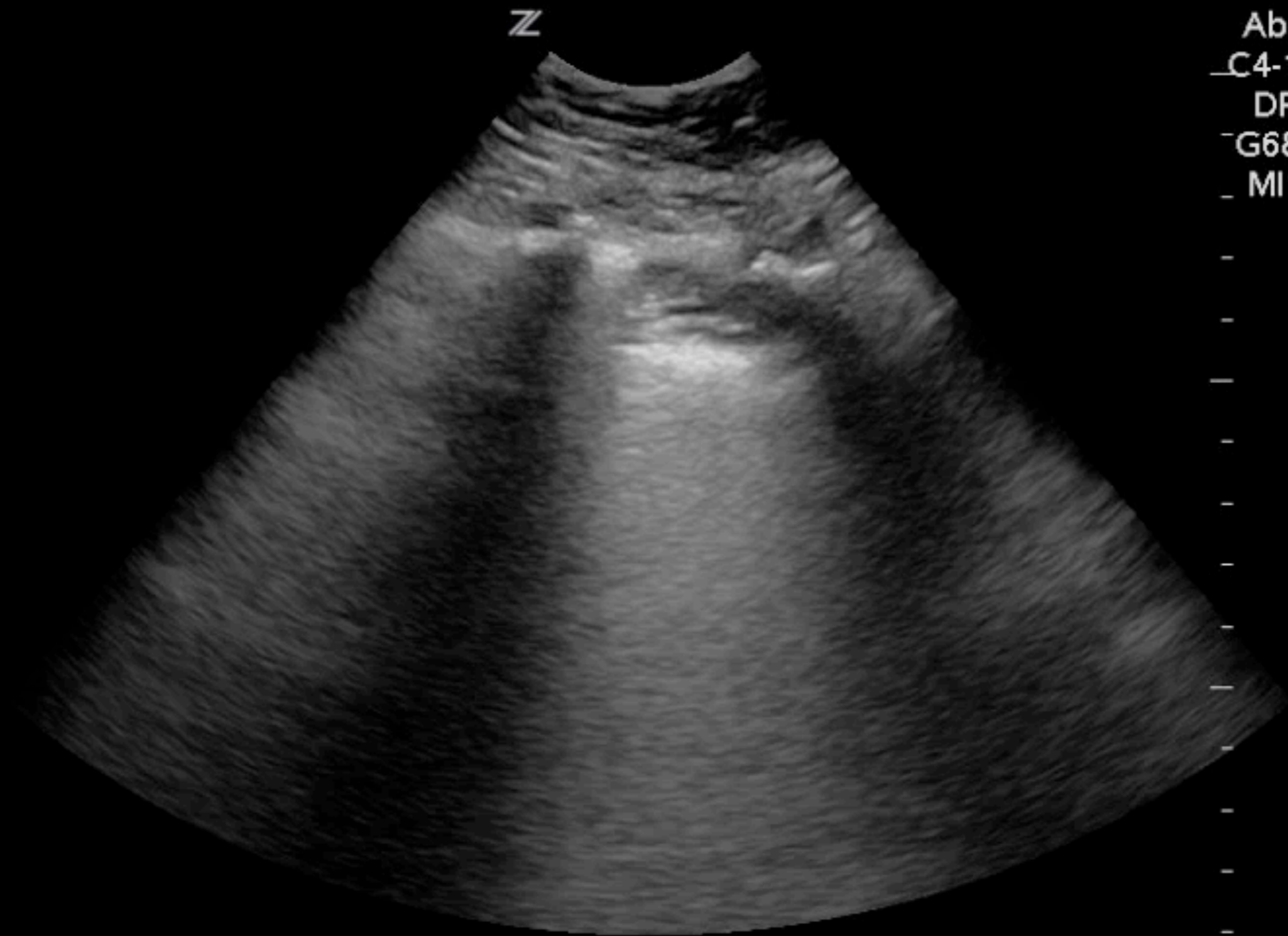Abd/General
P4-1c/CH4MHz
· DR50/M2/P2
-G82/E1/100%
· MI1.5 TIs0.4
- 10.0 cm
· 17 Hz
△ ZSI 0
Image

Dynamic air bronchogram



Abd/General
P4-1c/CH4MHz
· DR50/M2/P2
-G82/E1/100%
· MI1.5 TIs0.4
- 10.0 cm
· 17 Hz
△ ZSI 0
Image

Dynamic air bronchogram



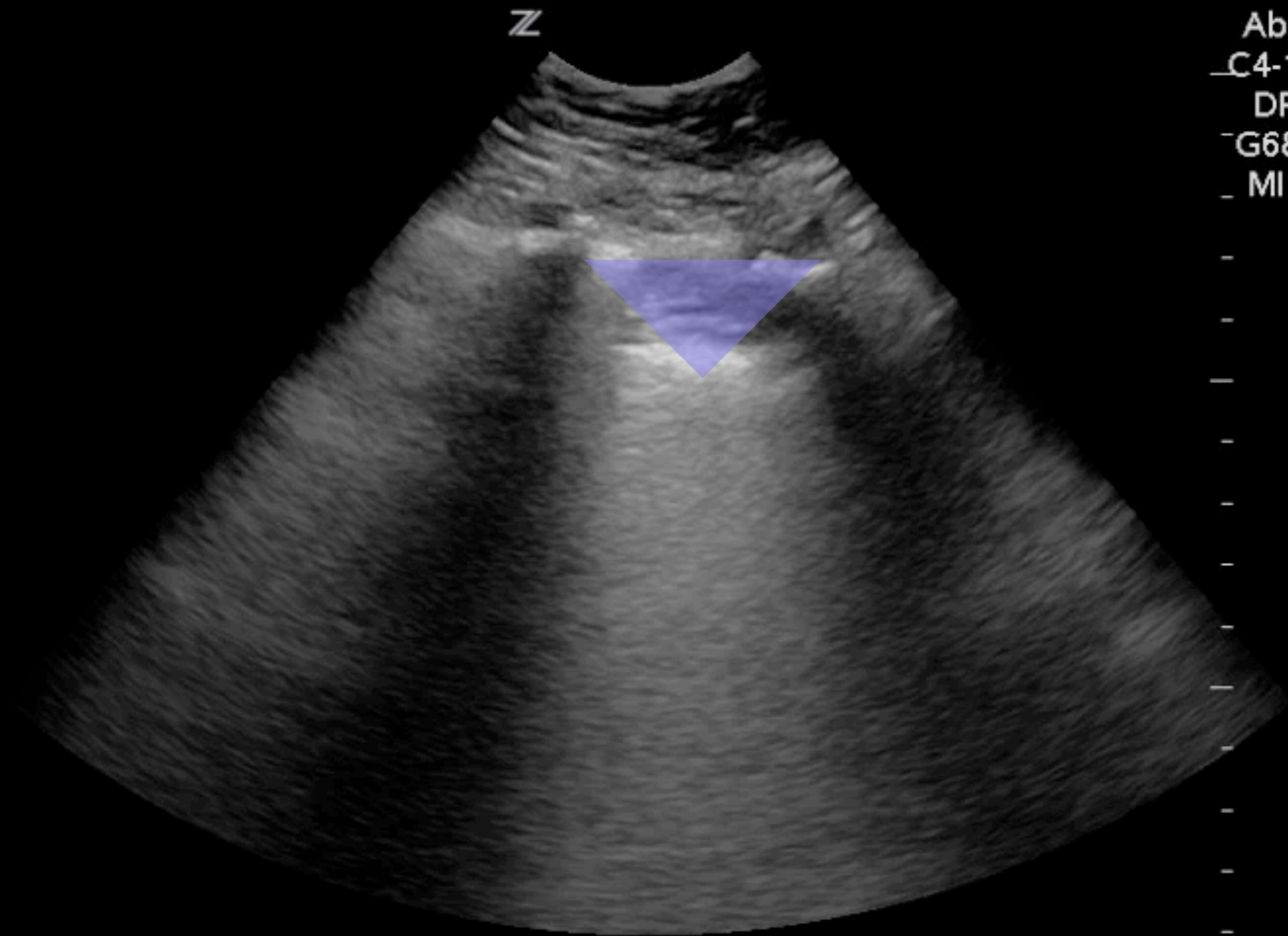Abd/General
_C4-1/CH4MHz
DR60/M3/P2
~G68/E1/100%
_ MI1.2 TIs0.4
14.0 cm
- 12 Hz
△ ZSI 0
Image

Subpleural consolidation



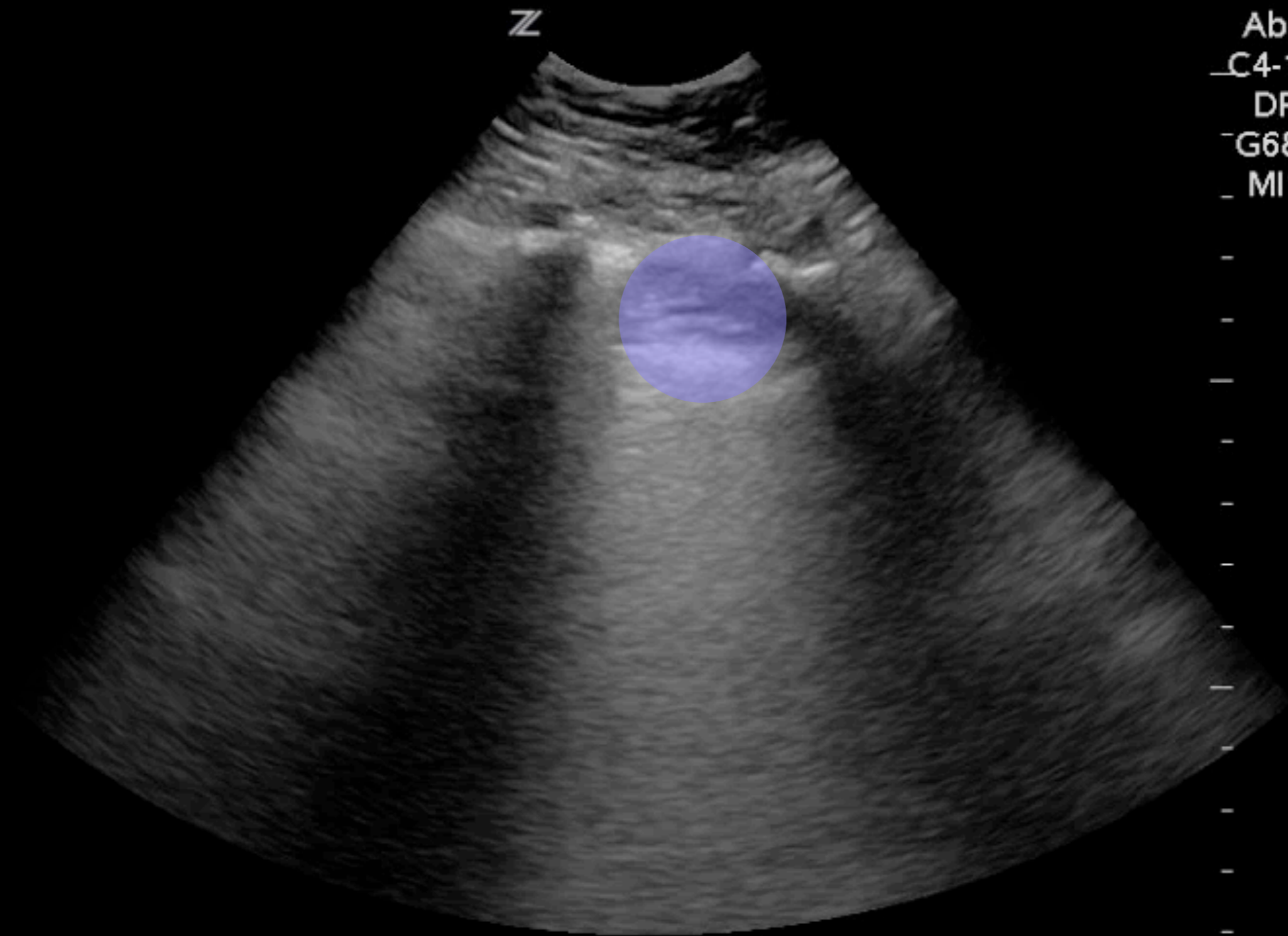
Abd/General
_C4-1/CH4MHz
DR60/M3/P2
^G68/E1/100%
_MI1.2 TIs0.4
14.0 cm
- 12 Hz
△ ZSI 0
Image

Subpleural consolidation
May represent pulmonary embolism



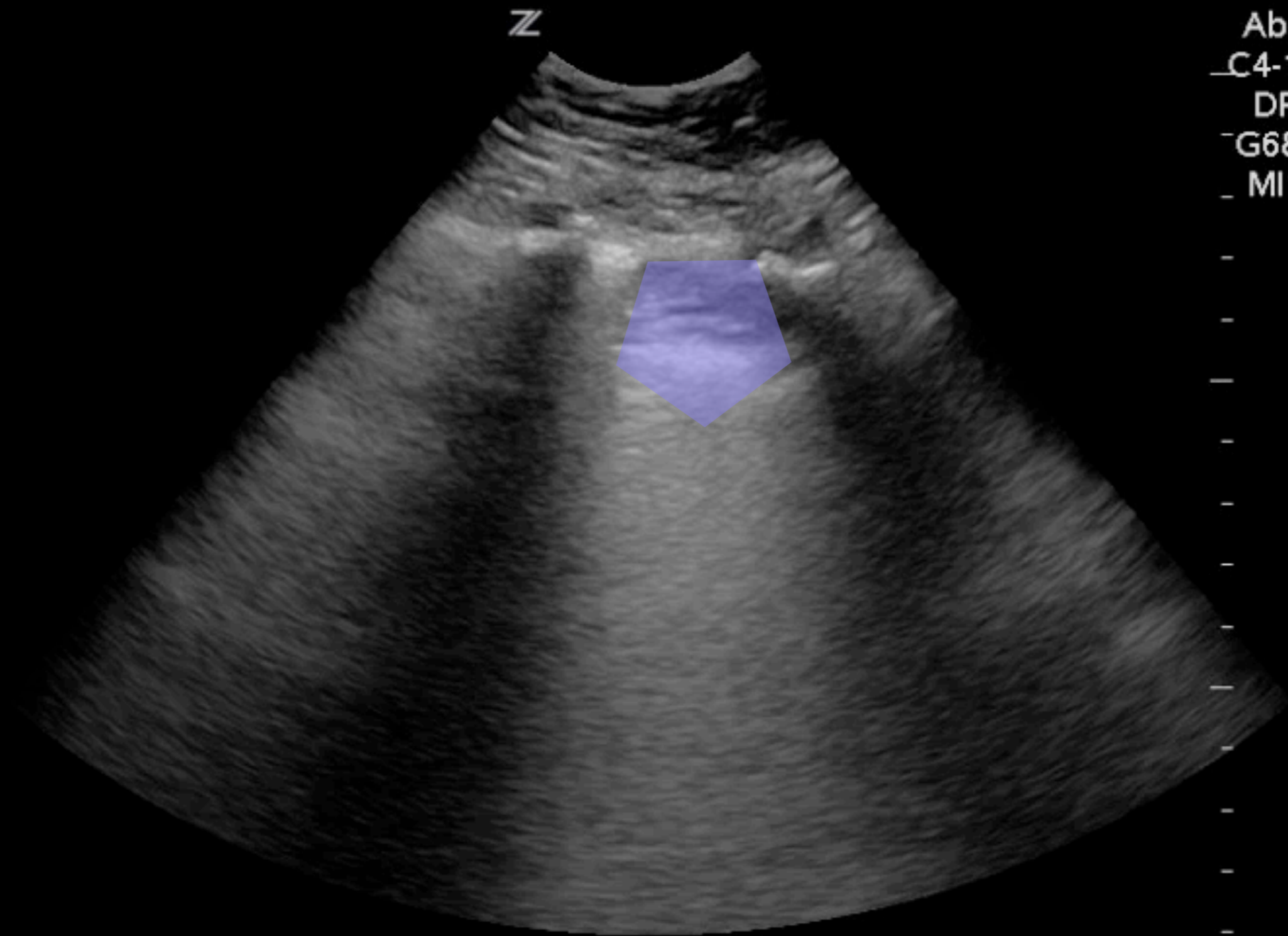
Abd/General
_C4-1/CH4MHz
DR60/M3/P2
~G68/E1/100%
_ MI1.2 TIs0.4
14.0 cm
- 12 Hz
△ ZSI 0
Image

Subpleural consolidation
May represent pulmonary embolism



Abd/General
_C4-1/CH4MHz
DR60/M3/P2
~G68/E1/100%
_ MI1.2 TIs0.4
14.0 cm
- 12 Hz
△ ZSI 0
Image

Subpleural consolidation
May represent pulmonary embolism



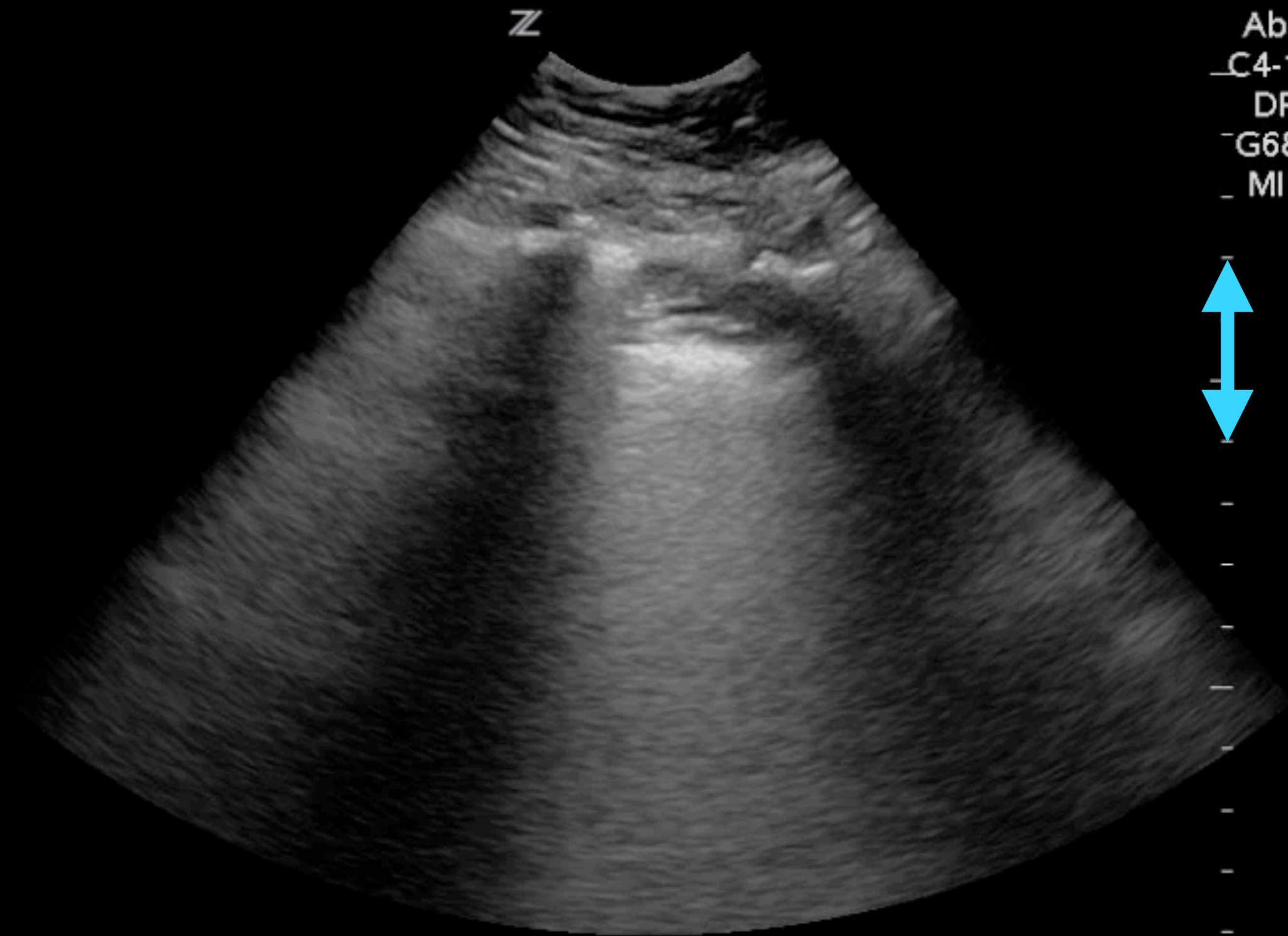Abd/General
_C4-1/CH4MHz
DR60/M3/P2
^G68/E1/100%
_MI1.2 TIs0.4
14.0 cm
- 12 Hz
△ ZSI 0
Image

Subpleural consolidation
May represent pulmonary embolism



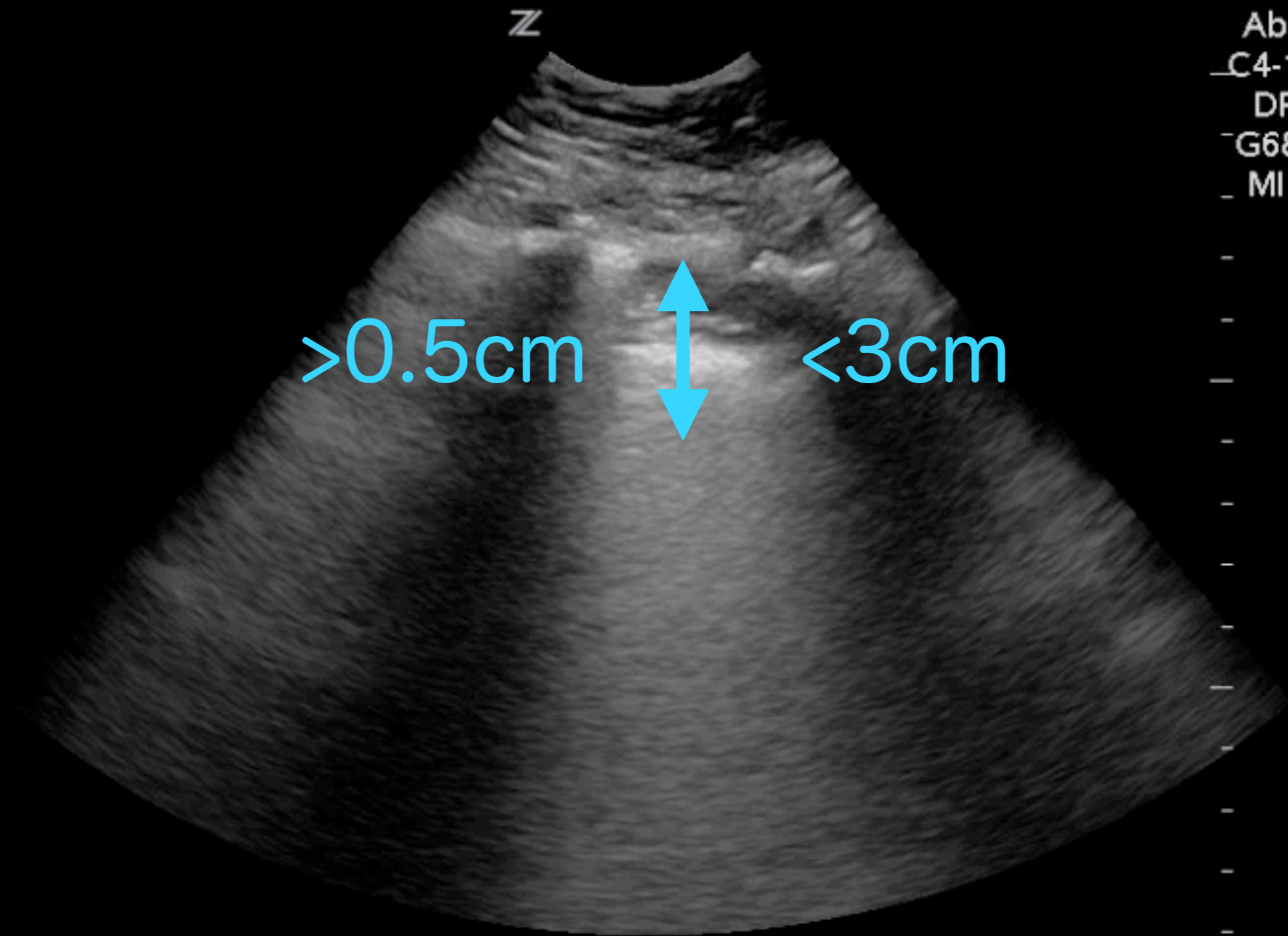
Abd/General
_C4-1/CH4MHz
DR60/M3/P2
^G68/E1/100%
_MI1.2 TIs0.4
14.0 cm
- 12 Hz
△ ZSI 0
Image

Subpleural consolidation
May represent pulmonary embolism



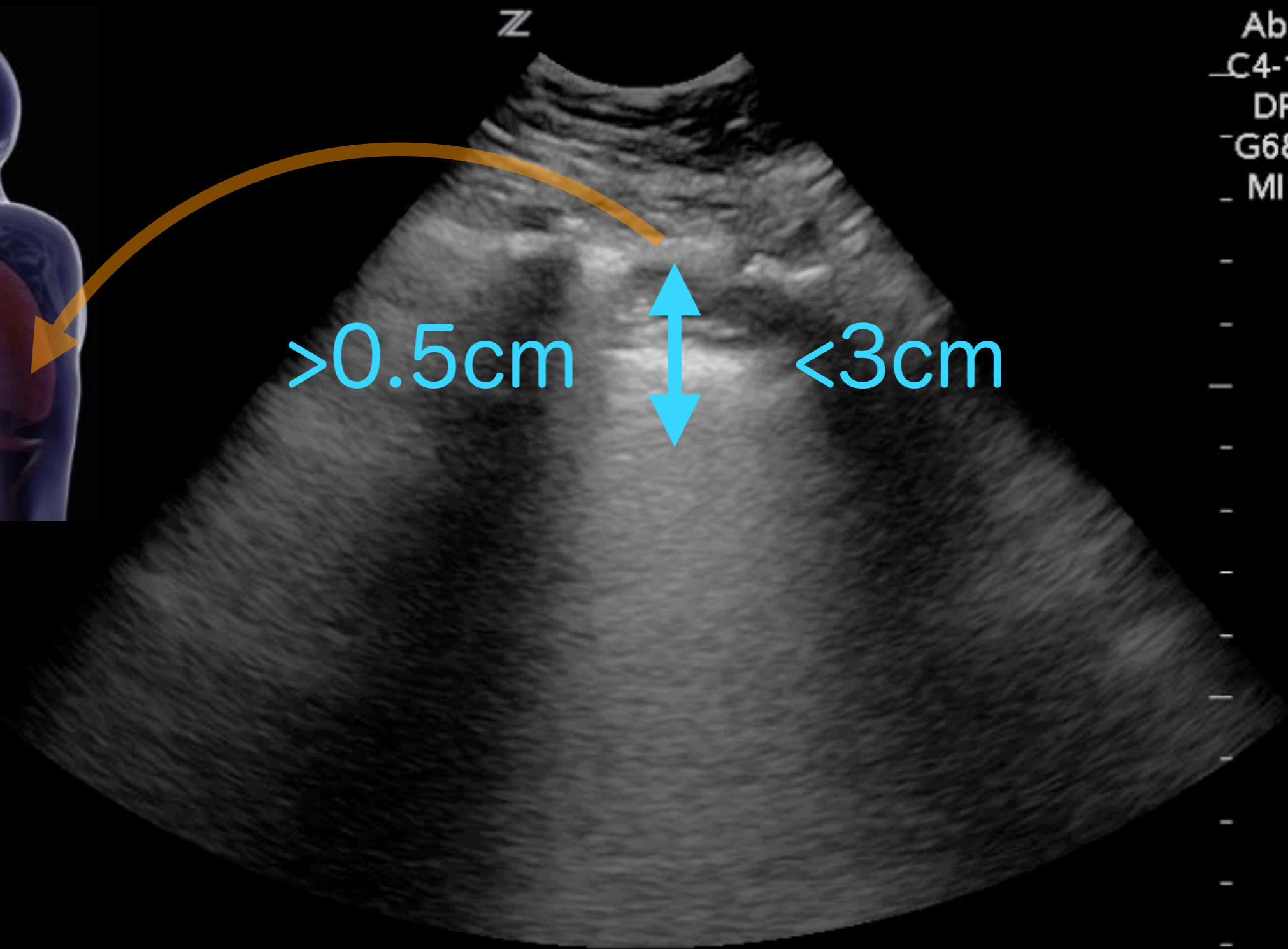
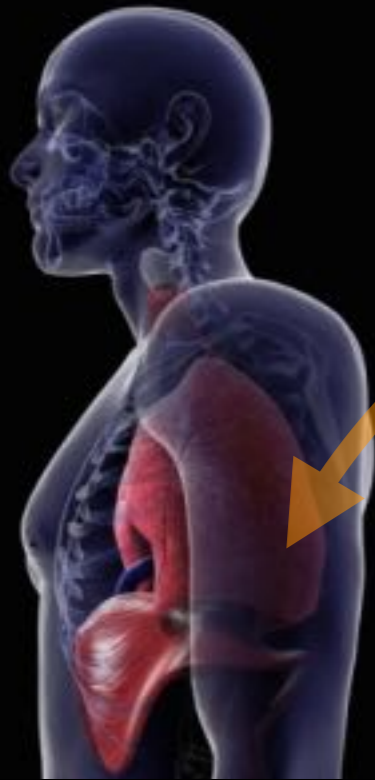Abd/General
_C4-1/CH4MHz
DR60/M3/P2
~G68/E1/100%
_ MI1.2 TIs0.4
14.0 cm
12 Hz
△ ZSI 0
Image

Subpleural consolidation
May represent pulmonary embolism



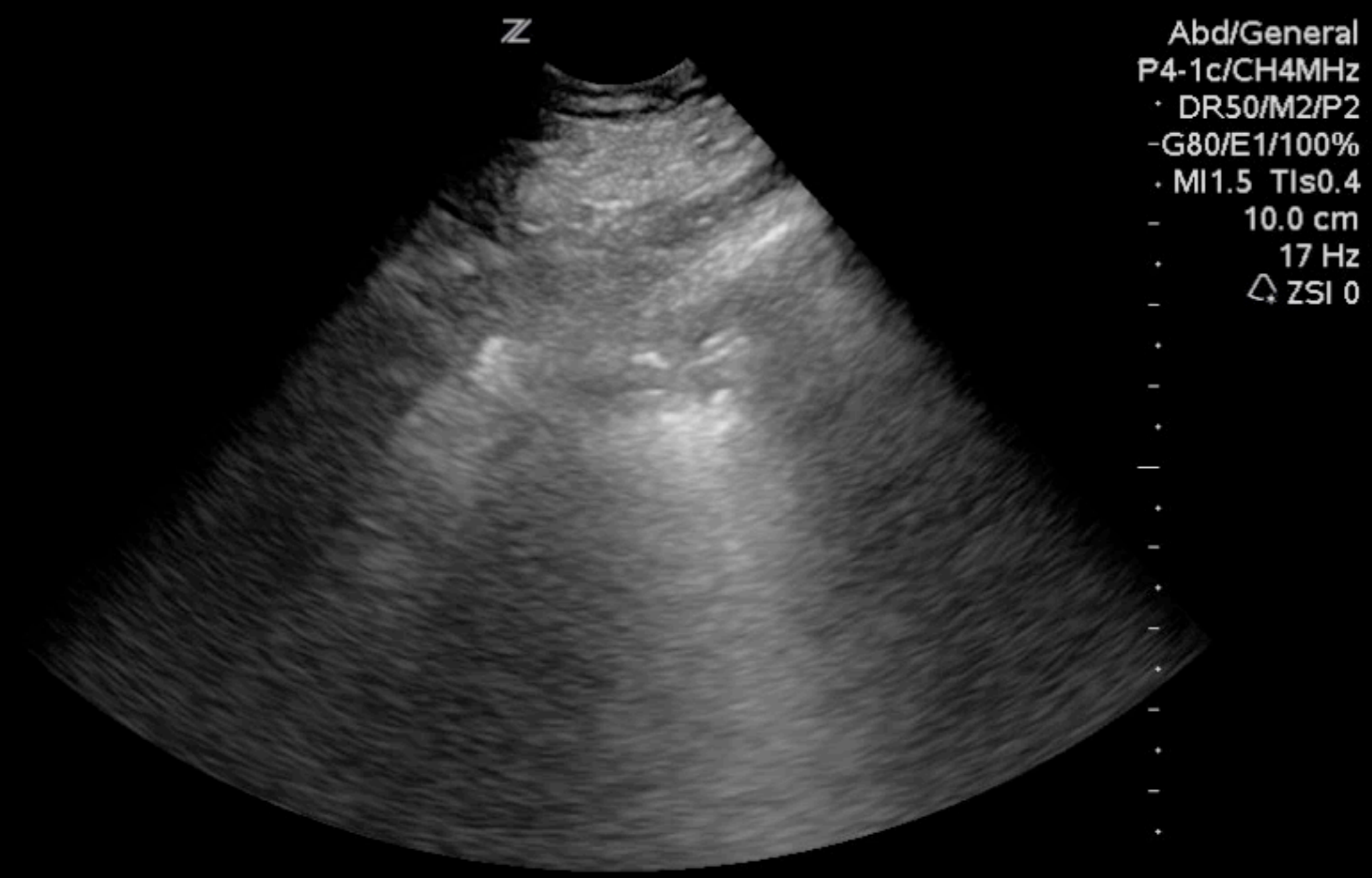Abd/General
_C4-1/CH4MHz
DR60/M3/P2
~G68/E1/100%
_ MI1.2 TIs0.4
14.0 cm
- 12 Hz
△ ZSI 0
Image

Subpleural consolidation
May represent pulmonary embolism

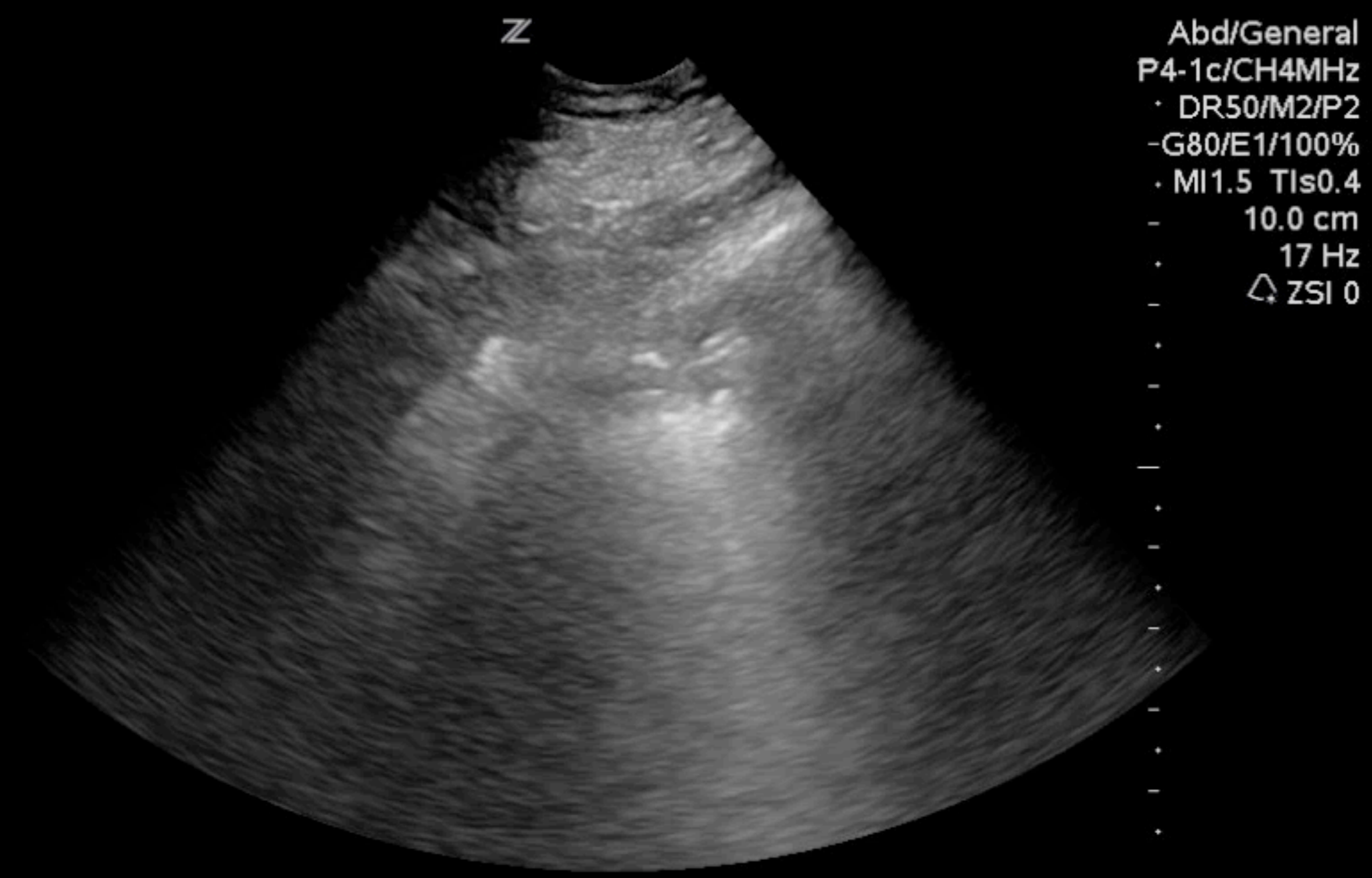


Abd/General
_C4-1/CH4MHz
DR60/M3/P2
_G68/E1/100%
_MI1.2 TIs0.4
14.0 cm
12 Hz
△ ZSI 0
Image

Subpleural consolidation
May represent pulmonary embolism



Subpleural consolidation

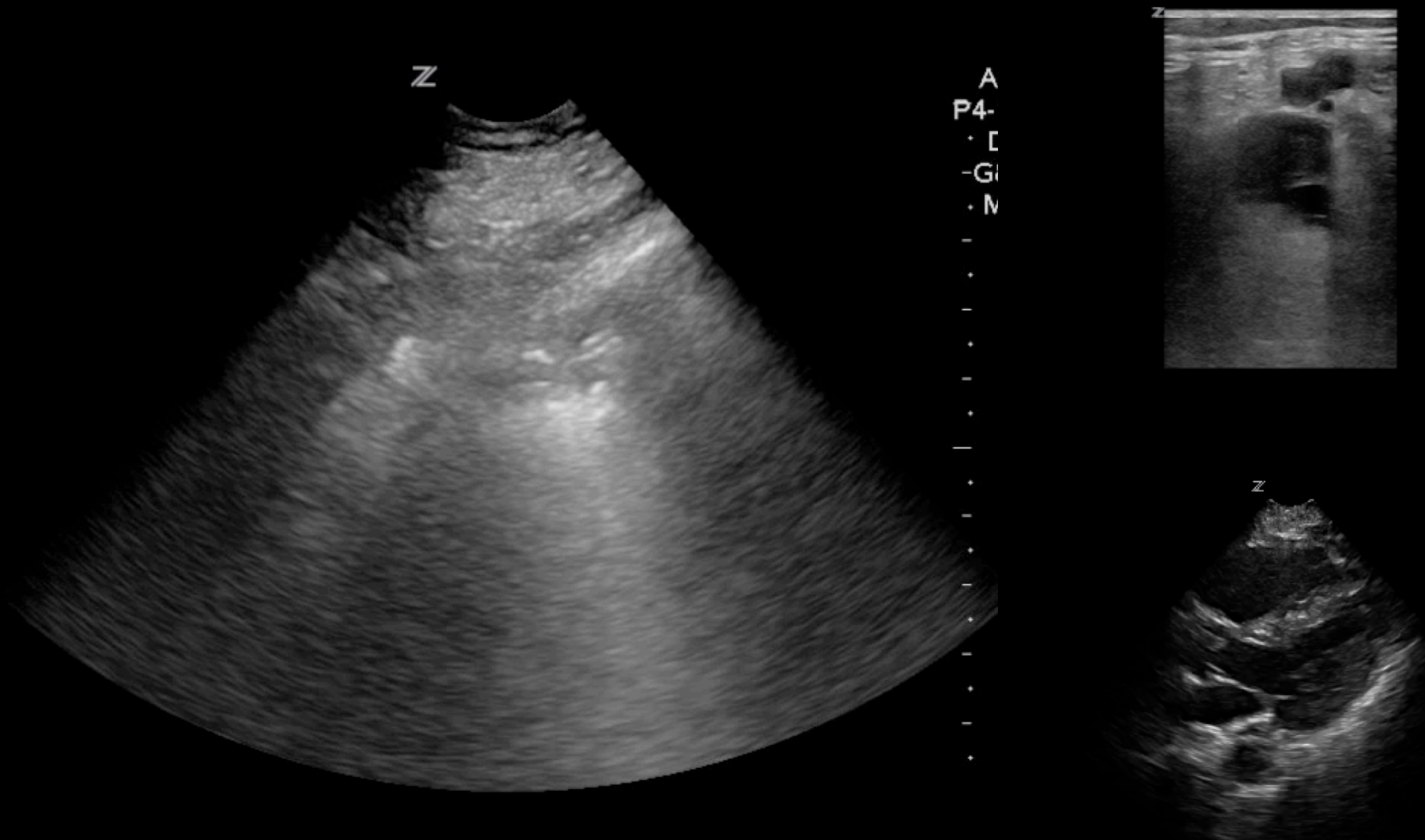

Subpleural consolidation



Abd/General
P4-1c/CH4MHz
· DR50/M2/P2
-G80/E1/100%
· MI1.5 TIs0.4
- 10.0 cm
· 17 Hz
△ ZSI 0

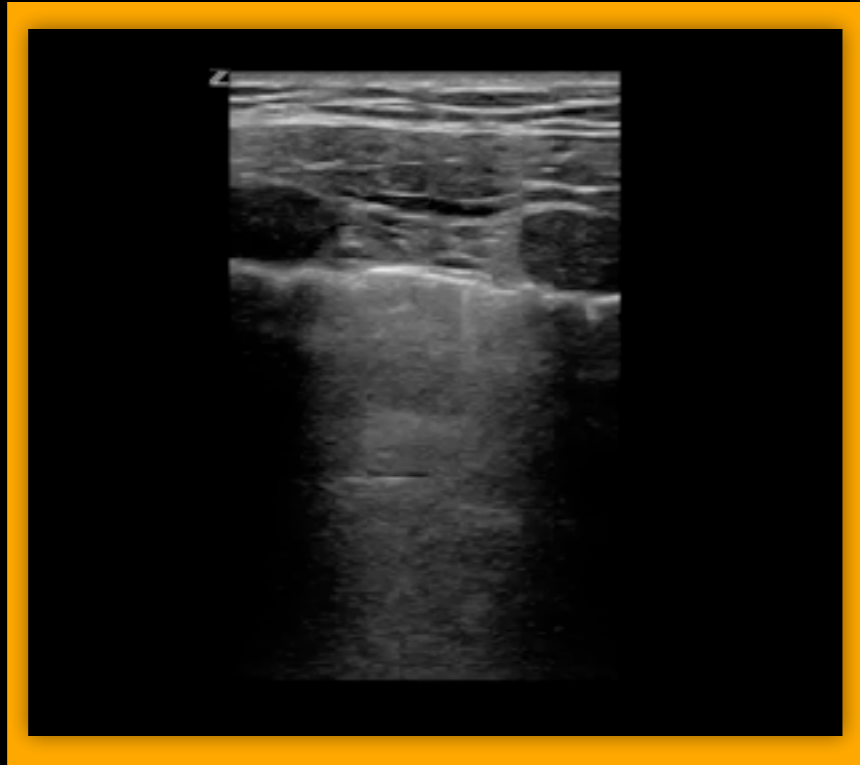
Subpleural consolidation
Surrounding B-lines more c/w infection



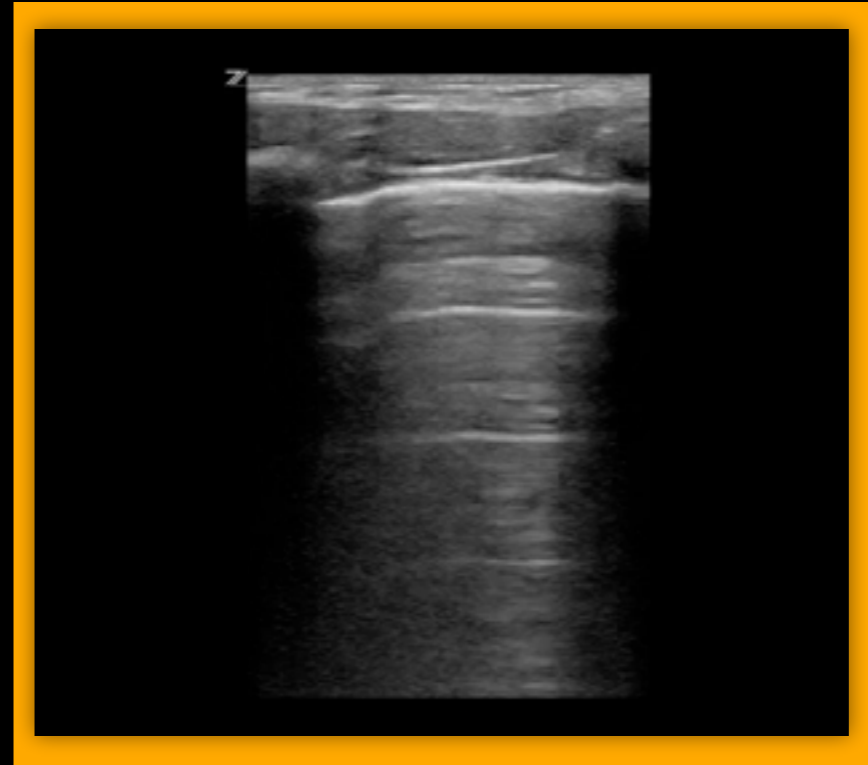
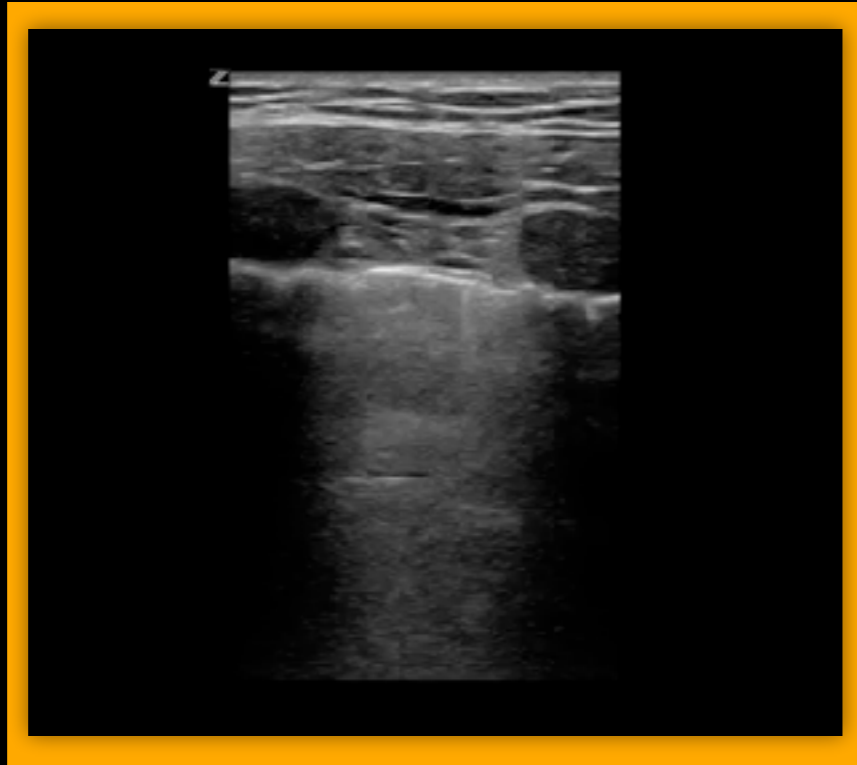
Subpleural consolidation
Surrounding B-lines more c/w infection

Take home points

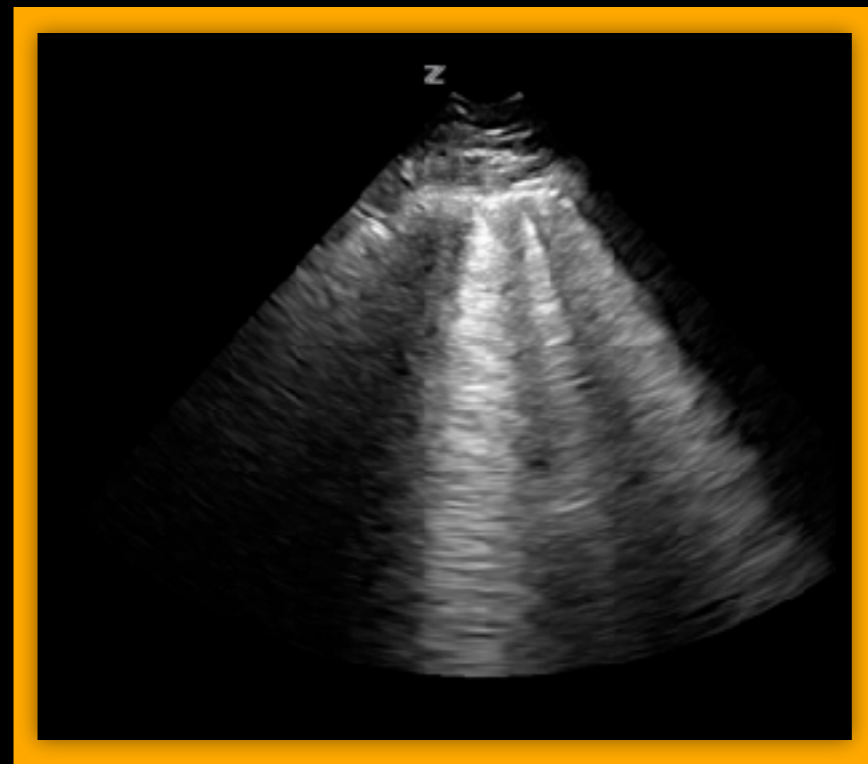
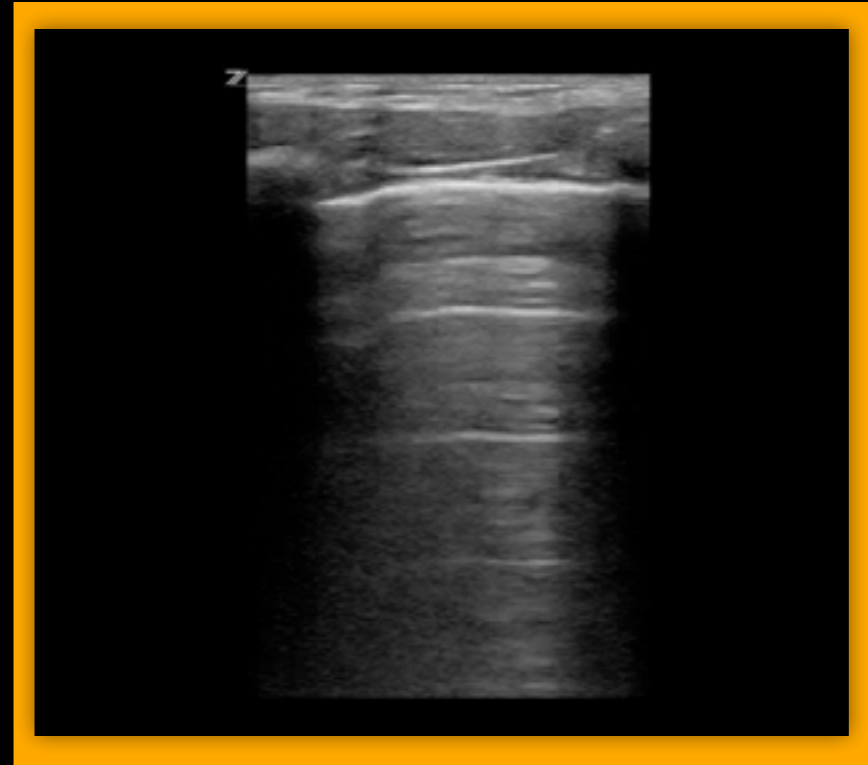
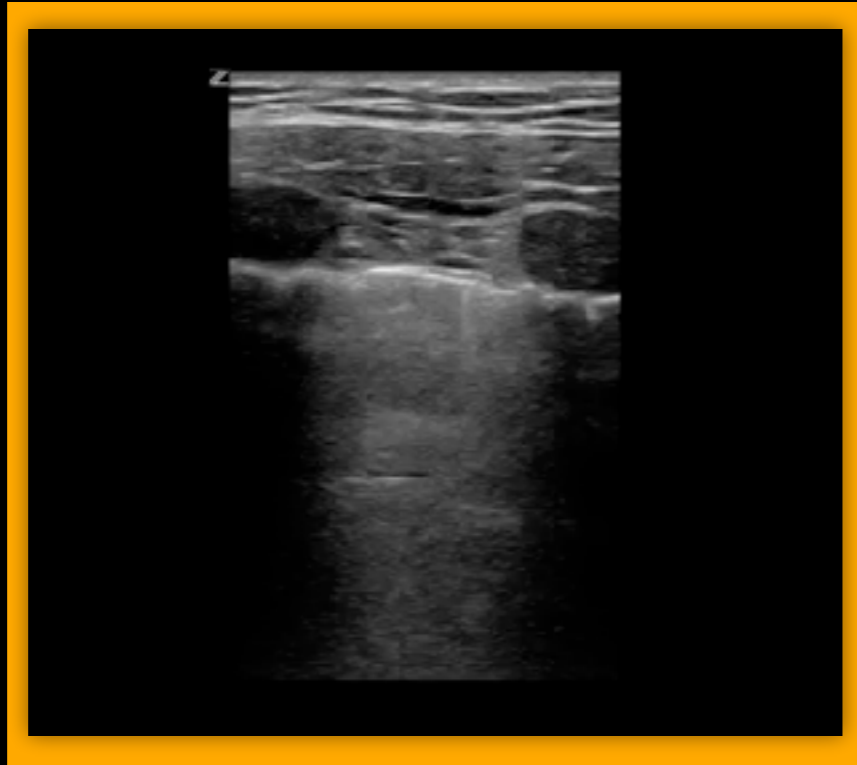
Take home points



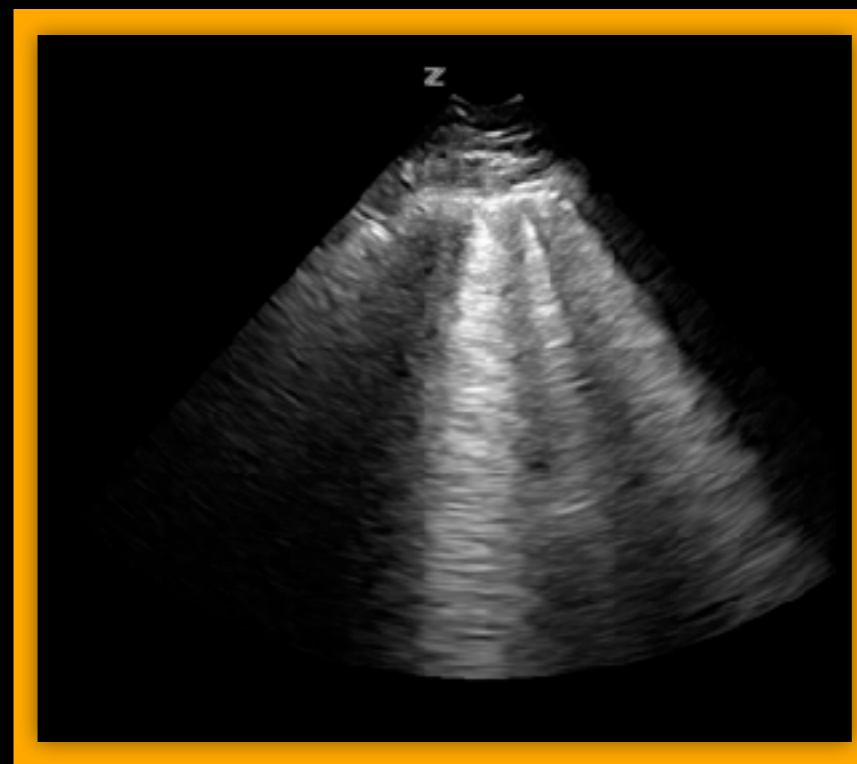
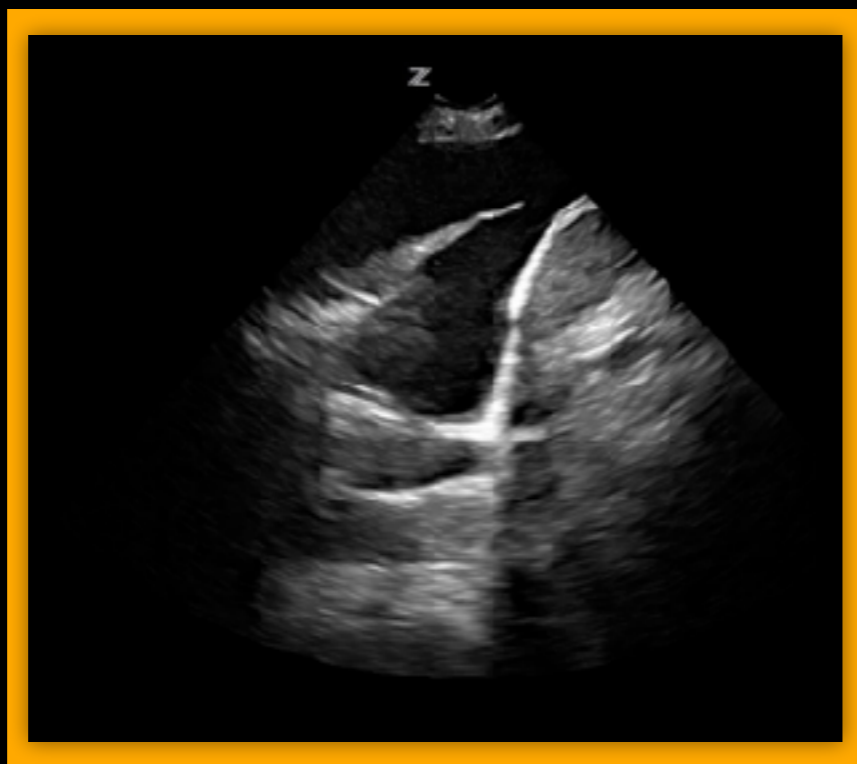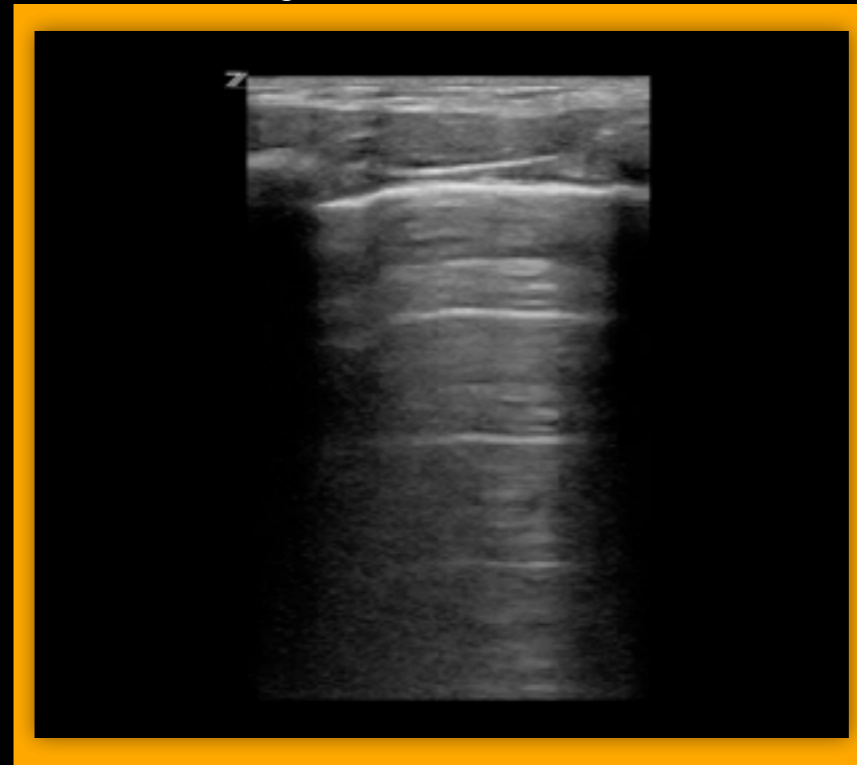
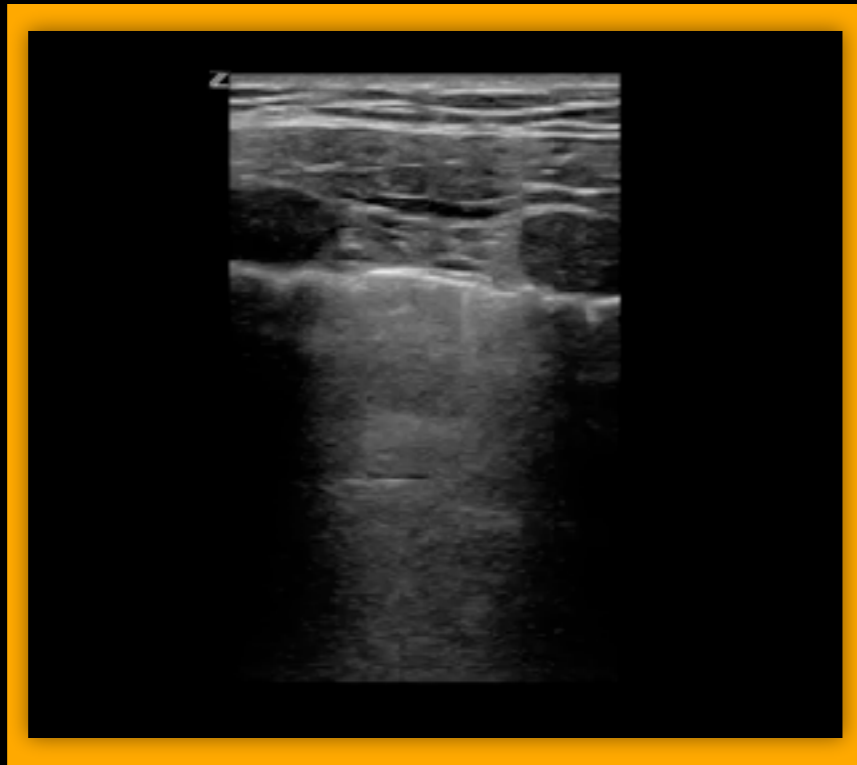Take home points



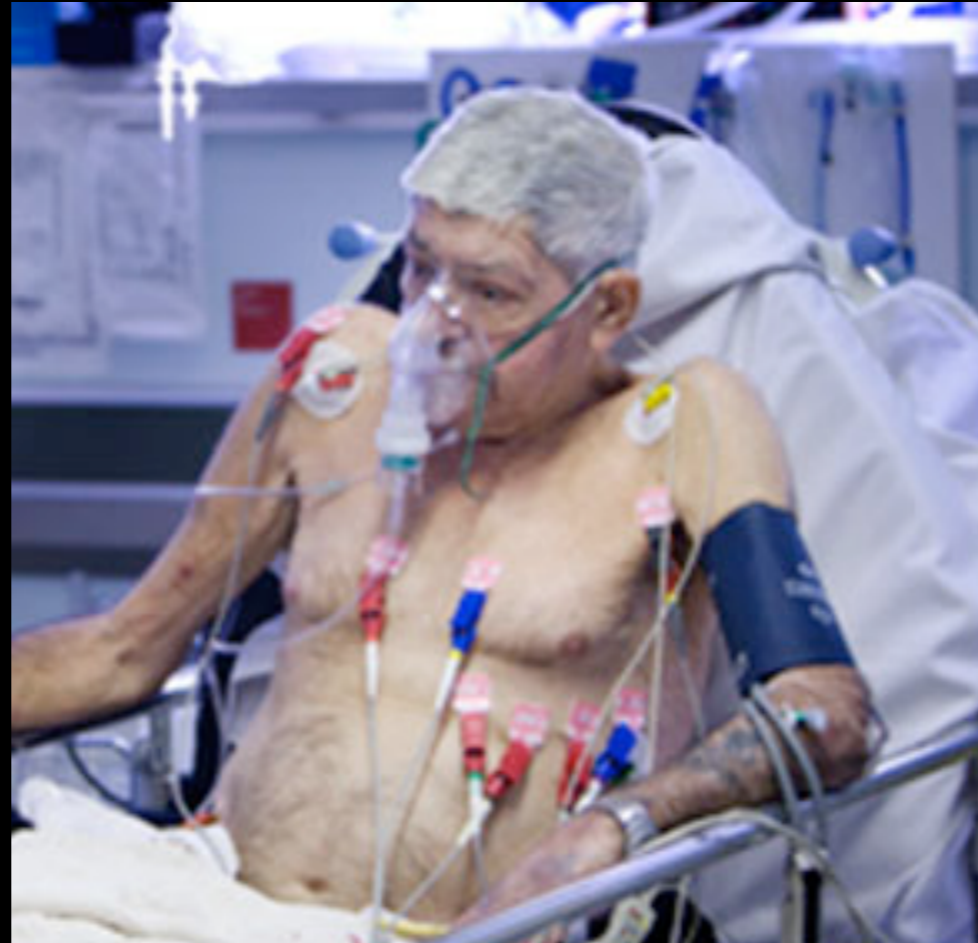Take home points



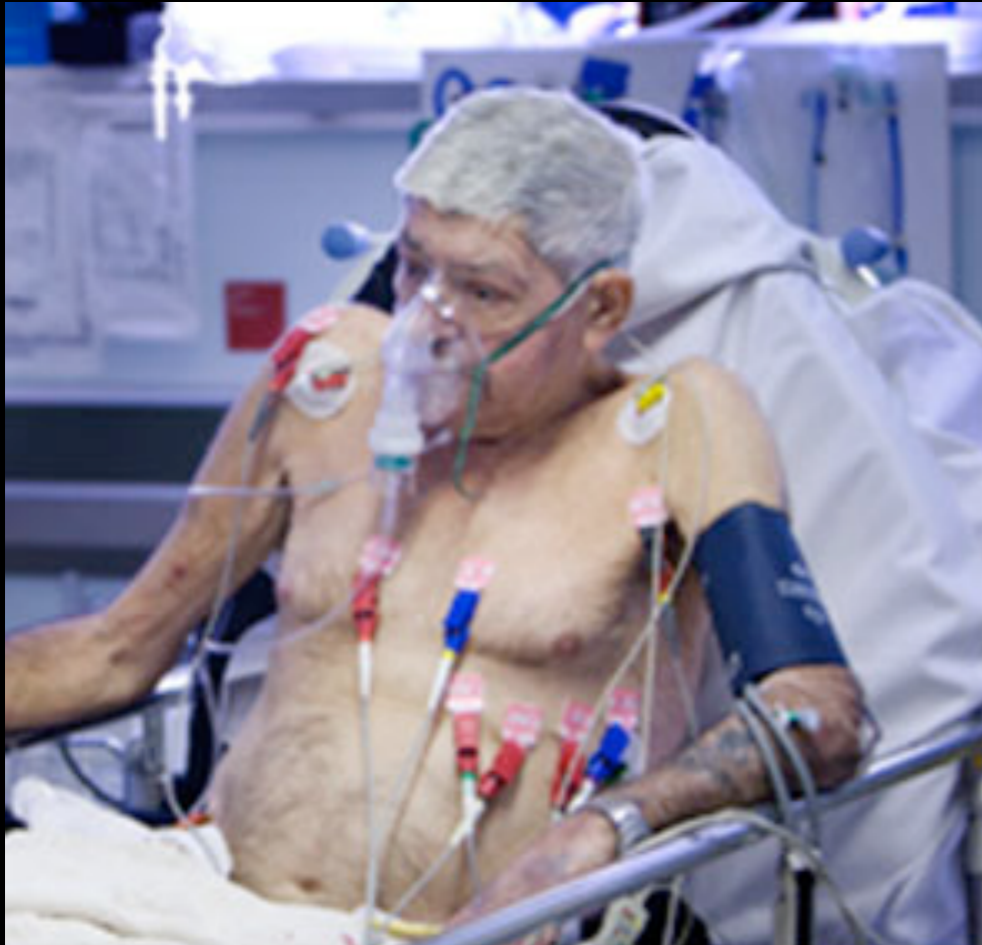Take home points



Case: Dyspnea

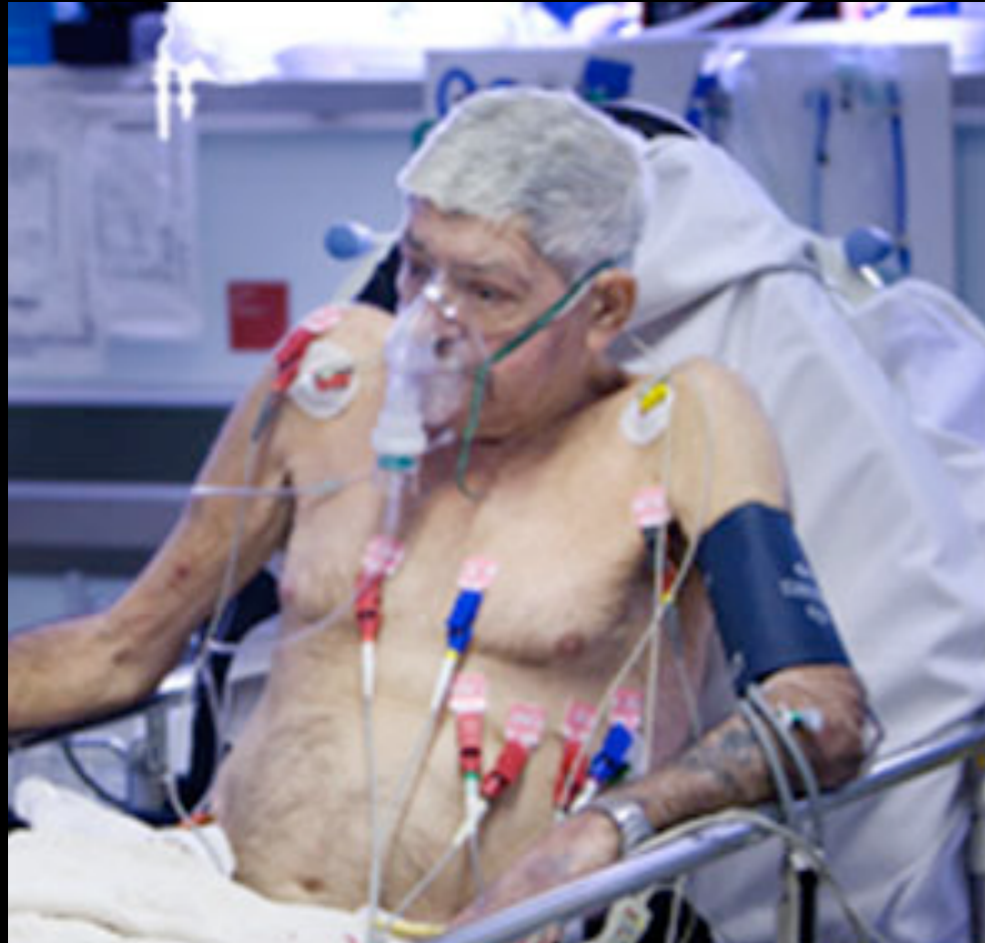

Case: Dyspnea



78 y/o M DM, CHF, COPD
2 days of worsening SOB
T 99, BP 188/75, HR 110,
SpO₂ 88%
Moderate air movement,
wheezing, 1+ PE BLE

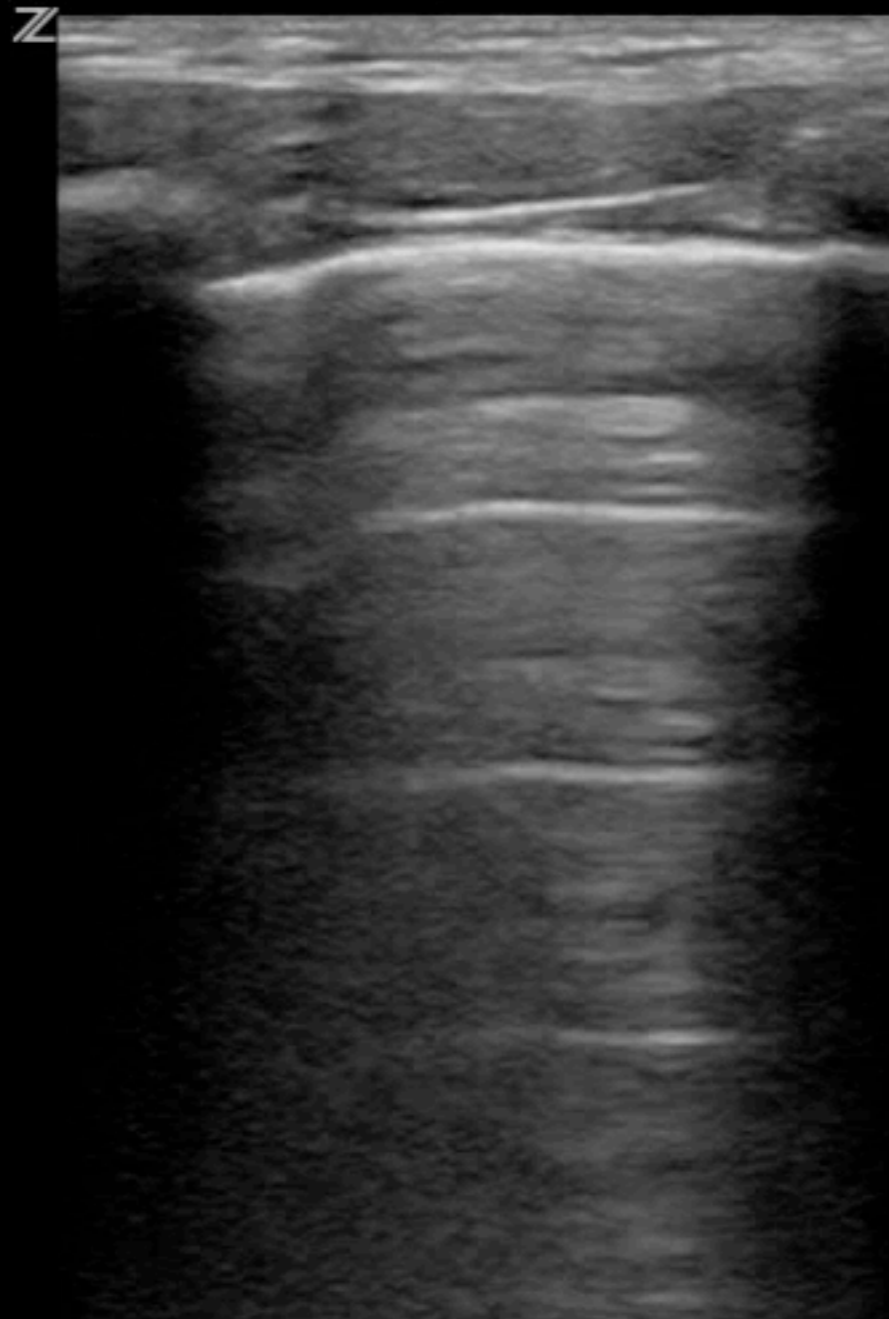
Case: Dyspnea



78 y/o M DM, CHF, COPD
2 days of worsening SOB
T 99, BP 188/75, HR 110,
SpO2 88%
Moderate air movement,
wheezing, 1+ PE BLE

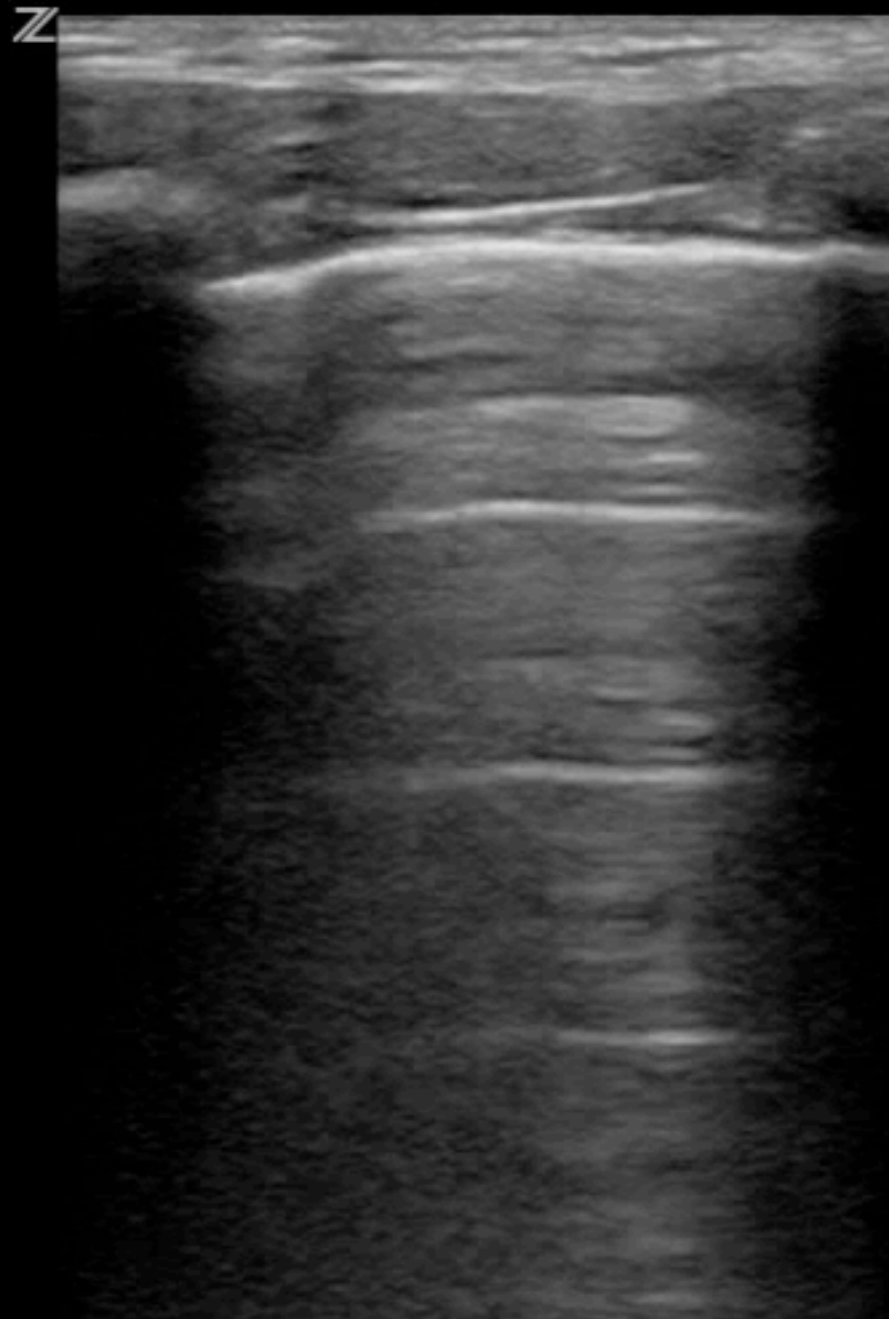
Treatment: ?

BiPap + (Nebs/Steroids vs NTG)



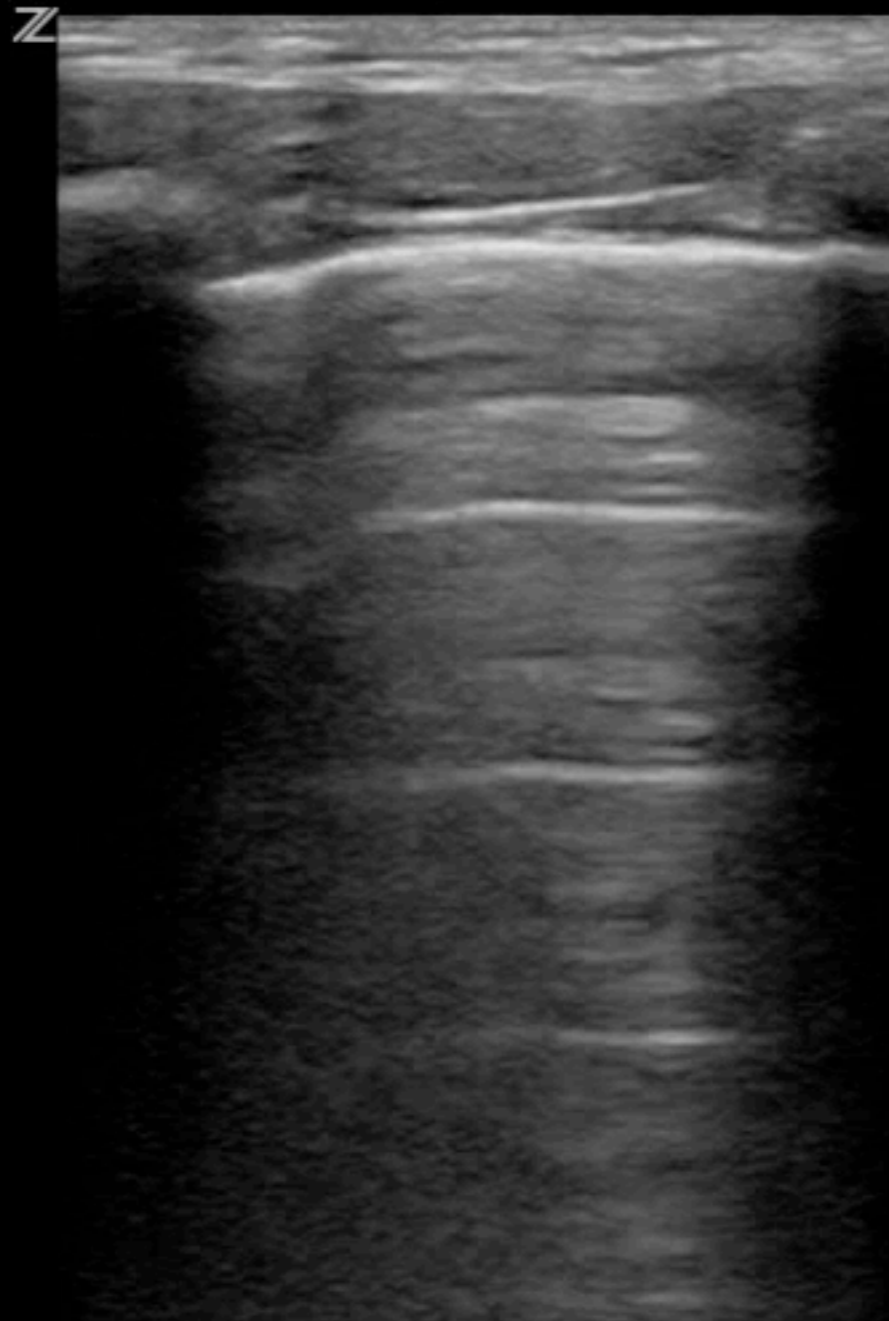
— Abd/PTX
L10-5/CH8MHz
· DR70/M3/P2
G86/E2/100%
- MI1.3 TIs0.1
6.0 cm
· 12 Hz
△ ZSI 0

Anterior lung spaces



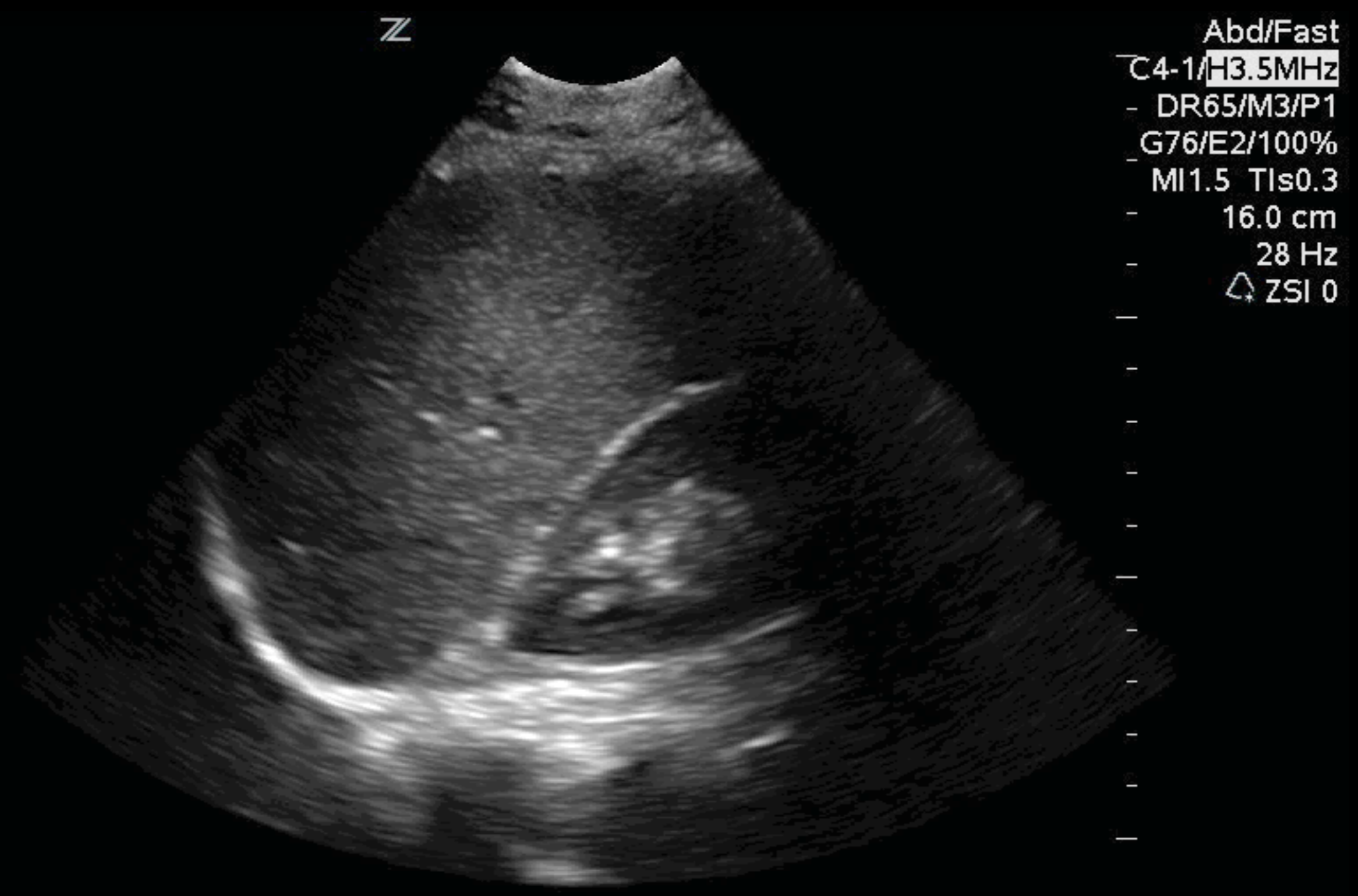
— Abd/PTX
L10-5/CH8MHz
· DR70/M3/P2
G86/E2/100%
- MI1.3 TIs0.1
6.0 cm
· 12 Hz
△ ZSI 0

Anterior lung spaces

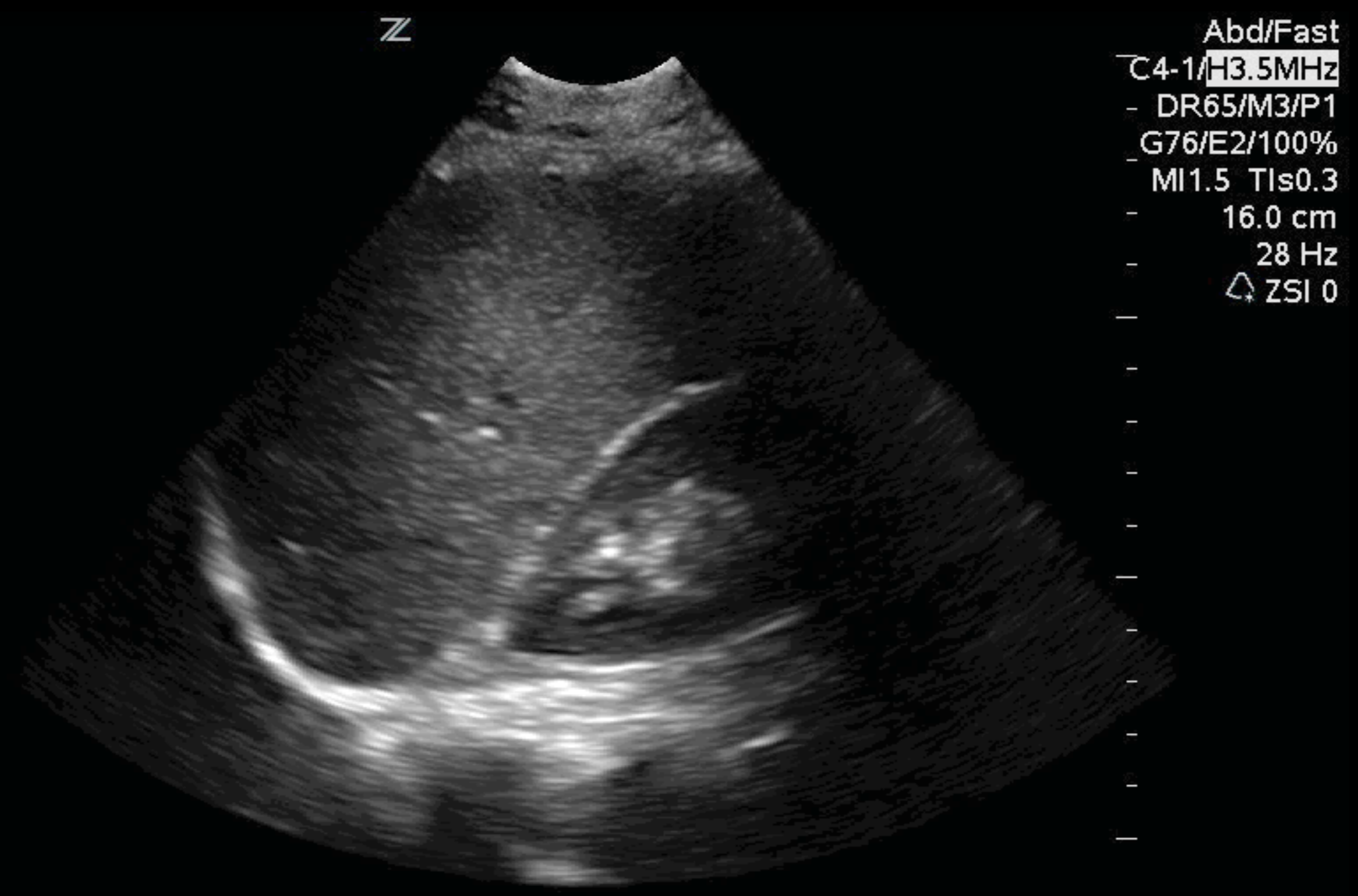


— Abd/PTX
L10-5/CH8MHz
· DR70/M3/P2
G86/E2/100%
- MI1.3 TIs0.1
6.0 cm
· 12 Hz
△ ZSI 0

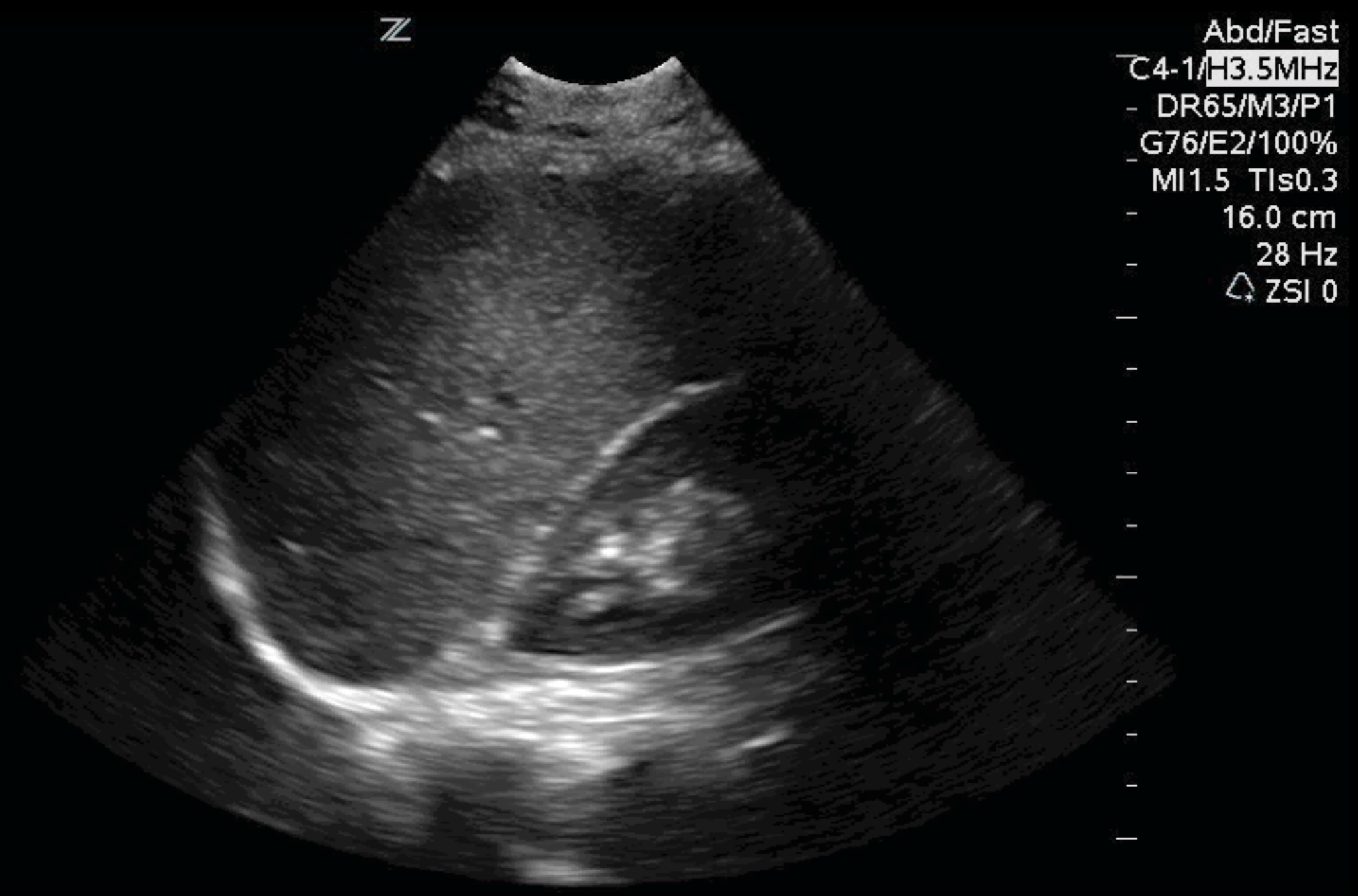
Anterior lung spaces
(+) lung sliding, A-lines



Pleural spaces



Pleural spaces

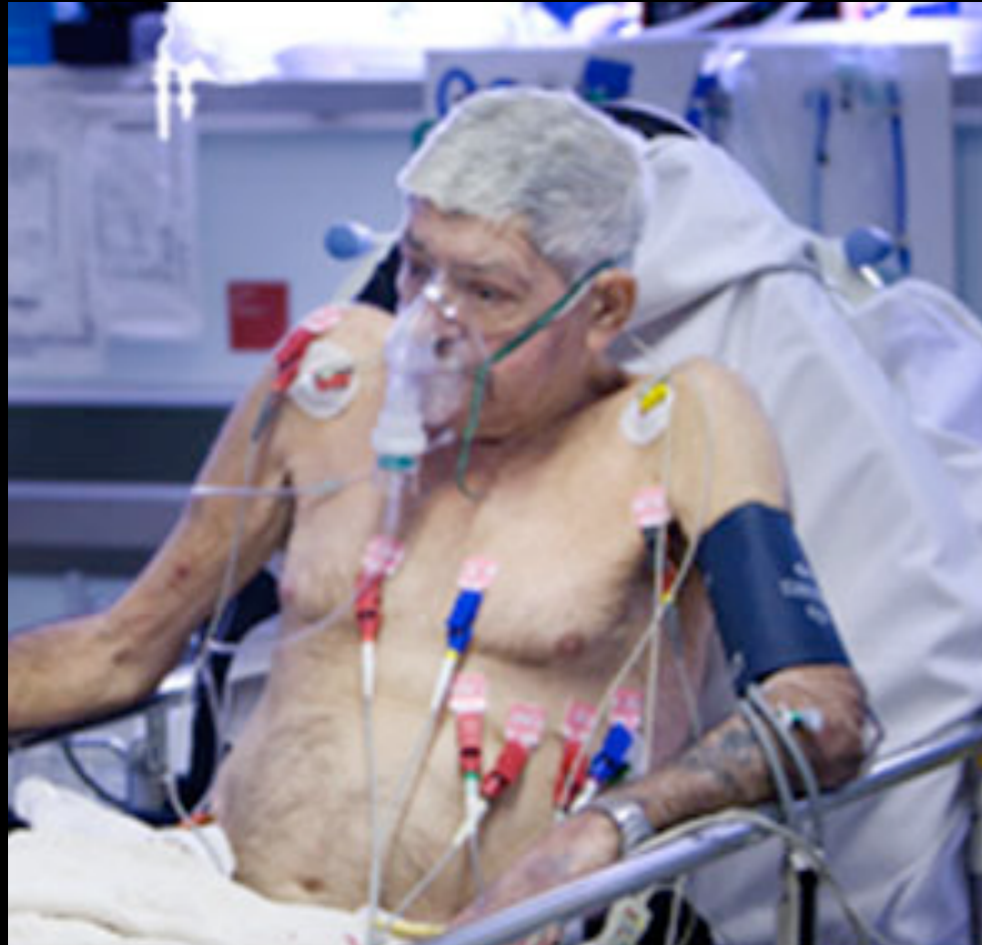

Pleural spaces
No pleural effusion

Case: Dyspnea

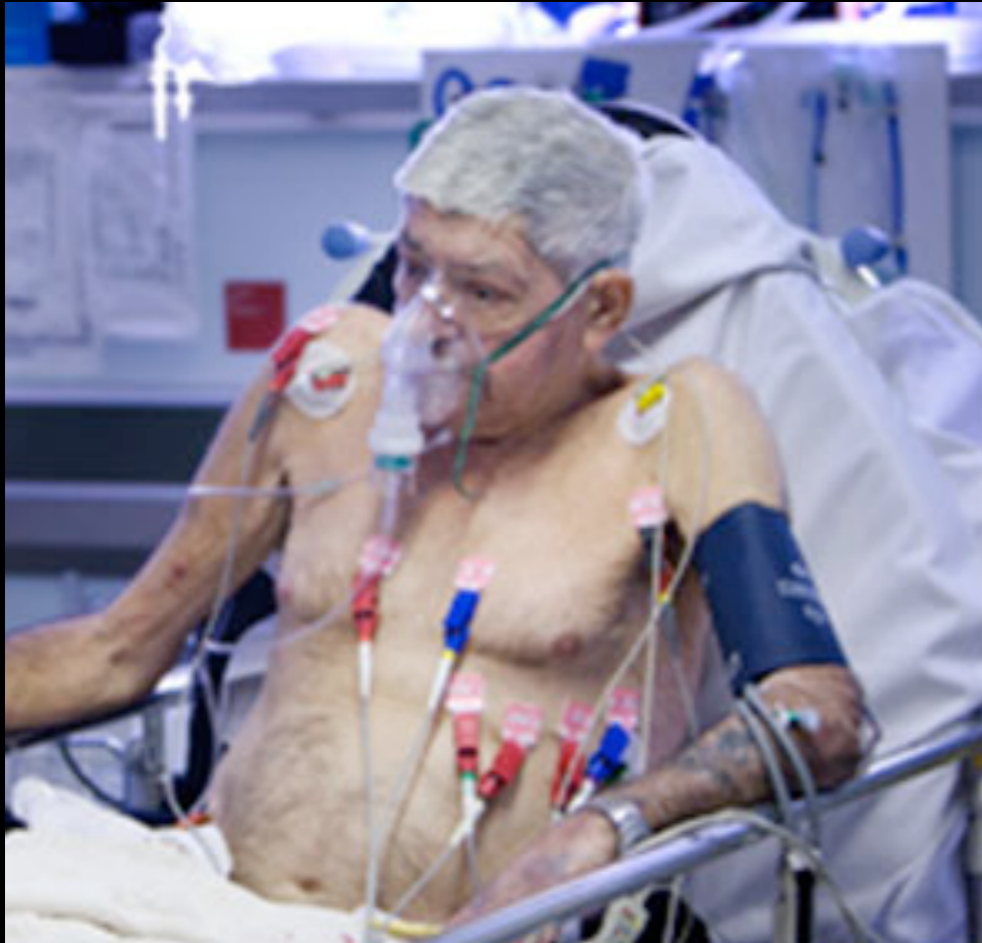

Case: Dyspnea



78 y/o M DM, CHF, COPD
2 days of worsening SOB
T 99, BP 188/75, HR 110,
SpO2 88%
Moderate air movement,
wheezing, 1+ PE BLE

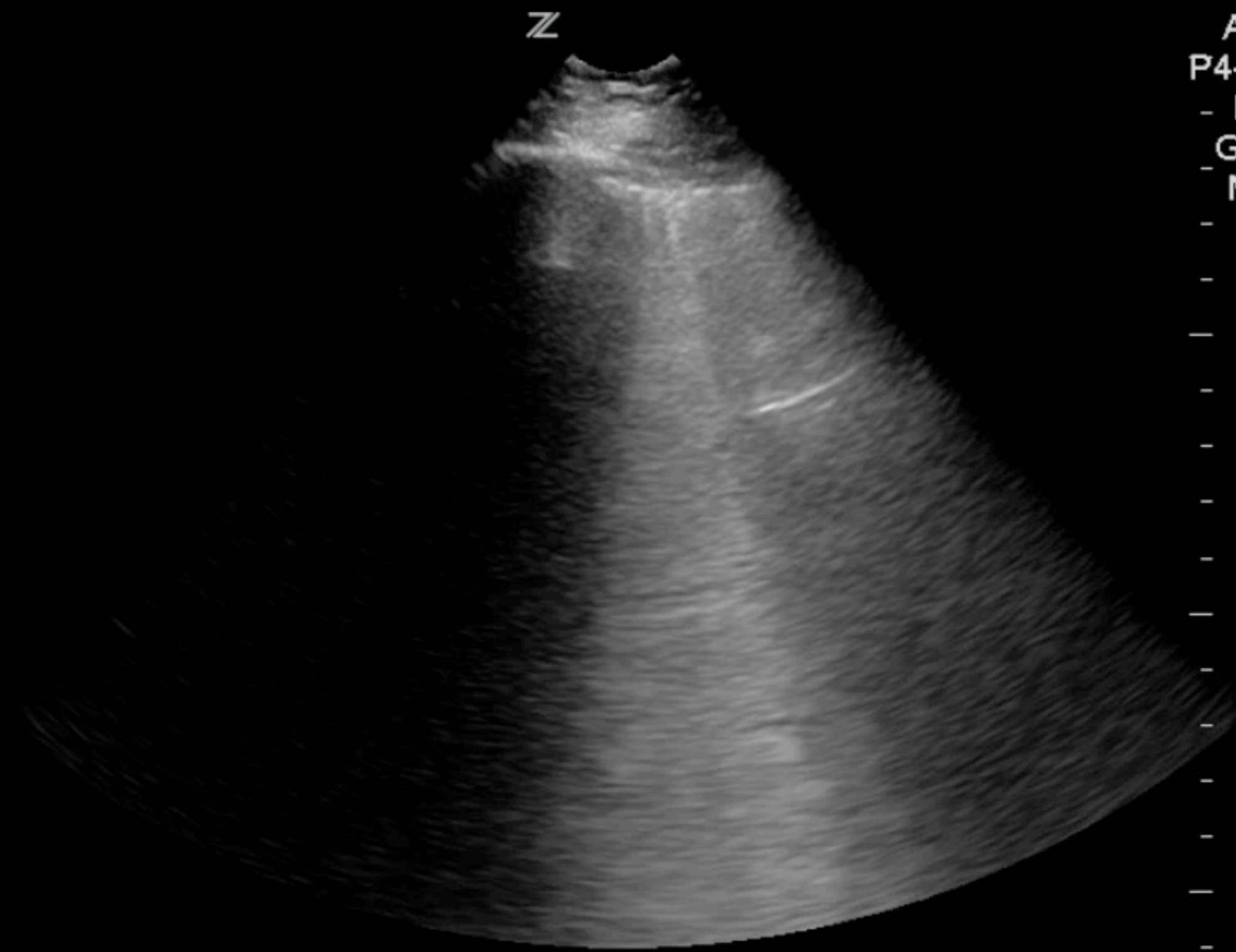
Case: Dyspnea



78 y/o M DM, CHF, COPD
2 days of worsening SOB
T 99, BP 188/75, HR 110,
SpO2 88%
Moderate air movement,
wheezing, 1+ PE BLE

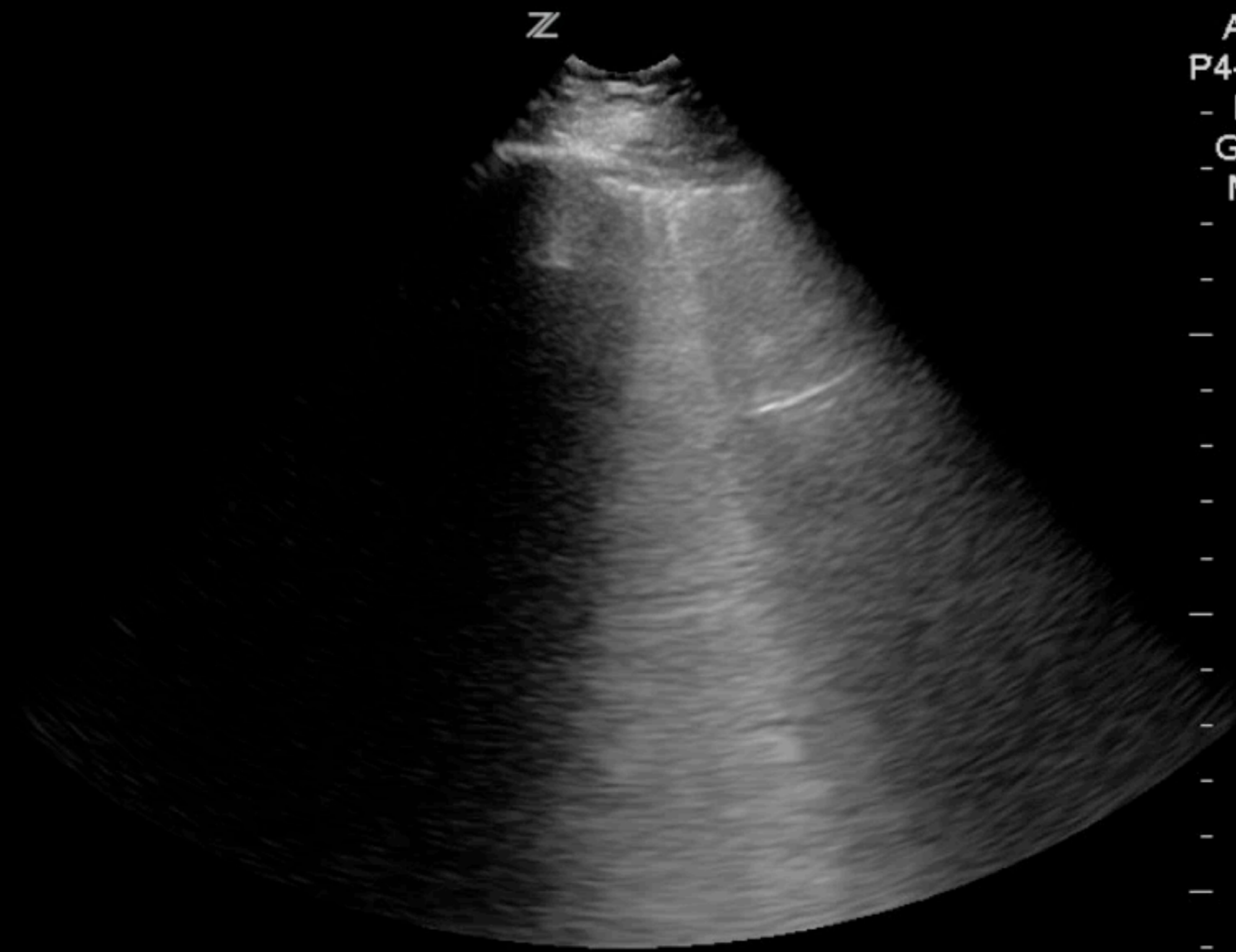
Treatment: ?

BiPap + (Nebs/Steroids vs NTG)



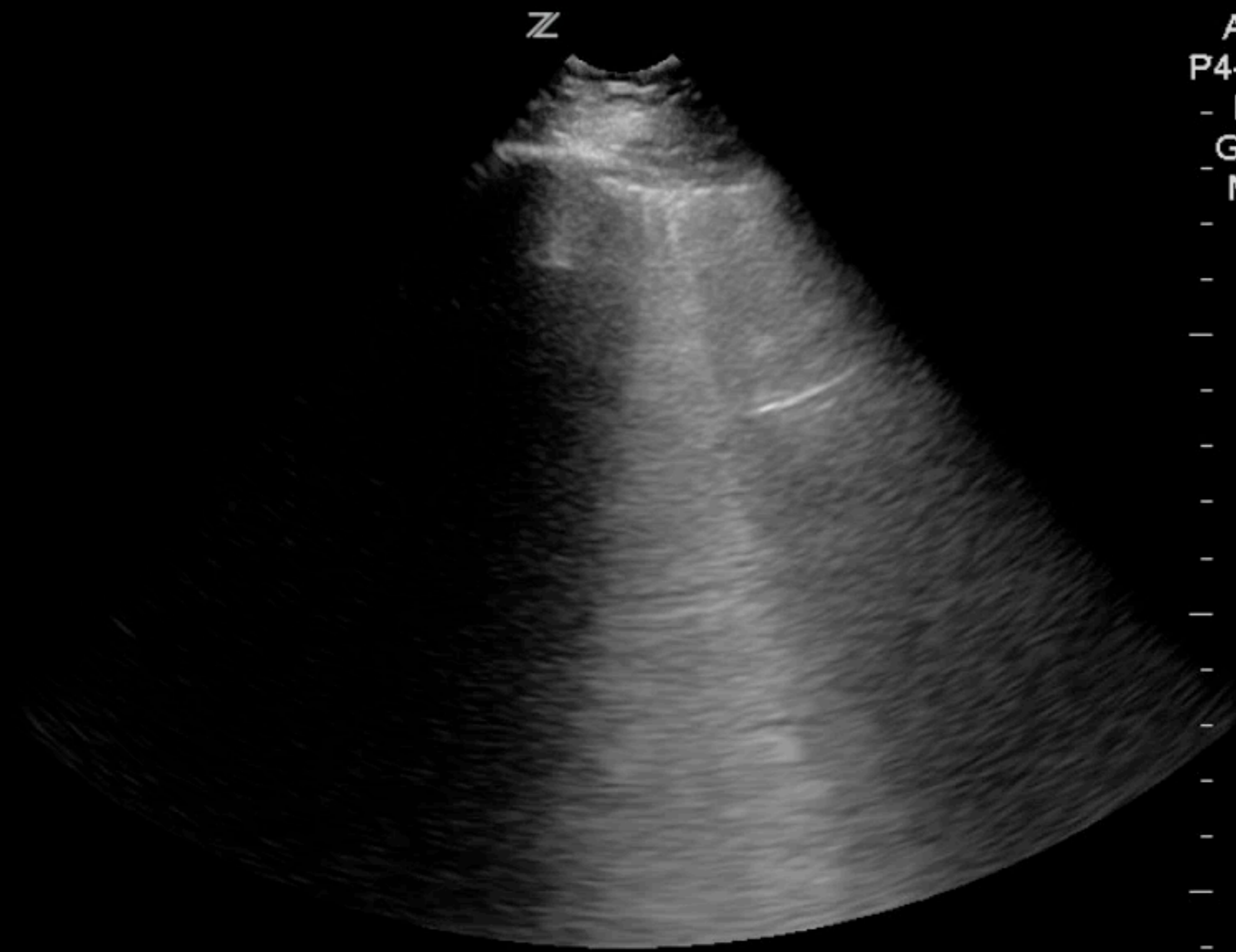
Abd/General
P4-1c/CH4MHz
- DR50/M2/P2
G76/E1/100%
- MI1.5 TIs0.6
- 16.0 cm
- 19 Hz
△ ZSI 0
Image

Anterior lung spaces



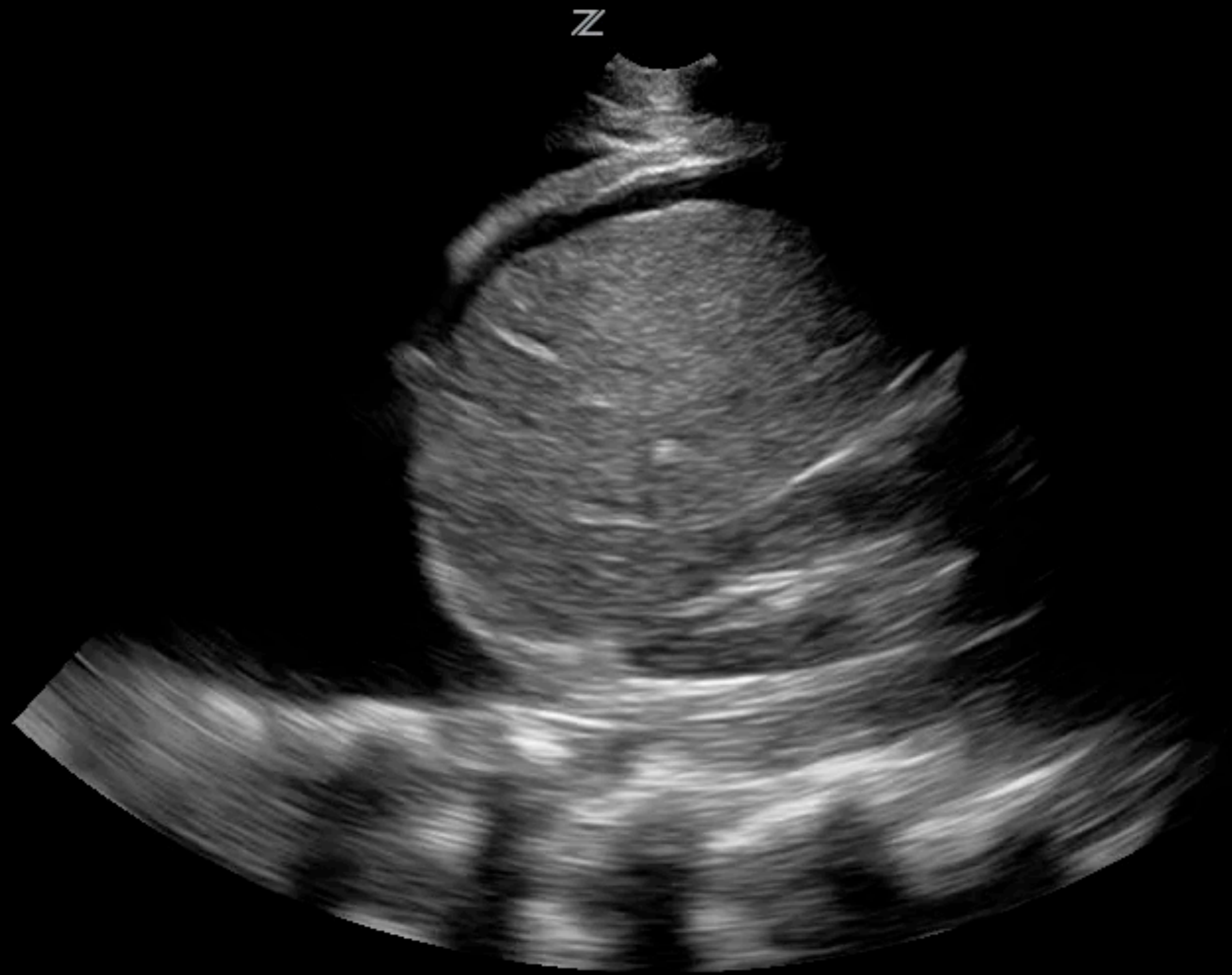Abd/General
P4-1c/CH4MHz
- DR50/M2/P2
G76/E1/100%
- MI1.5 TIs0.6
- 16.0 cm
- 19 Hz
△ ZSI 0
Image

Anterior lung spaces



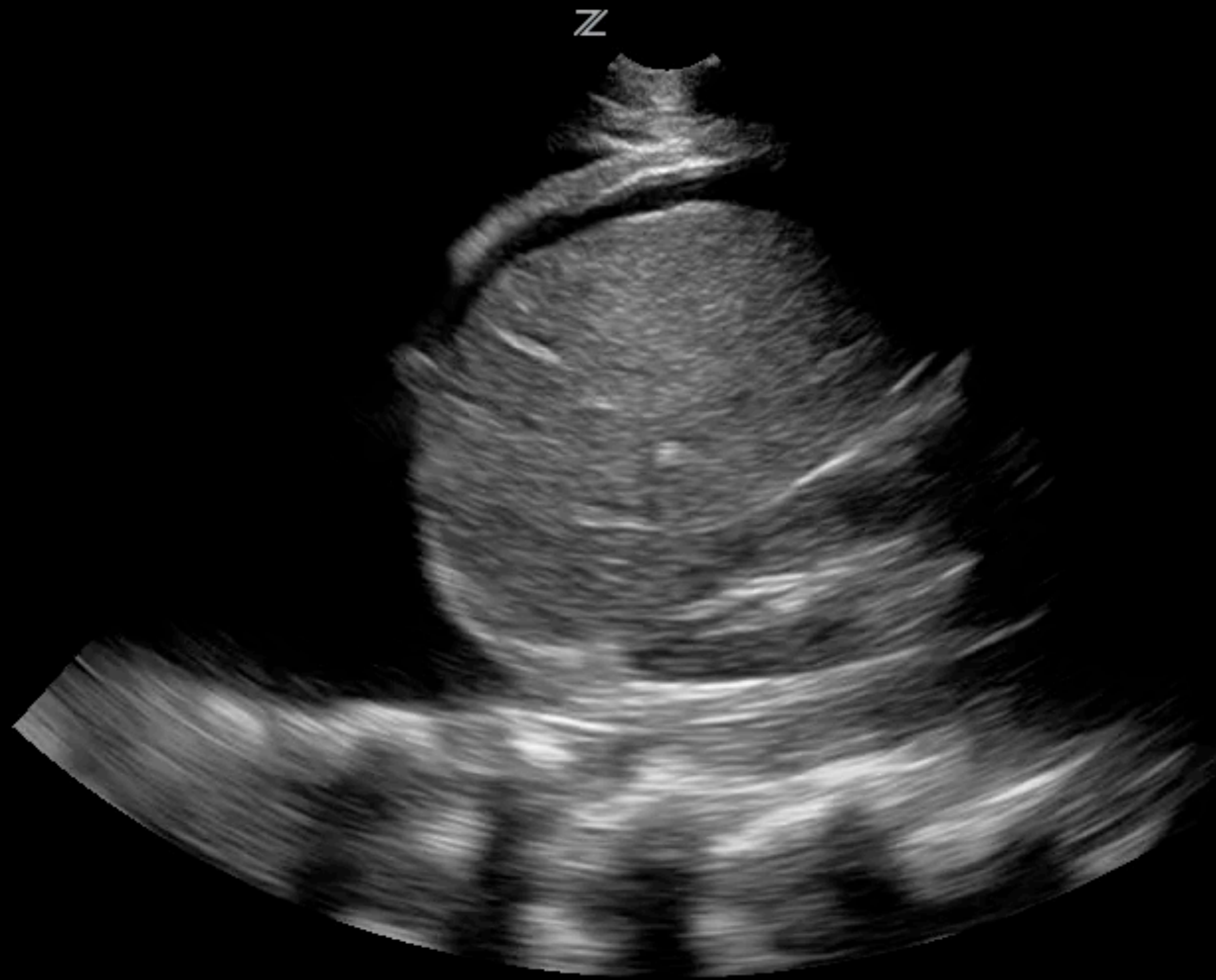Abd/General
P4-1c/CH4MHz
- DR50/M2/P2
G76/E1/100%
- MI1.5 TIs0.6
- 16.0 cm
- 19 Hz
△ ZSI 0
Image

Anterior lung spaces
B-lines



Abd/Thoracic
- P4-1c/4MHz
- DR50/M2/P2
_ G76/E1/100%
_ MI1.5 TIs1.0
_ 18.0 cm
_ 20 Hz
_ \triangle ZSI 0

Pleural spaces



Abd/Thoracic
- P4-1c/4MHz
- DR50/M2/P2
_ G76/E1/100%
_ MI1.5 TIs1.0
_ 18.0 cm
_ 20 Hz
_ \triangle ZSI 0

Pleural spaces



Abd/Thoracic
P4-1c/4MHz
DR50/M2/P2
G76/E1/100%
MI1.5 TIs1.0
18.0 cm
20 Hz
ZSI 0

Pleural spaces
(+) pleural effusion

Case: Dyspnea



Case: Dyspnea



78 y/o M DM, CHF, COPD
2 days of worsening SOB
T 99, BP 188/75, HR 110,
SpO₂ 88%
Moderate air movement,
wheezing, 1+ PE BLE

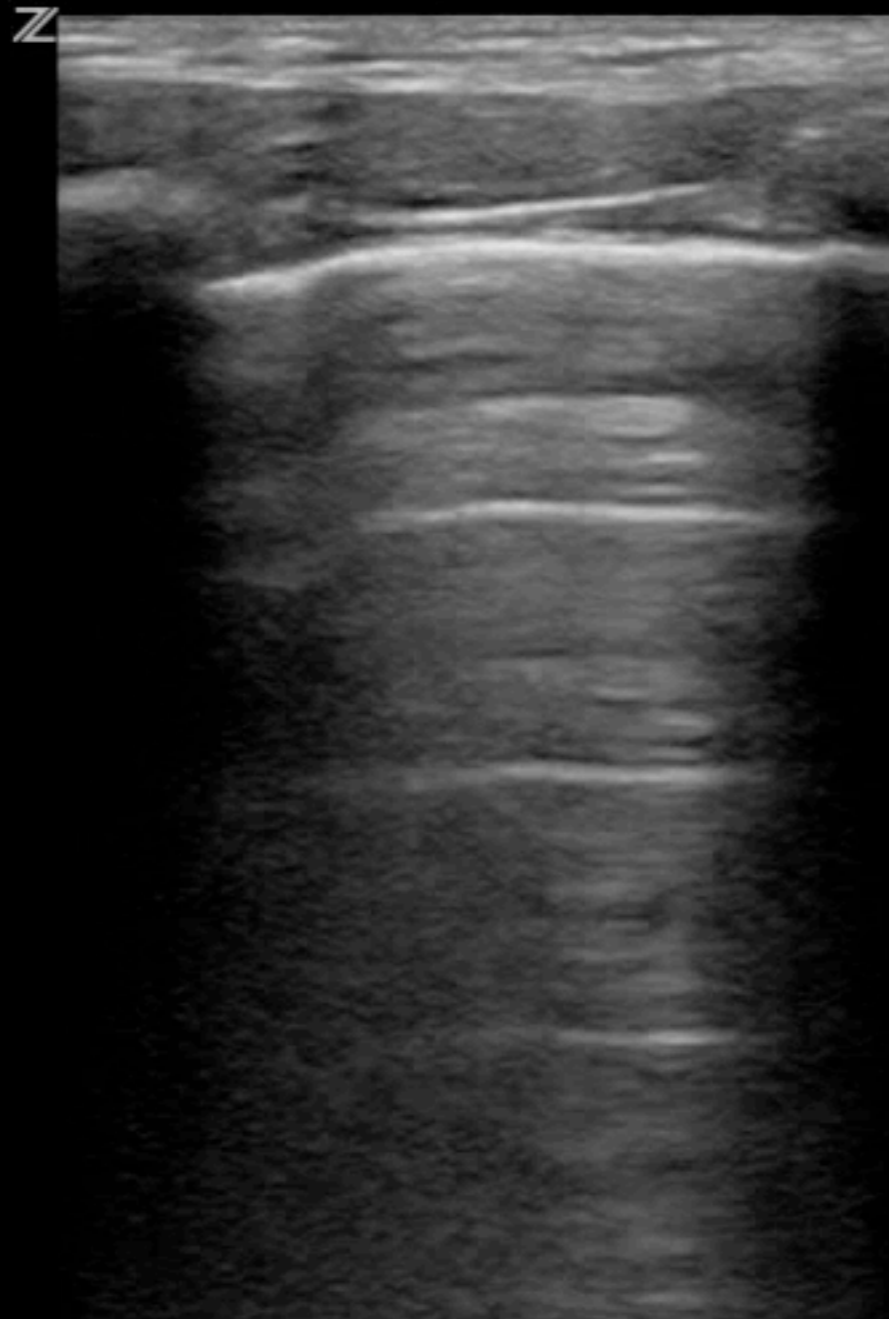
Case: Dyspnea



78 y/o M DM, CHF, COPD
2 days of worsening SOB
T 99, BP 188/75, HR 110,
SpO2 88%
Moderate air movement,
wheezing, 1+ PE BLE

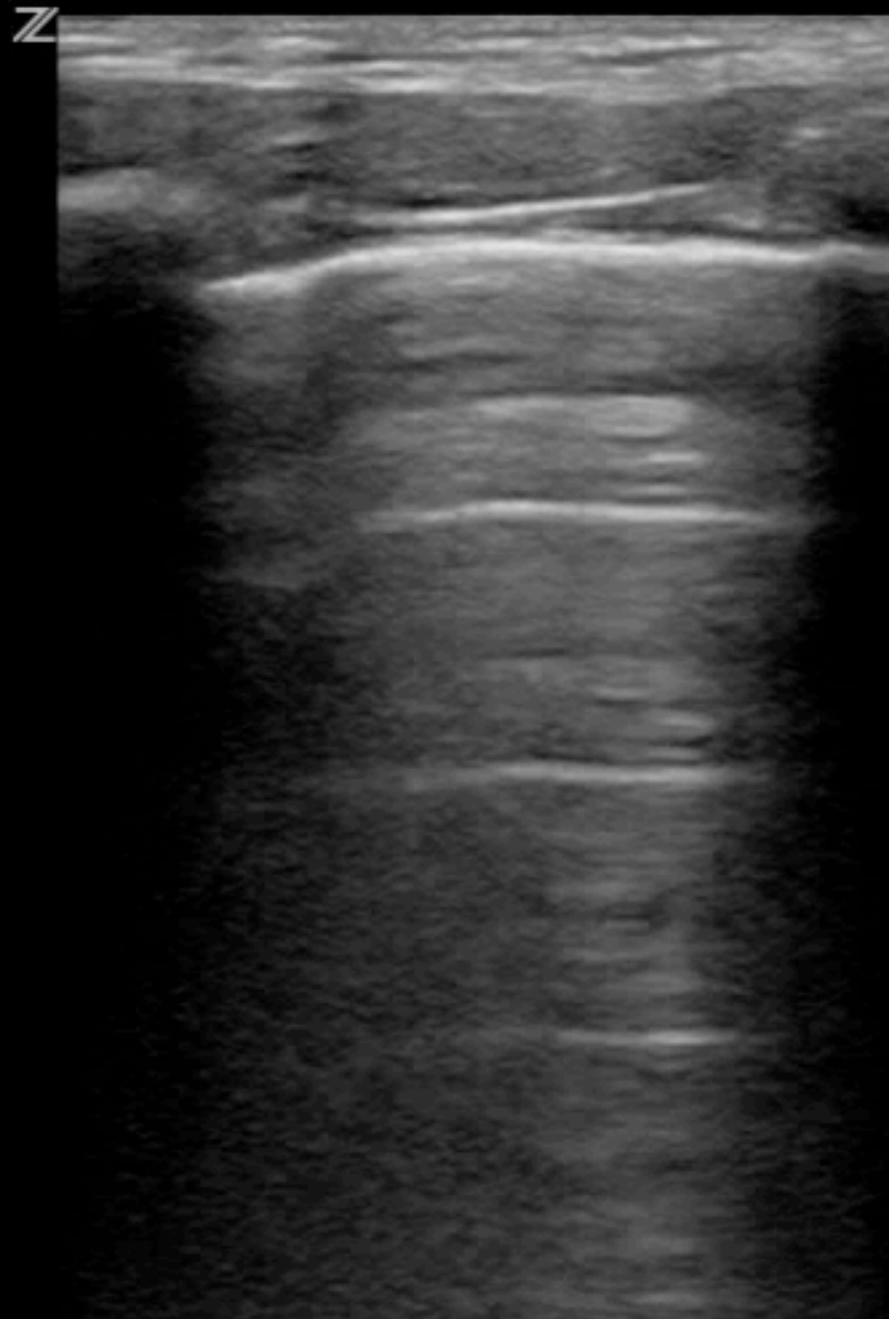
Treatment: ?

BiPap + (Nebs/Steroids vs NTG)



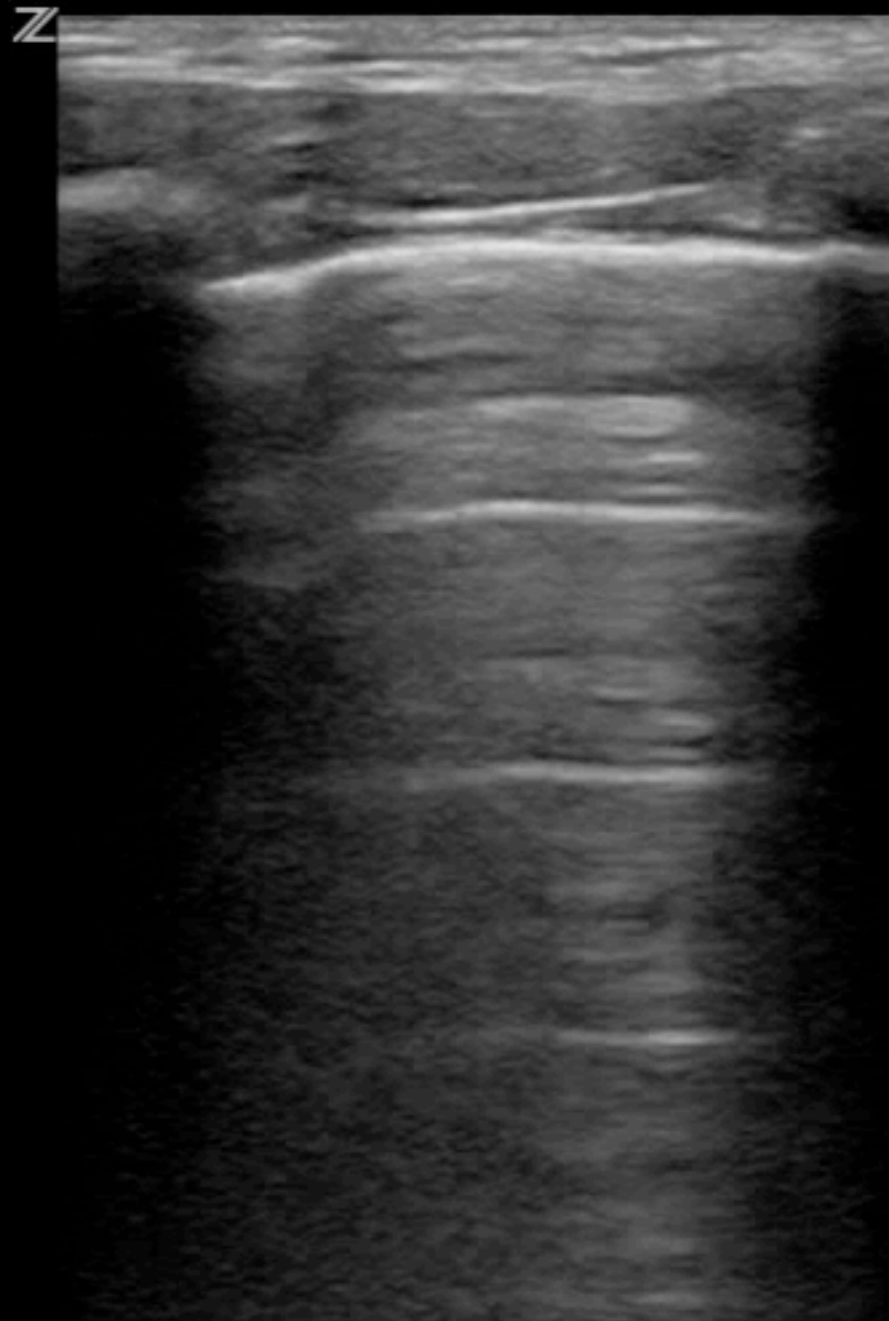
— Abd/PTX
L10-5/CH8MHz
· DR70/M3/P2
G86/E2/100%
- MI1.3 TIs0.1
6.0 cm
· 12 Hz
△ ZSI 0

Anterior lung spaces



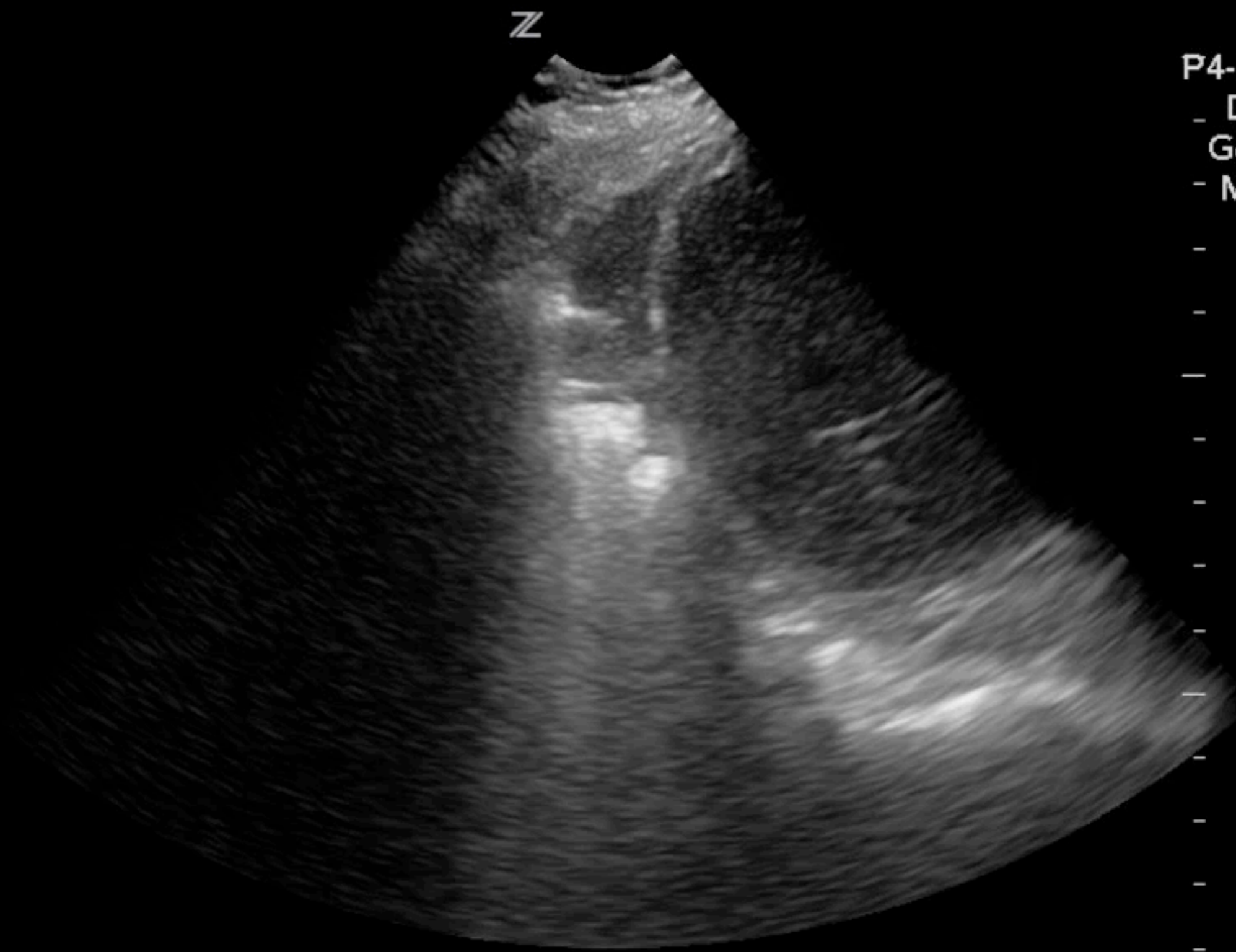
— Abd/PTX
L10-5/CH8MHz
· DR70/M3/P2
G86/E2/100%
- MI1.3 TIs0.1
6.0 cm
· 12 Hz
△ ZSI 0

Anterior lung spaces



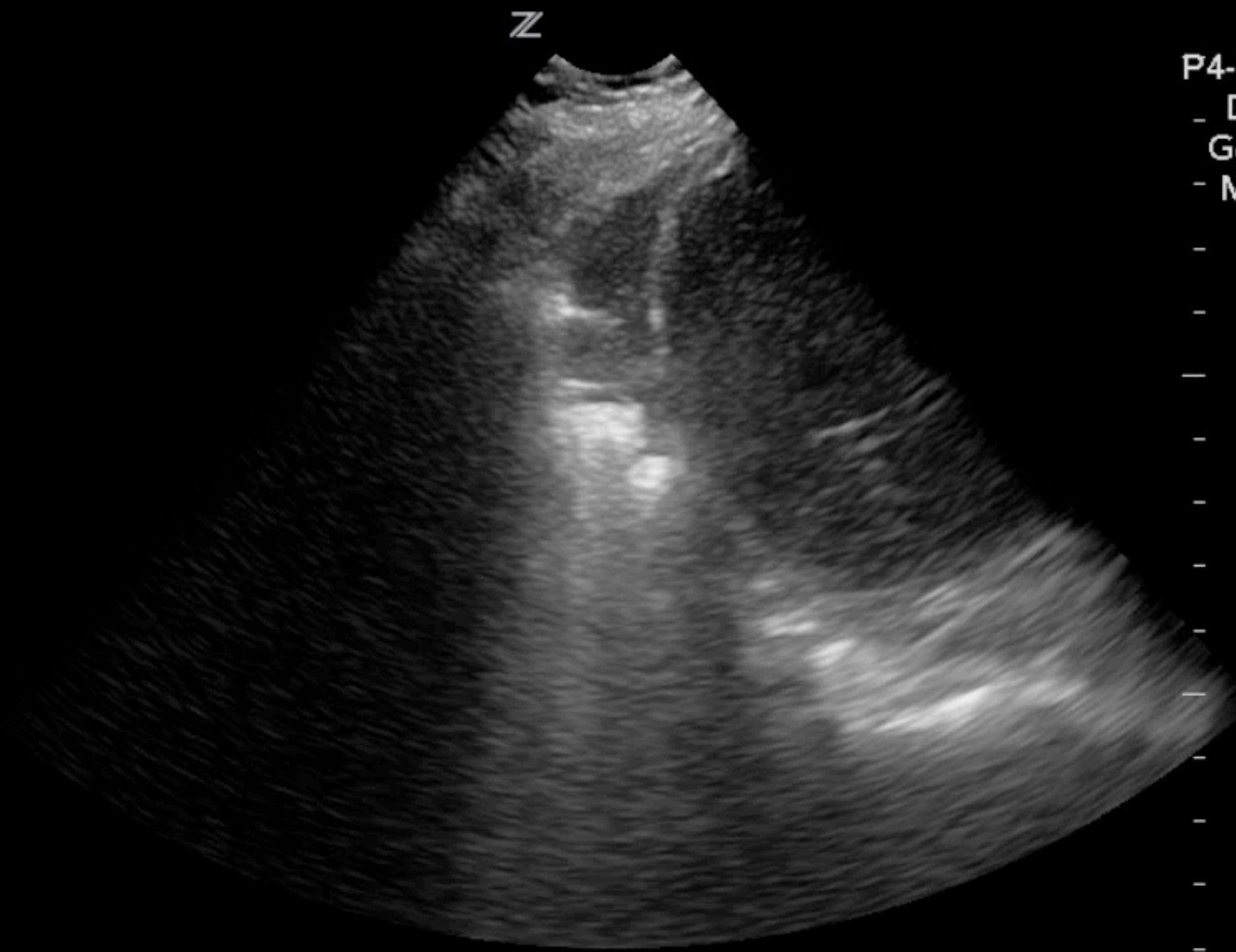
— Abd/PTX
L10-5/CH8MHz
· DR70/M3/P2
G86/E2/100%
- MI1.3 TIs0.1
6.0 cm
· 12 Hz
△ ZSI 0


Anterior lung spaces
(+) lung sliding, A-lines



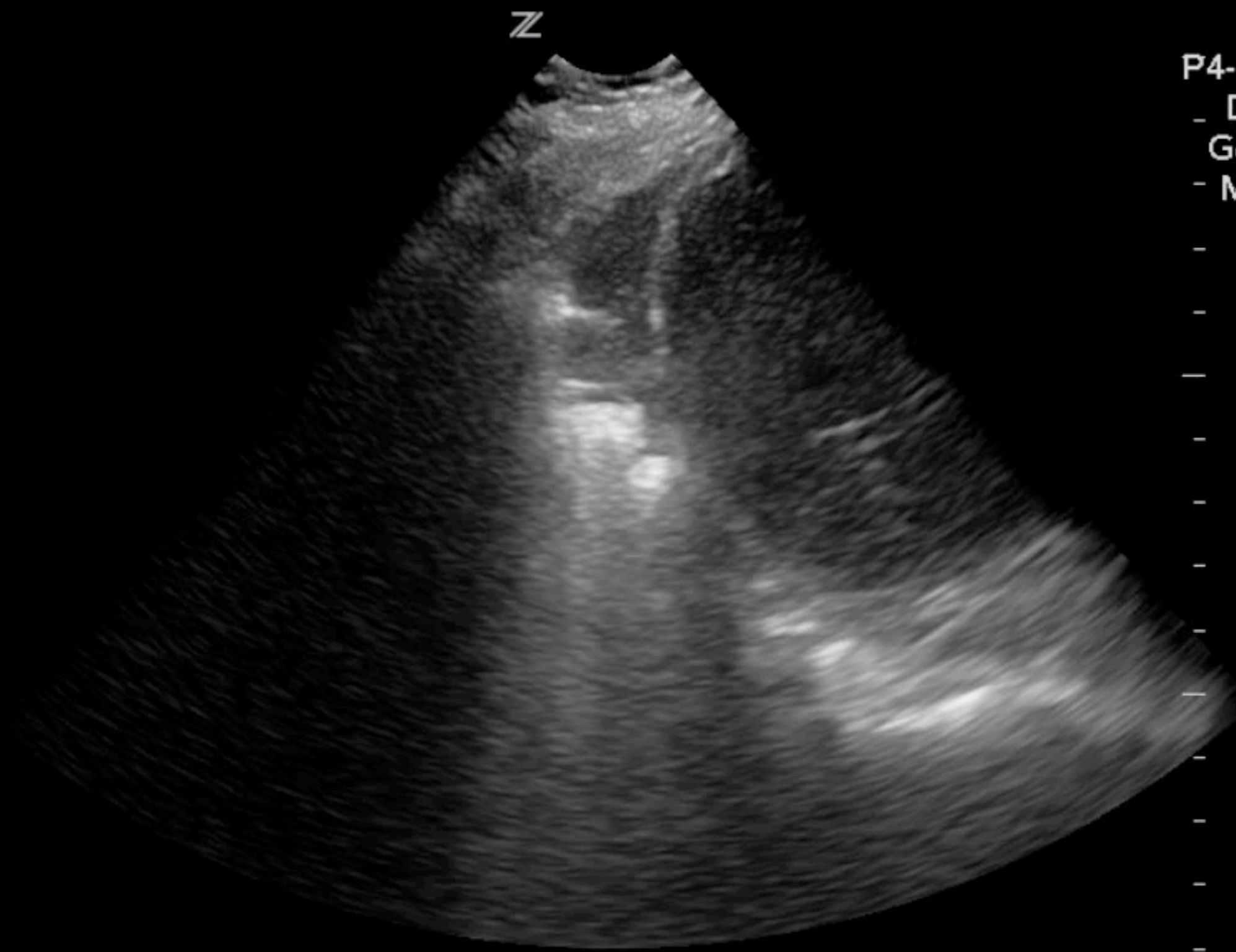
Abd/FAST
P4-1c/CH4MHz
_ DR50/M2/P2
_ G82/E1/100%
- MI1.5 TIs0.5
14.0 cm
17 Hz
△ ZSI 0
Image


Pleural spaces



Abd/FAST
P4-1c/CH4MHz
_ DR50/M2/P2
_ G82/E1/100%
- MI1.5 TIs0.5
_ 14.0 cm
_ 17 Hz
_  ZSI 0
_ **Image**

Pleural spaces



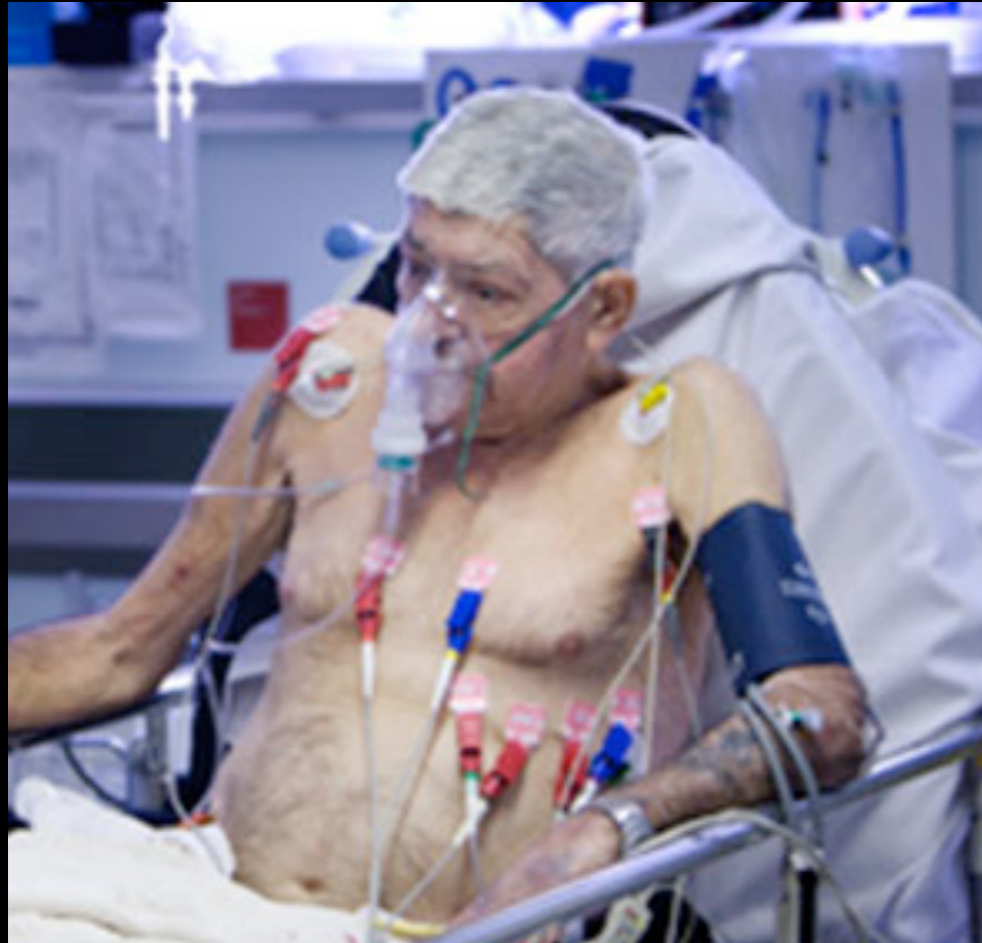Abd/FAST
P4-1c/CH4MHz
_ DR50/M2/P2
_ G82/E1/100%
- MI1.5 TIs0.5
_ 14.0 cm
_ 17 Hz
_  ZSI 0
_ **Image**

Pleural spaces
(+) air bronchograms

Case: Worsening Dyspnea



Case: Worsening Dyspnea



87 y/o F HBS c/s for PNA
T 100, BP 128/75, HR 110
Mild ARI, lactate 4.7
SpO₂ 95 → 88%

Case: Worsening Dyspnea

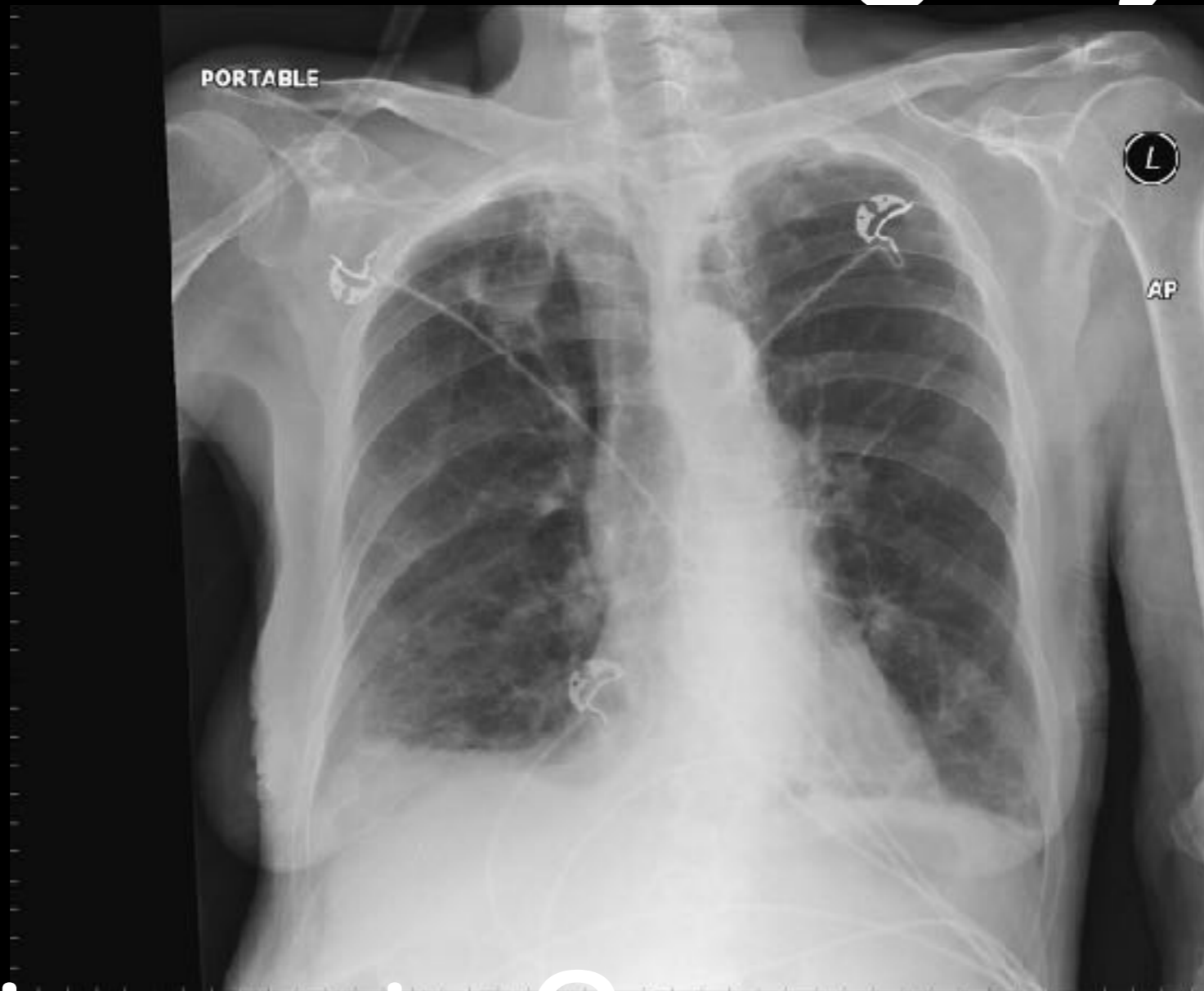

87 y/o F HBS c/s for PNA
T 100, BP 128/75, HR 110
Mild ARI, lactate 4.7
SpO2 95 → 88%

Treatment: ?

Hold or continue fluids?

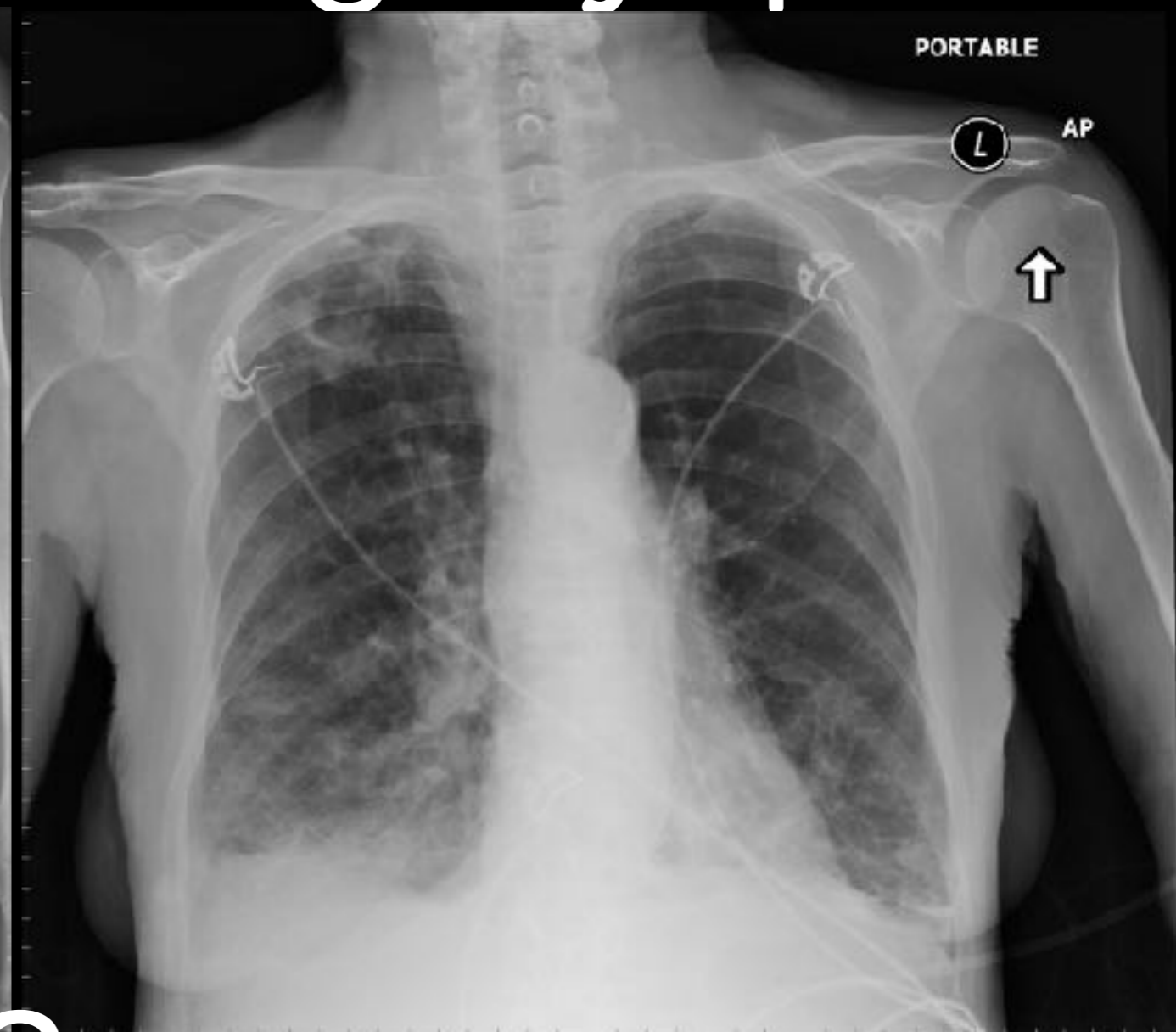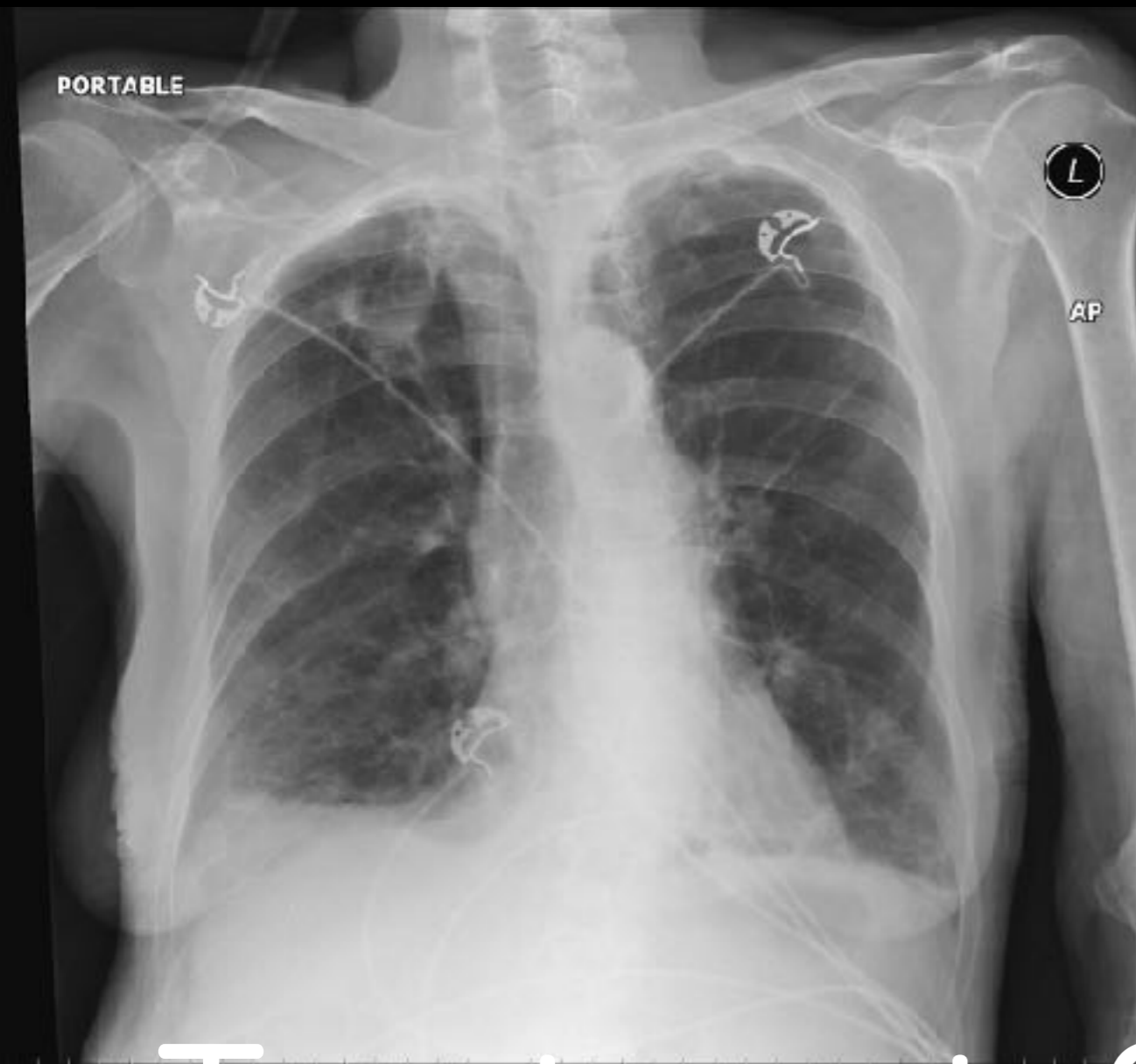Case: Worsening Dyspnea



Treatment: ?

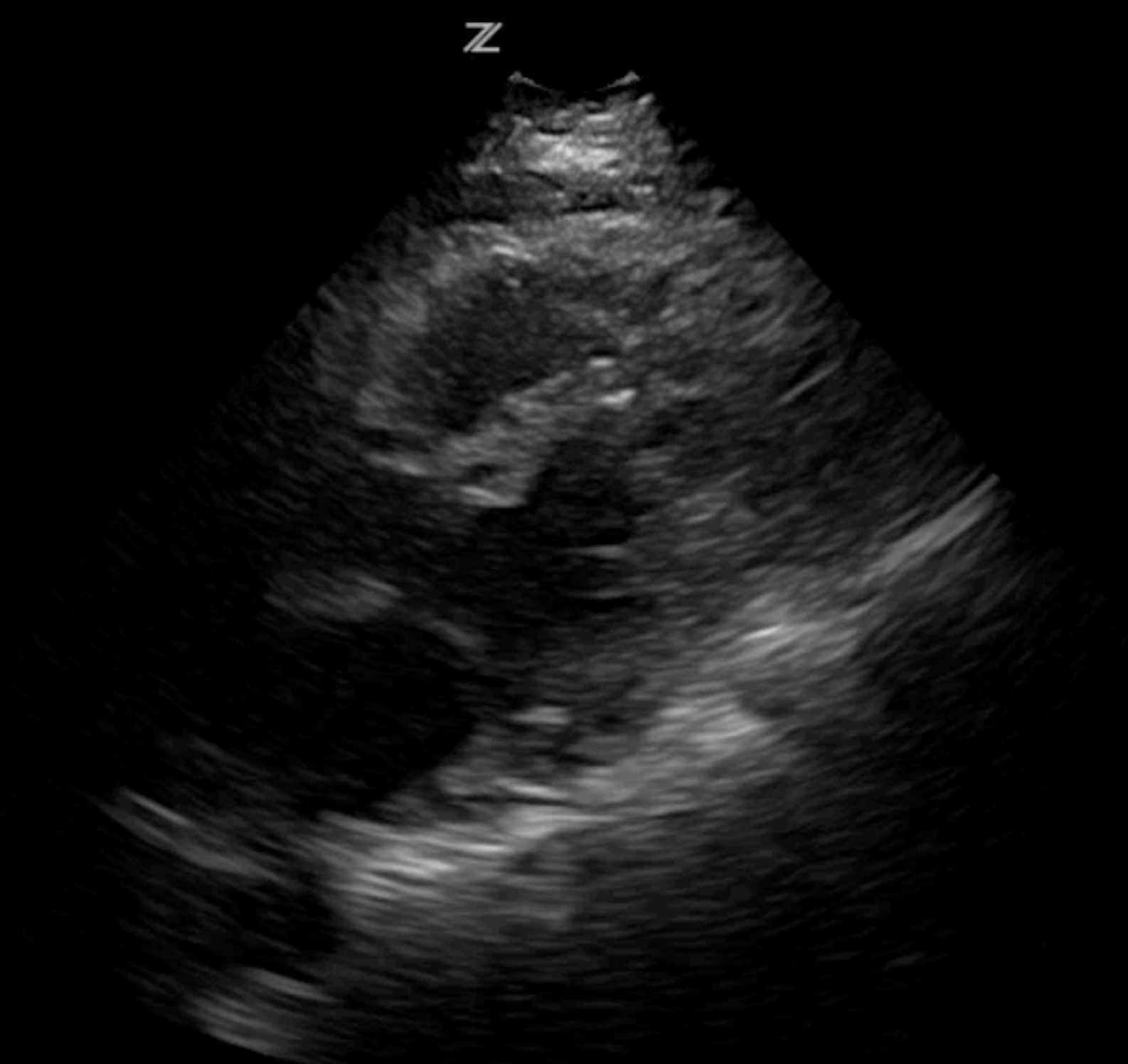
Hold or continue fluids?

Case: Worsening Dyspnea



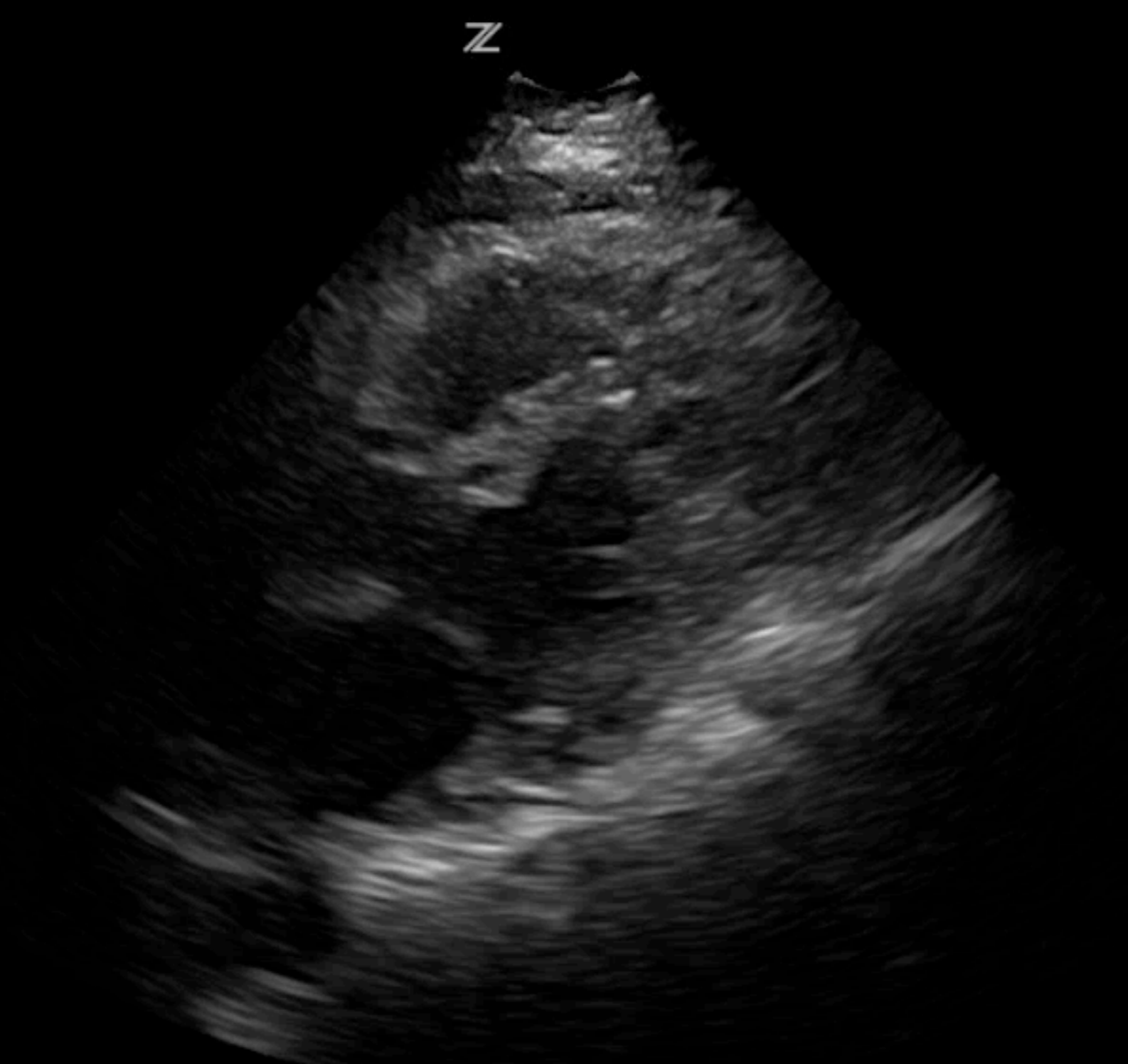
Treatment: ?

Hold or continue fluids?



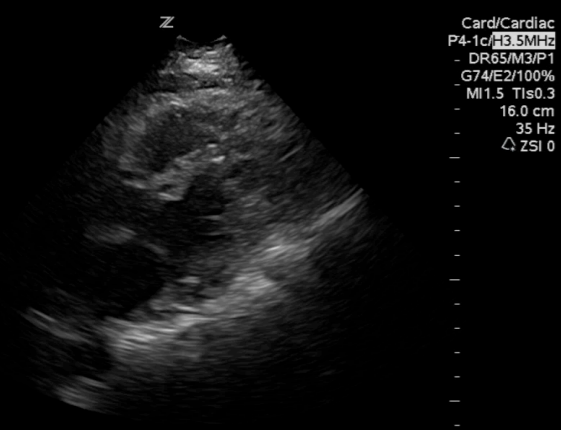
Card/Cardiac
P4-1c/H3.5MHz
- DR65/M3/P1
G74/E2/100%
- MI1.5 TIs0.3
- 16.0 cm
- 35 Hz
△ ZSI 0

Treatment: ?



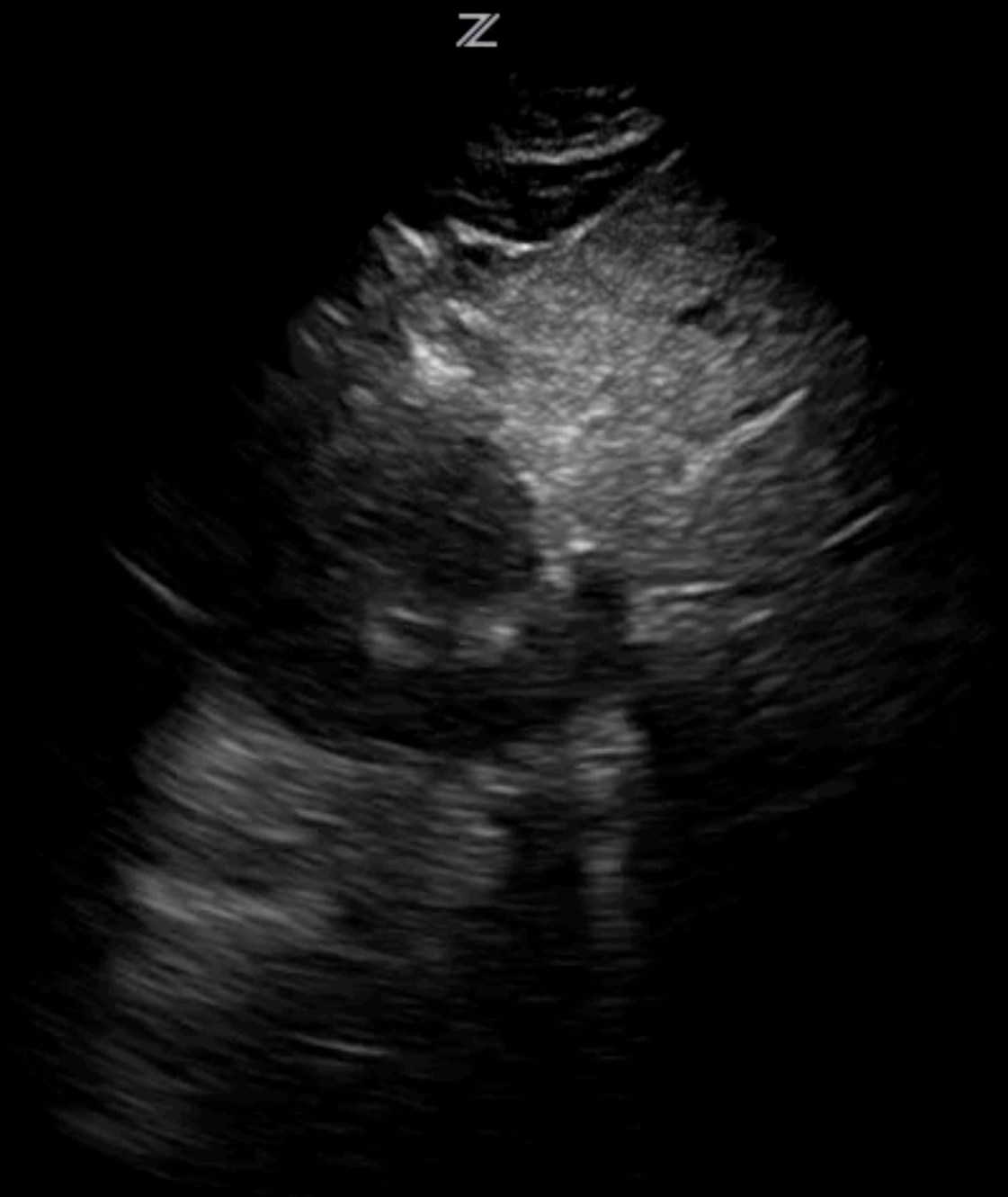Card/Cardiac
P4-1c/H3.5MHz
- DR65/M3/P1
G74/E2/100%
- MI1.5 TIs0.3
- 16.0 cm
- 35 Hz
△ ZSI 0

Treatment: ?
Evaluate cardiac function



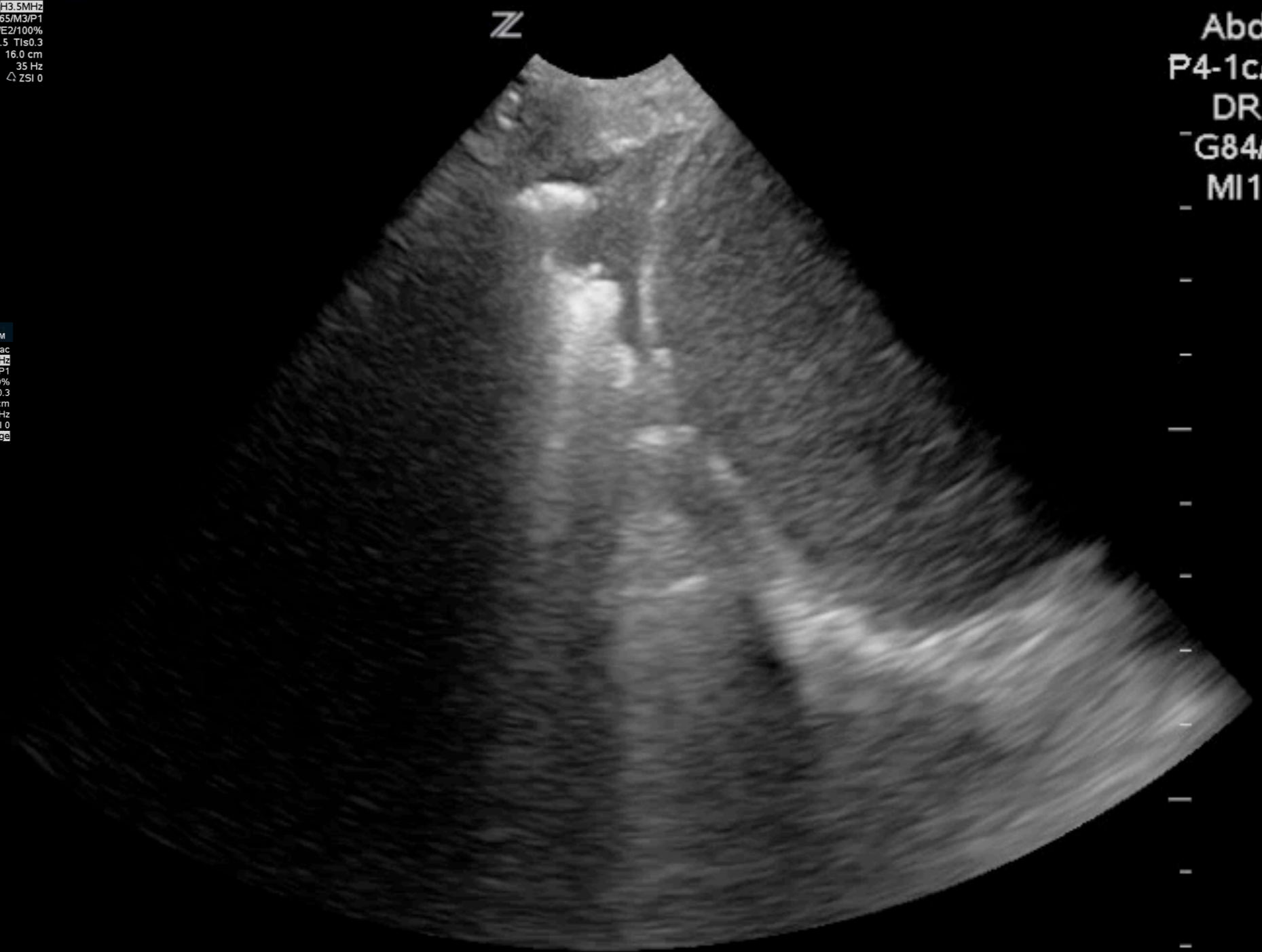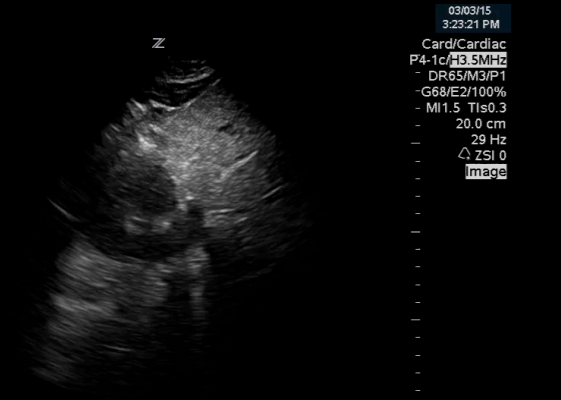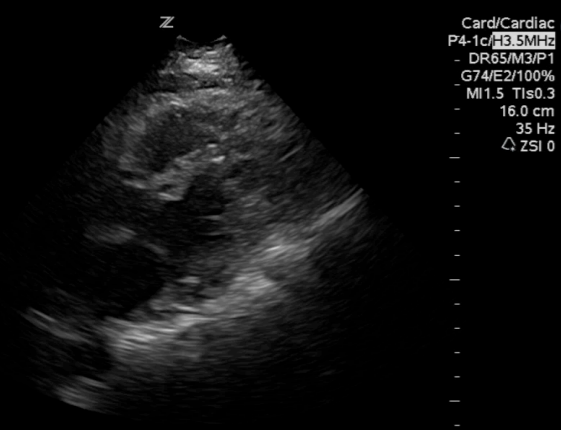
Card/Cardiac
P4-1c/H3.5MHz
- DR65/M3/P1
- G74/E2/100%
- MI1.5 TIs0.3
- 16.0 cm
- 35 Hz
△ ZSI 0

03/03/15
3:23:21 PM



Card/Cardiac
P4-1c/H3.5MHz
- DR65/M3/P1
- G68/E2/100%
- MI1.5 TIs0.3
- 20.0 cm
- 29 Hz
△ ZSI 0
Image

Treatment: ?
Evaluate IVC



Treatment: ?
Evaluate lung

Pearls & Pitfalls

Pearls & Pitfalls

Utilize lower frequency probes

Pearls & Pitfalls

Utilize lower frequency probes

Note limitations, e.g, subcutaneous emphysema

Pearls & Pitfalls

Utilize lower frequency probes

Note limitations, e.g, subcutaneous emphysema

No lung sliding does not always mean pneumothorax

Pearls & Pitfalls

Utilize lower frequency probes

Note limitations, e.g, subcutaneous emphysema

No lung sliding does not always mean pneumothorax

Be aware of heart when positioning probe

Pearls & Pitfalls

Utilize lower frequency probes

Note limitations, e.g, subcutaneous emphysema


No lung sliding does not always mean pneumothorax

Be aware of heart when positioning probe

Use echo in conjunction with lung US

Questions?

Scanning technique




Probe

Approach

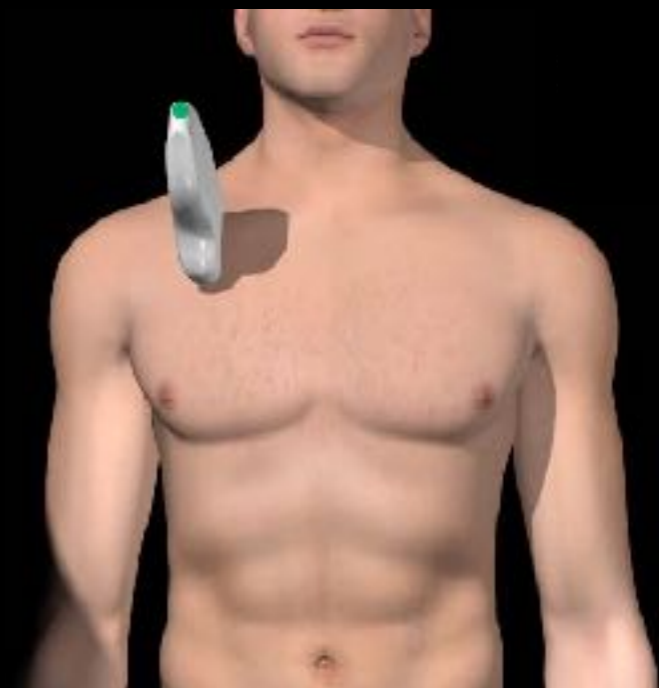Lung setting

Scanning technique




Probe

Approach



Scanning technique




Probe

Approach

Think FAST

Scanning technique



Probe

Approach

